

## The Race to Achieve the Gold Standard in Coronary Imaging

Giulio Guagliumi<sup>a</sup> and Renu Virmani<sup>b</sup>

<sup>a</sup>Cardiovascular Department, Ospedali Riuniti di Bergamo, Bergamo, Italy

<sup>b</sup>CVPath, International Registry of Pathology, Gaithersburg, United States

The accuracy of the intravascular ultrasound (IVUS) and optical coherence tomography (OCT) measurements is essential for the diagnosis and treatment of coronary artery disease. IVUS is considered the gold standard for in-vivo vessel wall interrogation and was established in postmortem specimens of human coronary arteries almost two decades ago.<sup>1,2</sup> Due to IVUS's ability to image through blood and penetrate deep into the vessel wall it provides consistent quantitative measurements of vessel dimensions which are needed for establishing the severity of disease and changes induced at the time of percutaneous coronary interventions (PCI).<sup>3,4</sup> However, lumen diameter, area, and volume, and percentage of obstruction are based on the evaluation of the lumen-vessel interface. A sharp distinction between lumen and vessel wall facilitates determination of lumen areas and volumes and allows precise automated lumen contour with less errors, an important feature for rapid intraprocedural image analysis. OCT is a new high resolution imaging modality that uses light waves instead of sound to probe the vessel, providing a tomographic perspective of lumen geometry.<sup>5</sup> Frequency of OCT light is 10 millions time faster than IVUS with a much clearer delineation of intraluminal border. The assessment of major critical processes in coronary artery disease (thin cap fibrous atheroma, macrophage accumulation, stent strut apposition, and coverage following drug eluting stent implantation) require high resolution lumen details and accurate contour traces. Right now few data are comparing OCT and IVUS for lumen characterization.<sup>6</sup> Thanks

to OCT's amazing axial resolution, 10 times finer than IVUS, it has the potential to become the modern gold standard in interventional cardiology for lumen measurements. The main limitation of OCT resides in the need to displace blood from the coronary artery. Two different methods are used for visualize the coronary artery by OCT imaging wire: one using occlusion with a small balloon catheter in combination with selective low volume of continuous saline flush or Ringer's lactate, the second without occlusion but requires a large volume of isomolar contrast injected through the coronary ostium.<sup>7</sup> Both OCT and IVUS may be performed successfully in almost all the coronary arteries during diagnostic and interventional procedures<sup>8</sup> and both have excellent reproducibility for quantitative lumen measurements. However, procedural failure of IVUS occurs mainly from difficulty to crossing tight stenoses, whereas poor visualization of the lumen border with OCT is due to insufficient blood removal and results in suboptimal OCT image quality. Nevertheless, before claiming OCT as gold standard for coronary lumen dimensions one should be aware of the fact that measurements may vary significantly between different imaging modalities.

In this issue of *Revista Española de Cardiología* Gonzalo et al<sup>9</sup> report on lumen dimensions obtained by OCT and IVUS with comparison to histology in vitro, and in vivo comparison of the two technique without histology. The main observed findings were: *a*) both IVUS and OCT measure larger lumen areas as compared to histology; *b*) OCT derived lumen measurements are systematically smaller compared to IVUS; *c*) the difference is attenuated with the use of a non-occlusive technique; and *d*) specific cut-off points should be developed to define lesion severity by OCT as it is unclear if OCT with or without occlusion overestimates % narrowing or IVUS underestimates it.

A good correlation of the luminal area between both OCT and IVUS and the histological examination ( $r=0.97$ ;  $P<.001$ ; and  $r=0.96$ ;  $P<.001$ , respectively) was previously reported by Kume et al<sup>10</sup> in a larger series of coronary arteries from cadavers. OCT and IVUS were performed early after death, under physiologic pressure in order to distend

SEE ARTICLE ON PAGES 615-24

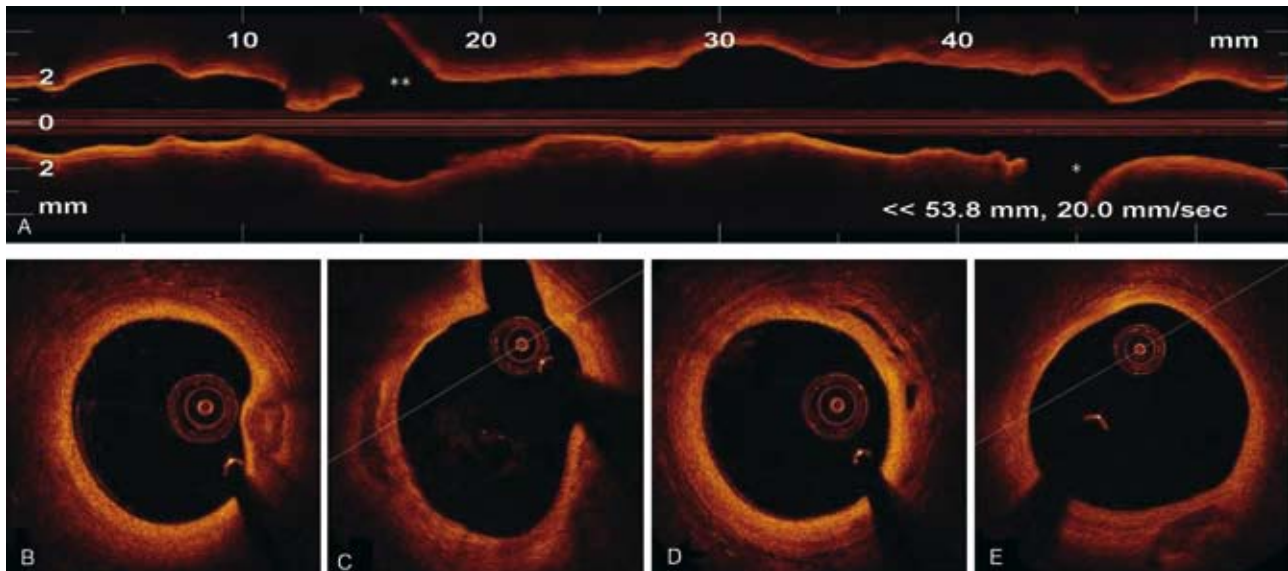
Conflict/disclosure statement: Dr Guagliumi reports receiving consulting fees or serving on advisory board for Boston Scientific, Abbott Vascular, Volcano and receiving grant support from Medtronic Vascular, Light Lab, Boston Scientific Corporation, Labcoat.

Correspondence: Dr Giulio Guagliumi, Cardiovascular Department, Ospedali Riuniti di Bergamo. Largo Barozzi 1, ingresso 14. 24100 Bergamo. Italia. E-mail: [guagliumig@gmail.com](mailto:guagliumig@gmail.com)

the lumen and obtain a circular cross-section, but before dehydration and fixation. In the present study OCT and IVUS measurements were carried out postmortem in perfusion-fixed samples, to make measurements of the lumen even more exact, but still before processing to obtain histological sections. Based on complex matching procedure, including the shape of the lumen, corresponding sites were selected. The finding by Gonzalo et al,<sup>9</sup> of coronary lumen dimensions by IVUS and OCT being larger than by histology in fixed human coronary arteries is not surprising, since comparisons of unfixed lumen measurements to fixed showed an increase in the percentage of cross-section luminal area stenosis from 21% (10) to 29% (10).<sup>11</sup> The process of dehydration, paraffin embedding, sectioning and staining results in a further reduction of the circumference by 19% (5) and wall thickness reduction by 18% (2).<sup>12</sup> Seigel et al showed that the overall plaque and medial shrinkage was in the order of 11%, with maximum shrinkage observed in collagen and lipid rich arteries and the least in heavily calcified vessels.<sup>11</sup> Further limitations exist comparing imaging obtained in fixed pathologic specimens and need further clarification. Backscattering of signals due to fixation of cross-link collagen may significantly enhance the delineation between lumen and vessel wall compared to in life lumen measurements, with an artificial increase of reflectivity. In addition, even limited difference in the alignment of only 35 matched frames of OCT, IVUS and histological sections may have an impact on the results. Also, the lesions assessed by Gonzalo et al<sup>9</sup> were not severely narrowed (59% [18]), with probably low calcium deposits, as illustrated in representative OCT longitudinal view, again impacting to a higher degree of lumen changes after fixation. Finally, a mean lumen and vessel areas of only 2.5 and 7.6 mm<sup>2</sup> respectively for ostial and proximal left artery descending coronary arteries (the only vessel examined ex-vivo in this study) is suggestive of a substantial shrinkage in these arteries. Therefore, caution must be used in extrapolating the message that IVUS and OCT imaging modalities significantly overestimates the true lumen dimensions as compared to pathology. We believe that high resolution imaging techniques likely gives the best estimate of the clinical lumen dimensions rather than measurements obtained by histology alone, which are not directly analogous to measurement in life and are subject to variable technical preparation and artifacts in the production of a histological section.

A second important message from the work of Gonzalo et al<sup>9</sup> is that OCT underestimates the lumen dimensions compared to IVUS. This difference has consistently been observed in prior studies.<sup>8</sup> Although, minimal lumen diameter (MLD) and

minimal lumen area measurements in living patients by OCT significantly correlate with the measurements by IVUS ( $r=0.91$ ;  $P<.0001$ ; and  $r=0.95$ ;  $P<.0001$  respectively), OCT measurements were found to be generally smaller (7%). Several factors may explain this difference: firstly, there are considerable limitations in the accuracy of IVUS measurements in the near field, primarily due to inadequate spatial resolution ( $>100\ \mu\text{m}$ ). Additional application of echogenic contrast dye can significantly improve precision of IVUS lumen measurements.<sup>13</sup> Furthermore, distortions produced by non-coaxial IVUS imaging and echo dropout may also limit a clear definition of the luminal border. It might simply be that IVUS measurements are actually an overestimation because of inferior axial resolution versus OCT that enables an optimal definition of the lumen-plaque border. However, OCT is not immune to artifacts, some of these are unique features of catheter design and properties of light, which may impact measurements. Despite precise manufacturing, commercially used image-wires have some differences in their optic path lengths; strict calibration is required to fully exploit the high spatial resolution of OCT. Furthermore, eccentric wire position in the lumen also can amplify image border distortion and artifacts. In addition, residual blood attenuates the light penetration and may create suboptimal imaging for lumen border delineation. In the work of Gonzalo et al<sup>9</sup> only OCT frames with 360° delineation contour were included. Motion artifacts during the cardiac cycle hampered the visualization of the entire vessel circumference in 10% to 20 % of the cross-sections. In a previous article from the same group of investigators focused on reproducibility of OCT, 399/1800 frames (22%) were excluded from the analysis due to the incomplete border visualization or presence of side branch, thus making thus potentially making the lumen contours inaccurate.<sup>14</sup> A real problem is the level of applicability in life of new high resolution intravascular techniques that needs to be the gold standard. Lastly, the wide gap in lumen dimensions observed by Gonzalo et al between IVUS and OCT in non stented coronary segments was not reported when the arteries are treated with metallic stents,<sup>15</sup> an important strategy used in interventional cardiology. Therefore, the small spectrum of lumen measurements reported in this manuscript cannot be easily extrapolated to the real world practice where a wide variation in vessel size and lesion severity are needed. Also, negotiating tortuous vessels may further increase errors and artifacts. Conversely, stents seem to be less affected by this variability. Therefore there is an important message in the current report which has clinical implications: IVUS criteria and cut-off points cannot be immediately translated to OCT. Further studies are



**Figure.** Tomographic scan of the entire left circumflex coronary artery obtained with new frequency domain OCT system (C7xR, LightLab, Watford, USA), in <math>< 3</math> seconds, with non occlusive flushing. A: longitudinal view of 54 mm of the artery at the pullback rate of 20 mm/s. B, C, and D: multiple cross sectional images selectively obtained at different levels of the native LCx. \*First marginal branch. \*\*Second marginal branch. (G. Guagliumi, personal data).

needed to address this issue in larger patients groups before accepting OCT as the new gold standard.

The reason why larger dimensions are observed with the non-occlusive technique as compared with the occlusive strategy is probably the result of continued blood flow and maintenance of outward pressure, which allows for larger lumens. In healthy swine the average intracoronary pressure measured during occlusion with 0.5-0.7 mL/s saline flushing rate was only 30-50 mm Hg. On the other hand, non occlusive high volume flushing can produce an excessive increase in intraluminal pressure and artificially enlarge the lumen diameter. The length of the region analyzed with OCT in both occluded and non-occluded passes was confined to short segments (mean, 11.3 mm), much shorter than what we would like to have in life for wide clinical application. In fact, in the currently available OCT systems, the non-occlusive technique should be limited to short coronary segments to avoid excessive QTc prolongation. The new generation of frequency domain OCT that can grab the entire coronary artery in few seconds (<math>< 5</math> s; Figure) will benefit the most of non occlusive, high volume contrast flushing method, without risk of major arrhythmias.<sup>16</sup>

IVUS had the great merit to open a new era on precise intraluminal measurements, otherwise assessed by coronary angiography. However, IVUS remains confined to clinical research investigations and few select indications, mainly complex lesion and patient cohorts. It is unclear if OCT will replace IVUS for routine clinical use. In order for OCT to be accepted by the medical community, ease of use

and interpretation even by the least experienced operators will be required. In the race to break the gold standard, light faster than sound has the potential to be in pole position. New frequency domain OCT systems (OFDI) are taking advantage of the unbeatable speed in pull-back rate (up to 20 mm/s) with extremely fast image data acquisition that allows to have a tomographic scan of the entire coronary artery in seconds, following a non-occlusive flush. Based upon these properties OFDI should probably permit a full scan of all 3 coronary vessels before and following coronary interventions with limited flush to avoid contrast overload (relevant in the presence of renal insufficiency and left ventricular failure). Finally, OFDI has the ability to be combined with adjuvant techniques, including Doppler and IVUS, and to derive enormous advantage by miniaturization. The race to break the gold standard for precise lumen assessment in patients is now opened. Nevertheless precise lumen measurement is only one of the multiple variables that are required for an appropriate decision making process.

## REFERENCES

1. Nishimura RA, Edwards WD, Warnes CA, Reeder GS, Holmes DR, Tajik AJ, et al. Intravascular ultrasound imaging: in vitro validation and pathologic correlation. *J Am Coll Cardiol.* 1990;16:145-54.
2. Abizaid AS, Minz GS, Merhan R, Abizaid A, Lansky AJ, Pichard AD, et al. Long term follow-up after percutaneous transluminal coronary angioplasty was not performed based on

- intravascular ultrasound findings. *Circulation*. 1999;100:256-61.
- Nissen SE, Gurley JC. Application of intravascular ultrasound for detection and quantitation of coronary atherosclerosis. *Int J Card Imaging*. 1991;6:165-77.
  - Jiménez-Quevedo P, Suzuki N, Corros C, Ferrer C, Angiolillo DJ, Alfonso F, et al. Vessel shrinkage as a sign of atherosclerosis progression in type 2 diabetes: a serial intravascular ultrasound analysis. *Diabetes*. 2009;58:209-14.
  - Fujimoto JG, Boppart SA, Tearney GJ, Bouma BE, Pitris C, Brezinski ME, et al. High resolution in vivo intrarterial imaging with optical coherence tomography. *Heart*. 1999;82:128-33.
  - Low AF, Kawase Y, Chan YH, Tearney G, Bouma B, Jang I, et al. In vivo characterization of coronary plaques with conventional grey-scale intravascular ultrasound: correlation with optical coherence tomography. *EuroInterv*. 2009;4:626-32.
  - Prati F, Cera M, Ramazzotti V. Safety and feasibility of a new non-occlusive technique for facilitated intracoronary optical coherence tomography (OCT) acquisition in various clinical and anatomical scenarios. *EuroInterv*. 2007;3:365-70.
  - Yamaguchi T, Therashima M, Akasaka T, Hayashi T, Mizuno K, Muramatsu T, et al. Safety and feasibility of an Intravascular Optical Coherence Tomography Image Wire System in the Clinical Setting. *Am J Cardiol*. 2008;101:562-7.
  - Gonzalo N, Serruys PW, García-García HM, Can Soest G, Okamura T, Ligthart J, et al. Comparación cuantitativa ex vivo e in vivo de las dimensiones del lumen medidas por tomografía de coherencia óptica y ecografía intravascular en arterias coronarias humanas. *Rev Esp Cardiol*. 2009;62:615-24.
  - Kume T, Akasaka T, Kawamoto T, Watanabe N, Toyota E, Neishi Y, et al. Assessment of coronary intima-media thickness by optical coherence tomography. Comparison with intravascular ultrasound. *Circ J*. 2005;69:903-7.
  - Siegel RJ, Swan K, Edwalds G, Fishbein MC. Limitations of postmortem assessment of human coronary artery size and luminal narrowing: differential effects of tissue fixation and processing on vessels with different degrees of atherosclerosis. *J Am Coll Cardiol*. 1985;5:342-6.
  - Virmani R, Avolio AP, Mergner WJ, Robinowitz M, Herderick EE, Cornhill JF, et al. Effect of aging on aortic morphology in populations with high and low prevalence of hypertension and atherosclerosis. Comparison between occidental and Chinese communities. *Am J Pathol*. 1991;139:1119-29.
  - Schmid KM, Voelker W, Mewald J, Paul HJ, Wehrmann M, Bültmann B, et al. In vitro assessment of luminal dimensions of coronary arteries by intravascular ultrasound with and without application of echogenic contrast dye. *Basic Res Cardiol*. 1994;89 Suppl 1:129-35.
  - Tanimoto S, Rodríguez-Granillo G, Barlis P, de Winter S, Bruining N, Hamers R, et al. A novel approach for quantitative analysis of intracoronary optical coherence tomography: high inter-observer agreement with computer-assisted contour detection. *Cath Cardiovasc Interv*. 2008;72:228-35.
  - Kawase Y, Hoshino K, Yoneyama R, McGregor J, Hajjar RJ, Jang IK, et al. In-vivo volumetric analysis of coronary stent using optical coherence tomography with a novel balloon occlusion-flushing catheter: a comparison with intravascular ultrasound. *Ultrasound Med Biol*. 2005;31:1343-49.
  - Yun SH, Tearney GJ, Vakoc BJ, Shishkov M, Oh WY, Desjardins AE, et al. Comprehensive volumetric optical microscopy in-vivo. *Nat Med*. 2006;12:1429-33.