

body myositis, necrotizing myositis, and nonspecific myositis. The recent description of new antibodies and the availability of techniques for their detection have prompted calls for a reclassification under the term AIM, given that almost all forms of the disease feature autoimmune antibodies.²

The case of NAM reported here differs from other reported instances of AIM in showing minimal or absent inflammation in the muscle biopsy, despite the presence of areas of marked necrosis and regeneration.

NAM can occur alone or in conjunction with viral infection, cancer, scleroderma, or statin therapy. The condition is associated with 2 types of antibody: anti-SRP antibodies and antibodies to 3-hydroxy-3-methylglutaryl coenzyme-A reductase²; however, up to a third of patients are seronegative.

Anti-SRP antibodies are highly specific and are associated with more acute forms of disease, higher creatine kinase concentrations, and more pronounced damage to the respiratory and esophageal muscles. Cardiac injury is less frequent.^{1–3}

The first description of cardiac involvement in AIM was provided by Oppenheim in 1899. The prevalence of cardiac injury in AIM patients remains uncertain, ranging from 6% to 75% depending on patient selection and the method used. However, cardiac injury is considered a major clinical manifestation of AIM and one of the principle causes of death.^{3,4}

Clinical expression of cardiac involvement is relatively infrequent (3%–6%), with the most frequent cardiac manifestation being myocarditis (40%). Recurrent myocarditis is believed to cause fibrosis of the cardiac conduction tissue, the vasculature, and the myocardium; the final outcome is heart failure, which is the most frequent cardiovascular cause of death (20%).^{5,6} Nevertheless, the rate of subclinical involvement ranges from 13% to 72% and shows a wide variety of manifestations, including alterations to the electrocardiogram (arrhythmias and conduction and repolarization alterations), the echocardiogram (diastolic dysfunction and takotsubo pattern), and MRI. Cardiac MRI stands out as the best method for detecting the initial myocardial inflammation and myocardial fibrosis in the chronic phase.³

The case reported here demonstrates the advisability of achieving an etiological diagnosis of nonischemic myocardial injury and shows that cardiac involvement can be the only manifestation of AIM. This patient's case also emphasizes the importance of cardiac MRI, autoimmunity studies, and above all

multidisciplinary collaboration for an appropriate clinical approach to these disorders.

CONFLICTS OF INTEREST

C. Morís de la Tassa is a proctor for Medtronic and sits on its advisory board.

Amaia Martínez León,^{a,*} Jessica Paola Rugeles Niño,^b Anahy María Brandy García,^c César Morís de la Tassa,^a Luis Caminal Montero,^b and José Rozado Castaño^a

^aServicio de Cardiología, Hospital Universitario Central de Asturias, Oviedo, Asturias, Spain

^bServicio de Medicina Interna, Hospital Universitario Central de Asturias, Oviedo, Asturias, Spain

^cServicio de Reumatología, Hospital Universitario Central de Asturias, Oviedo, Asturias, Spain

*Corresponding author:

E-mail address: amaiamtzleon@gmail.com (A. Martínez León).

Available online 30 June 2018

REFERENCES

- Milone M. Diagnosis and management of immune-mediated myopathies. *Mayo Clin Proc.* 2017;92:826–837.
- Senécal JL, Raynaud JP, Troyanov Y. A new classification of adult autoimmune myositis. *Arthritis Rheum.* 2017;69:878–884.
- Thiébaud M, Terrier B, Menacer S, et al. Antisignal recognition particle antibodies-Related cardiomyopathy. *Circulation.* 2013;127:e434–e436.
- Gupta R, Wayangankar SA, Targoff IN, Henneby TA. Clinical cardiac involvement in idiopathic inflammatory myopathies: a systematic review. *Int J Cardiol.* 2011;148:261–270.
- Hengstman GJ, ter Laak HJ, Vree Egberts WT, et al. Anti-signal recognition particle autoantibodies: marker of a necrotizing myopathy. *Ann Rheum Dis.* 2006;65:1635–1638.
- Dankó K, Ponyi A, Constantin T, Borgulya G, Szegedi G. Long-term survival of patients with idiopathic inflammatory myopathies according to clinical features: a longitudinal study of 162 cases. *Medicine (Baltimore).* 2004;83:35–42.

<https://doi.org/10.1016/j.rec.2018.04.024>
1885-5857/

© 2018 Sociedad Española de Cardiología. Published by Elsevier España, S.L.U. All rights reserved.

A 3D Printed Patient-specific Simulator for Percutaneous Coronary Intervention



Simulación impresa en 3D de intervención coronaria percutánea específica para un paciente

To the Editor,

Advances in 3-dimensional (3D) printing over the past 10 years have converted this technology from a specialized industrial process into a widely used tool with applications in many areas, including cardiology.^{1,2}

The 3D printing methodology that has expanded most is fused deposition modeling, and commercially accessible printers today provide 20 μm resolution with practically no geometric limitation.

Previous reports have shown the usefulness of 3D printing for pretreatment trials,³ training,⁴ physiological simulations,⁵ and other applications. To our knowledge, the approach described here is the first specifically designed for training in percutaneous coronary intervention that reproduces structures while preserving

the spatial distribution found in the patient and maintaining high-precision anatomic detail.

The model was built from synchronized cardiac computed tomography images. The ascending aorta and coronary arteries were segmented using the HOROS open-code software program (The Horos Project), resulting in a mesh of the intravascular volume of these structures. Subsequent processing in the Rhinoceros 3D modeling program produced vessels with a defined wall thickness while maintaining the intravascular lumen dimensions. A bespoke stand was then designed to hold the model in the correct anatomical orientation. The model was prepared for printing in the CURA program (Ultimaker inc).

The resulting model precisely replicated the spatial orientation of the intravascular lumens in the aorta and coronary tree. Blood flow was simulated by continuous pumping of saline solution through the model in an open hydraulic circuit.

A 7-Fr, 3.75 extra-backup curve guide catheter (Medtronic) was introduced into the left coronary artery through a 7-Fr introducer

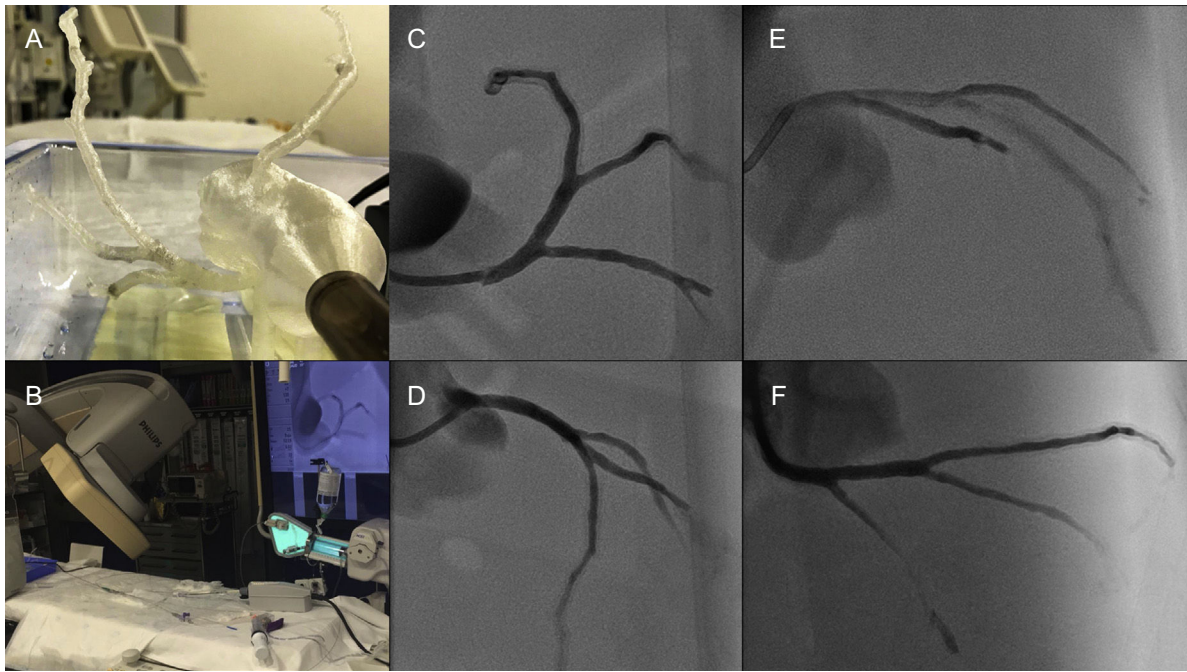


Figure 1. A and B, Coronary vessel model in correct anatomical orientation. C-F, Angiographic projections: C, Left anterior oblique artery, caudal view; D, Left anterior oblique, cranial view; E, Right anterior oblique, cranial view; F, Right anterior oblique, caudal view.

sheath (Terumo), and contrast agent was injected with a contrast pump (ACIST).

This is the first report of the on-site production of a 3D model for simulated coronary intervention built from patient-specific anatomical characteristics of the aorta and coronary vessels. The correct anatomical positioning of structures in the model reliably reproduced the orientation of the arteries in standard angiographic projections (Figure 1). This level of precision allowed us to

verify the applicability of different intracoronary imaging techniques: intravascular ultrasound (Eagle Eye Platinum Digital IVUS, Vulcano Philips) and optical coherence tomography (OCT; Dragonfly OPTIS, St Jude) (Figure 2E and F and [video 1 of the supplementary material](#)). Furthermore, the model was used to simulate coronary stent implantation (Figure 2A-C) and rotablation (Rotablator, Boston Scientific) ([Figure 2D](#) and [video 2 of the supplementary material](#)).

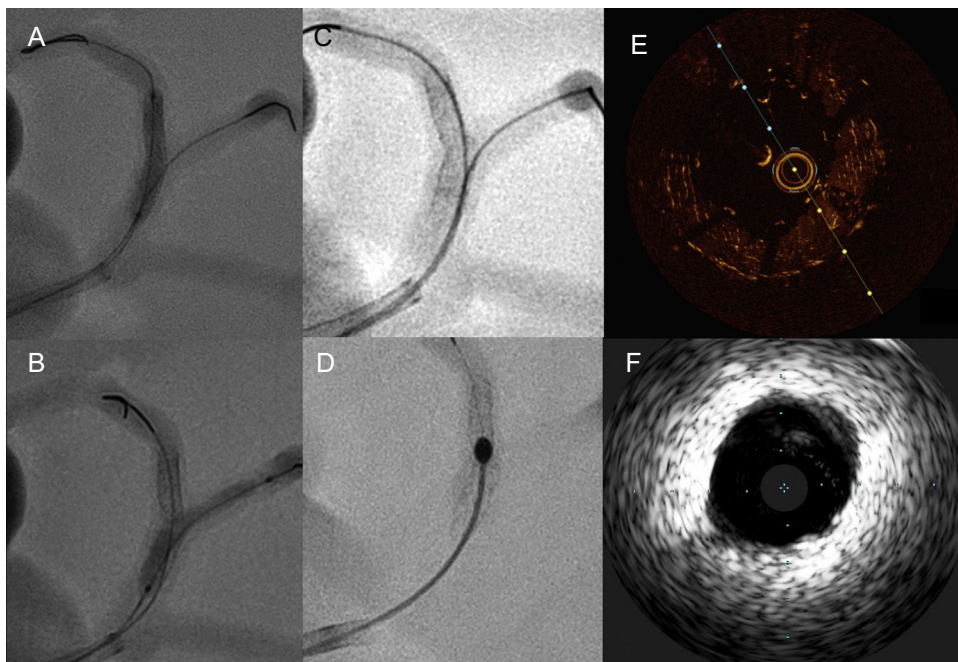


Figure 2. A-C, Simulation of coronary intervention at the bifurcation of the left anterior descending and primary diagonal arteries. D, Stent rotablation. E, Optical coherence tomography image at the level of a segment with an implanted stent. F, Intravascular echocardiography image at the level of the left coronary branch.

Despite being an accurate replica of the patient's coronary tree, the model has limitations for the simulation of coronary intervention: *a)* it does not reproduce the mechanical properties of the tissues that form the artery wall; and *b)* exposure of the model to light and sound mean that the OCT and IVUS images obtained differ from those obtained in the patient. However, as our report shows, the 3D model proved useful for stent evaluation.

In our view, 3D opens up a multitude of possibilities for coronary intervention in both coronary and structural heart disease. The potential of this technology has been demonstrated in diverse industrial applications and in biomedicine, with the implantation in patients of 3D printed prostheses made with biocompatible materials. The cardiological applications of these types of models range from teaching anatomy and angiographic projections to training in complex interventions, such as imaging-guided coronary interventions, treatment of bifurcations or ostial lesions, the development of new procedures, and support for structural interventions. Finally, it is possible to envision a future in which 3D modeling is used to generate personalized devices for cardiovascular intervention.

Acknowledgments

The authors thank the Cardiology and Radiology Service staff at the *Hospital Clínico Universitario* in Santiago de Compostela for their collaboration in this study.

CONFLICTS OF INTEREST

D3 Applied Technologies provided assistance and equipment used in the performance of this study.

Spanish Cardiovascular Imaging Registry. First Official Report of the Spanish Society of Cardiology Working Group on Cardiovascular Imaging (2017)



Registro Español de Imagen Cardíaca. I Informe Oficial de la Sección de Imagen Cardíaca de la Sociedad Española de Cardiología (2017)

To the Editor,

In recent years, cardiac imaging has become increasingly complex and technical while the indications for imaging procedures have been extended. To analyze the current situation, the Working Group on Cardiovascular Imaging of the Spanish Society of Cardiology (SEC), in line with other similar initiatives,^{1–5} conducted a voluntary online survey of members of the working group to collect information on activity in 2016. The survey was distributed to 86 hospitals in Spain, with a response rate of 61% (89% in public hospitals, with the only autonomous communities not represented being Castile-La Mancha and the Basque Country). The human resources assigned to cardiac imaging in centers at different levels of care are shown in [Table 1](#). The results for activity and echocardiography equipment are detailed in [Table 2](#). The number of studies, their complexity, and the ratio of studies/device increased; there were a greater number of beds in

SUPPLEMENTARY MATERIAL



Supplementary material associated with this article can be found in the online version available at <https://doi.org/10.1016/j.rec.2018.04.025>.

Alfredo Redondo Diéguez,* Belén Cid Álvarez, Alejandro Ávila Carrillo, Fernando Gómez Peña, José Ramón González-Juanatey, and Ramiro Trillo Nouché

Unidad de Hemodinámica y Cardiología Intervencionista, Complejo Hospitalario Universitario de Santiago de Compostela (CHUS), Centro de Investigación Biomédica en Red de Enfermedades Cardiovasculares (CIBERCV), Santiago de Compostela, A Coruña, Spain

*Corresponding author:

E-mail address: alfredorendon@gmail.com (A. Redondo Diéguez).

Available online 3 July 2018

REFERENCES

1. Vukicevic M, Mosadegh B, Min JK, Little SH. Cardiac 3D printing and its future directions. *JACC Cardiovasc Imaging*. 2017;10:171–184.
2. Valverde I. Three-dimensional printed cardiac models: applications in the field of medical education, cardiovascular surgery, and structural heart interventions. *Rev Esp Cardiol*. 2017;70:282–291.
3. Mokin M, Nagesh SVS, Ionita CN, Mocco J, Siddiqui AH. Stent retriever thrombectomy with the Cover accessory device versus proximal protection with a balloon guide catheter: In vitro stroke model comparison. *J Neurointerv Surg*. 2016;8:413–417.
4. Mitsouras D, Liacouras P, Imanzadeh A, et al. Medical 3 D printing for the radiologist. *RadioGraphics*. 2015;35:1965–1988.
5. Shepard L, Sommer K, Izzo R, et al. Initial simulated FFR investigation using flow measurements in patient-specific 3 D printed coronary phantoms. *Proc SPIE Int Soc Opt Eng*. 2017. Disponible en: <https://doi.org/10.1117/12.2253889>.

<https://doi.org/10.1016/j.rec.2018.04.025>
1885-5857/

© 2018 Sociedad Española de Cardiología. Published by Elsevier España, S.L.U. All rights reserved.

the institution, 38.6% of devices were more than 10 years old, and 89% of centers had digital image storage capability. The studies performed in the echocardiography laboratory were stored on the server and subject to standard reporting in 91% and 73%, respectively. For studies performed outside the laboratory (eg, clinic, emergency room, acute coronary unit), these percentages decreased to 74% and 60%. The echocardiography laboratories had a registry of indications in 26.5% (the most frequent were ventricular function, arrhythmias, and cardiac valve regurgitation), a registry of events in 47%, and internal quality control procedures in 48% (local protocols, 72%; expert review of reports, 65%; analysis of variability, 40%). Of the total number of attending physicians who performed echocardiography, Spanish or European accreditation had been obtained in transthoracic echocardiography by 26.6%, in transesophageal echocardiography by 8.9%, and in congenital diseases by 3.6%.

With regard to nonechocardiographic imaging, [Table 2](#) shows the number of studies performed with each technique according to the complexity of the institution. The main indications for cardiac computed tomography were screening for coronary disease (52%), valve disease study (18%), and study prior to percutaneous aortic valve placement (12%). Overall, 96% of detectors were arrays of 64 or more. Cardiologists participated in the acquisition, analysis, and signing of the report in 56%, 65%, and 56% of cases, respectively. Overall, 30% of the centers had an analysis station in the cardiology