

Image in cardiology

# Aortic Thrombosis, a Rare Cause of Acute Myocardial Infarction in Young Patients



## Trombosis aórtica como causa de infarto de miocardio en paciente joven

Pilar García-González,\* Mónica Ferrando-Beltrán, and Francisco Pomar-Domingo

Servicio de Cardiología, Consorcio Hospital General Universitario de Valencia, Valencia, Spain

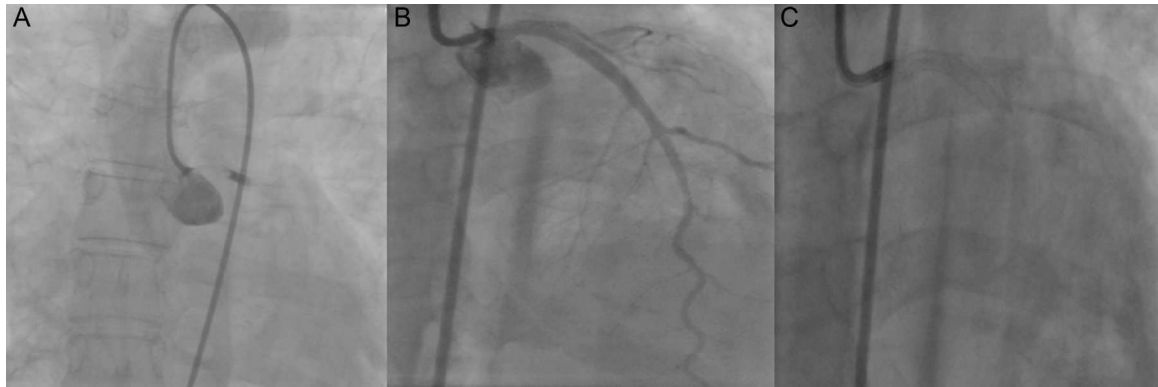


Figure 1.

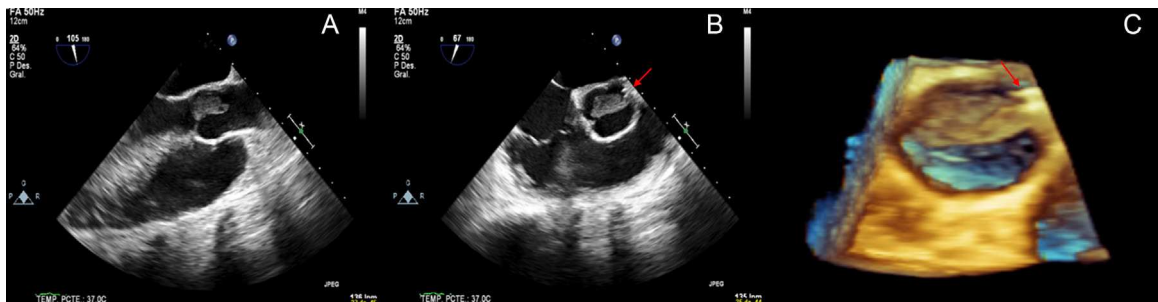


Figure 2.

A 40-year-old woman with no cardiovascular risk factors consulted for chest pain. The electrocardiogram showed ST-segment elevation in the anterior leads. Emergency coronary angiography demonstrated an image consistent with an occlusive thrombus in the left main coronary artery. A guidewire was inserted, the occlusion resolved, and flow was restored in the entire coronary vasculature; intracoronary ultrasound imaging showed no signs of thrombus or coronary artery dissection. The patient was transferred to our center for an acute anterolateral myocardial infarction. Upon arrival, she presented a recurrence of precordial pain, a new ST-segment elevation, and cardiogenic shock. A second coronary angiography showed complete occlusion of the left main coronary artery by a mass consistent with a thrombus. With the patient under inotropic support and intraaortic counterpulsation, a stent was placed in the left main coronary artery, and coronary flow was restored (Figure 1). Transthoracic echocardiography showed severe biventricular systolic dysfunction and a mass in the aortic root, confirmed by 2- and 3-dimensional transesophageal echocardiography (Figure 2) as a 30-mm thrombotic mass anchored at the left main coronary artery ostium and stent (arrow) and progressing toward the aortic valve. Finally, a ventricular assist device had to be implanted as a bridge to heart transplantation. The mass disappeared, likely related to the anticoagulant therapy administered.

The presence of thrombi in the ascending aorta is a rare cause of acute myocardial infarction. The diagnosis should be made with transesophageal echocardiography, which enables characterization of the mass and establishment of the differential diagnosis with other masses. Treatment of this condition is controversial. The recommended options are anticoagulation, and when this measure fails, thrombectomy.

\* Corresponding author:

E-mail address: [pilargaron84@gmail.com](mailto:pilargaron84@gmail.com) (P. García-González).

Available online 1 March 2014