

## Arrhythmogenic Right Ventricular Dysplasia in the Elderly

### To the Editor,

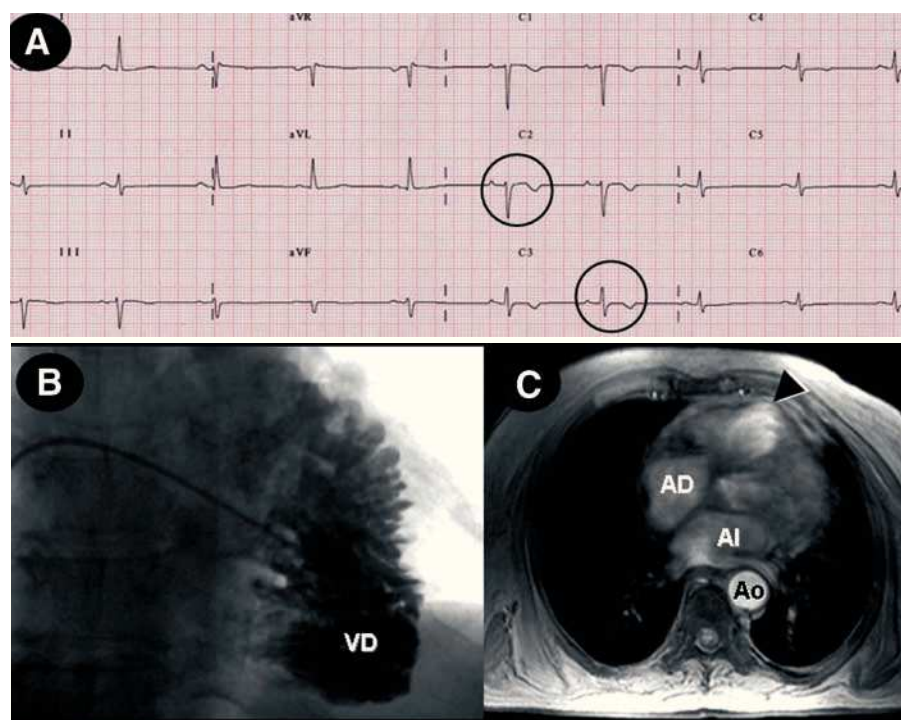
The prevalence of arrhythmogenic right ventricular dysplasia (ARVD) varies widely according to the series and the geographical area, and accounts for 5% of all sudden deaths in patients <65 years old.<sup>1</sup> This condition is an autosomal dominant disease with variable penetrance and incomplete expression. A higher prevalence is observed in men, and a family history is found in about 30% of patients.<sup>2</sup> The mean age at diagnosis is around 30 years, whereas presentation in patients >65 years old is rare.

We describe the case of a 76-year-old man with a history of benign prostatic hyperplasia, but no cardiovascular risk factors. The family history included death of 2 brothers at age 50 and 60 due to uncertain causes, as well as death of a sister at age 11, also for unknown reasons; two of the patient's sons had died accidentally. The patient consulted for mid-chest discomfort, dizziness, and palpitations; the electrocardiogram showed regular, monomorphic wide QRS complex tachycardia and a left bundle-branch block morphology. Tachycardia persisted following administration of intravenous amiodarone and electrical cardioversion was performed; sinus rhythm was restored with left anterior bundle-branch block and negative T-waves in V<sub>2</sub> and V<sub>3</sub>.

The echocardiogram showed good function of the left ventricle (LV) and dysfunction of the right ventricle (RV) with dilation (43 mm), but no valve abnormalities or evidence of pulmonary hypertension (Figure 1A). Catheterization revealed RV dilation and considerable trabeculation with a "stack of coins" image, as well as normal pulmonary pressure; the LV and coronary arteries were normal (Figure 1B). Magnetic resonance imaging (Figure 1C) showed RV dilation with an area of apical dyskinesia and wall thinning. Holter monitoring disclosed 352 premature ventricular beats, with no episodes of ventricular tachycardia (VT). An electrophysiological study performed after intravenous amiodarone for several days showed ventricular electric stability.

Based on the presence of diagnostic criteria for ARVD,<sup>2</sup> the patient was diagnosed with this condition, and because he had experienced VT while under amiodarone therapy, a single-chamber defibrillator was implanted.<sup>3</sup> He subsequently had episodes of paroxysmal atrial fibrillation that triggered inappropriate discharges and in the following months, presented VT that was controlled with sotalol 160 mg/day.

A search of the Medline database (National Library of Medicine, Bethesda, MD) found 5 cases of ARVD among the elderly<sup>4-7</sup>; all of these patients had died and were diagnosed by histology (Table). One patient was diagnosed at 72 years,



**Figure 1.** A: baseline electrocardiogram shows negative T waves in V<sub>2</sub> and V<sub>3</sub> (circles). B: right ventriculography discloses dilation of the right ventricle (RV) and “stack of coins” image. C: magnetic resonance image showing apical aneurysm (arrow).

**TABLE. Cases of Arrhythmogenic Right Ventricular Dysplasia in Elderly Patients Reported in the Literature\***

Case	Age, Y	Sex	VT	ECG	Autopsy	Author and Literature Reference
1	76	Male	Yes	T(–) V <sub>2</sub> , V <sub>3</sub>	No	Present case
2	72 <sup>†</sup>	Male	Yes	AF, T (–) V <sub>2</sub> , V <sub>3</sub>	Yes	Kamide K et al <sup>4</sup>
3	76	Female	Yes <sup>‡</sup>	T (–) V <sub>2</sub> , V <sub>3</sub> , ? QTc	Yes	Barriales et al <sup>5</sup>
4	74	Male	Yes	R V <sub>2</sub> through V <sub>6</sub> and e waves	Yes	More D et al <sup>6</sup>
5	73	Male	No	R V <sub>2</sub> through V <sub>6</sub> and e waves	Yes	
6	84	Female	No	CAVB, T (–) V <sub>2</sub>	Yes	Ferreira AC et al <sup>7</sup>

\*CAVB indicates complete atrioventricular block; AF, atrial fibrillation.

<sup>†</sup>This patient presented clinical symptoms of recurrent ventricular tachycardia from age 45, although the diagnosis was made at age 72.

<sup>‡</sup>This patient presented polymorphic ventricular tachycardia.

although he had presented a history of VT from age 45.<sup>4</sup> The mean patient age was 75.8 years; 4 were men and 2, women. None of the cases mentioned a family history, except for the present case. Four had presented VT, one of them polymorphic VT,<sup>5</sup> which, even though it is not the characteristic type, has been described in some cases of ARVD. The most frequent electrocardiographic findings were negative T-waves in the right precordials (V<sub>2</sub> and V<sub>3</sub>), and in two cases, epsilon waves.<sup>7</sup>

New pharmacological therapies, radio frequency ablation, and defibrillators<sup>3</sup> will probably have a favorable impact on the survival of these patients and will make it not unlikely to see elderly patients with ARVD. The possibility of a late onset of the disease should also be suspected. A two-chamber defibrillator in these patients could improve the diagnosis of supraventricular arrhythmias, because they are elderly patients in whom the prevalence of atrial fibrillation is increased and because inappropriate therapies for supraventricular tachyarrhythmia may be more common among patients with ARVD.<sup>8</sup>

Antonio García-Quintana, José R. Ortega-Trujillo, and Alfonso Medina Fernández-Aceytuno

Servicio de Cardiología, Hospital Universitario de Gran Canaria Dr. Negrín, Las Palmas de Gran Canaria, Spain

## REFERENCES

1. Aguilera B, Suárez Mier MP, Morentin B. Miocardiopatía arritmogénica como causa de muerte súbita en España. Presentación de 21 casos. *Rev Esp Cardiol.* 1999;52:656.
2. Tome Esteban MT, García-Pinilla JM, McKenna WJ. Update in arrhythmogenic right ventricular cardiomyopathy: genetic, clinical presentation and risk stratification. *Rev Esp Cardiol.* 2004;57:757-67.
3. Corrado D, Leoni L, Link MS, della Bella P, Gaita F, Curnis A, et al. Implantable cardioverter-defibrillator therapy for prevention of

- sudden death in patients with arrhythmogenic right ventricular cardiomyopathy/dysplasia. *Circulation*. 2003;108:3084-91.
4. Kamide K, Satoh S, Okamoto K, Ueda T, Katoh H, Nakano S, et al. A case of arrhythmogenic right ventricular dysplasia with left and right ventricular hypofunction in an elderly subject: long-term follow-up. *Jpn Circ J*. 1997;61:872-6.
  5. Barriales V, Tamargo JA, Aguado MG, Martín M, Rondan J, Posada IS. Electrical storm as initial presentation of arrhythmogenic right ventricular cardiomyopathy in an elderly woman. *Int J Cardiol*. 2004;94:331-3.
  6. More D, O'Brien K, Shaw J. Arrhythmogenic right ventricular dysplasia in the elderly. *Pacing Clin Electrophysiol*. 2002;25:1266-9.
  7. Ferreira AC, García SA, Pasquale MA, Canoniero MJ, Peter A. Arrhythmogenic right ventricular dysplasia in the elderly. *Heart Dis*. 2003;5:393-6.
  8. Tavernier R, Gevaert S, de Sutter J, De Clercq A, Rottiers H, Jordaens L, et al. Long term results of cardioverter-defibrillator implantation in patients with right ventricular dysplasia and malignant ventricular tachyarrhythmias. *Heart*. 2001;85:53-6.