

## Balloon Angioplasty for Native Coarctation in Children: Immediate and Medium-Term Results

María J. del Cerro, Aurora Fernández-Ruiz, Fernando Benito, Dolores Rubio, María C. Castro, and Felipe Moreno

Servicio de Cardiología Pediátrica, Hospital Infantil La Paz, Madrid, Spain.

**Introduction and objectives.** The use of balloon angioplasty to treat native aortic coarctation in pediatric patients is controversial. Our aims were to report our experience with this technique and to compare retrospectively the immediate and medium-term results obtained during 2 different time periods.

**Subjects and method.** 53 patients who underwent balloon angioplasty for native coarctation were divided into 2 groups: (A) those treated between 1985-1988 (n=26); and (B) those treated between 1993-2003 (n=27). Follow-up data were available for all patients.

**Results.** The immediate result was good (i.e., pressure gradient, <20 mm Hg) in 18/26 patients in group A (69.2%) and 22/27 (81.5%) in group B. On follow-up, the recoarctation rate was similar in both groups: 33% in group A and 25.6% in group B. Group A patients with recoarctation were referred for surgery, whereas five group B patients underwent a second angioplasty (either balloon or stent). At the end of follow-up, angioplasty had been successful in 62% (16/26) of patients in group A vs 85% (23/27) in group B. The incidence of serious complications was lower in group B (4%) than group A (19.2%), as was the incidence of aneurysm: 4% in group B vs 15% in group A.

**Conclusions.** Balloon angioplasty is an effective alternative to surgery for the treatment of native, localized aortic coarctation. Better selection of suitable patients, use of low-profile catheters, and improved patient care can reduce the incidence of complications. Repeat angioplasty (either balloon or stent) in cases of recoarctation has improved results with this technique.

**Key words:** *Native coarctation. Balloon angioplasty. Congenital cardiac defects. Pediatrics.*

### Angioplastia con balón de la coartación nativa en la edad pediátrica: resultado inicial y a medio plazo

**Introducción y objetivos.** La angioplastia percutánea de la coartación nativa en la edad pediátrica es una técnica controvertida. El objetivo de este estudio es aportar nuestra experiencia con esta técnica, y comparar retrospectivamente los resultados obtenidos en 2 períodos distintos.

**Sujetos y método.** Los 53 pacientes tratados con angioplastia se dividieron en 2 grupos: a) tratados entre 1985 y 1988 (n = 26), y b) tratados entre 1993 y 2003 (n = 27). Se realizó seguimiento en todos.

**Resultados.** La angioplastia fue inicialmente efectiva (gradiente < 20 mmHg) en 18/26 pacientes del grupo A (69,2%), y en 22/27 (81,5%) en el grupo B. Presentaron recoartación el 33% del grupo A y el 25,6% del grupo B. Los pacientes recoartados del grupo A fueron derivados a cirugía, mientras que en 5 pacientes del grupo B se realizó una segunda angioplastia. Al final del seguimiento, se había conseguido una angioplastia efectiva en el 62% (16/26) en el grupo A frente al 85% (23/27) en el grupo B. La incidencia de complicaciones graves fue menor en el grupo B (4%) que en el A (19,2%), así como la de aneurismas (grupo B: 4%; grupo A: 15%).

**Conclusiones.** La angioplastia percutánea es una alternativa eficaz en el tratamiento de la coartación nativa, circunscrita. La mejor selección de los casos, la utilización de balones de menor perfil y la optimización de los cuidados generales puede disminuir la incidencia de complicaciones. La aplicación de una segunda angioplastia (simple o con *stent*) en los casos de recoartación ha mejorado los resultados de esta técnica.

**Palabras clave:** *Coartación nativa. Angioplastia con balón. Defectos cardíacos congénitos. Pediatría.*

SEE EDITORIAL ON PAGES 1010-3

Correspondence: Dra. M.J. del Cerro Marín.  
Servicio de Cardiología Pediátrica. Hospital Infantil La Paz.  
Paseo de la Castellana, 261. 28046 Madrid. España.  
E-mail: mcerro.hulp@salud.madrid.org

Received October 18, 2004.  
Accepted for publication May 13, 2005.

## INTRODUCTION

Since its introduction in the field of congenital heart disease, balloon angioplasty has replaced surgery as first choice in the treatment of various stenotic lesions (pulmonary and aortic stenosis, pul-

## ABBREVIATIONS

PTA: percutaneous transluminal angioplasty.

Fr: French.

MRI: magnetic resonance imaging.

monary artery stenosis, postsurgery recoarctation). However, 22 years after its initial implementation,<sup>1,2</sup> balloon angioplasty of native coarctation continues to be a controversial technique. Following the initial enthusiasm raised by its effectiveness as described in the first clinical experiences,<sup>3,4</sup> the use of this technique became restricted due to the reported incidence of early recoarctation<sup>5-7</sup> and, in particular, the development of aneurysms in the angioplasty site.<sup>8-11</sup> Despite this, several groups have continued to use balloon angioplasty as the treatment of choice for localized coarctation. Published results,<sup>12-15</sup> along with long-term follow-up studies,<sup>16-19</sup> show results comparable to those of surgery, as well as the absence of progression of the aneurysm in some cases. This, together with the increasingly known incidence of aortic aneurysms in coarctation patients treated surgically,<sup>20,21</sup> has kept the debate open regarding the treatment of choice of aortic coarctation after the neonatal period.

Our experience with the percutaneous treatment of coarctation began in 1985<sup>22</sup> (3 years after the publication of the first cases); the technique was dropped in 1988 due to the observed incidence of aneurysms in our series, whose long-term prognosis was then uncertain. Five years later, in 1993, in view of the results published by groups that had continued to use

this technique,<sup>12,15,17</sup> we began to use balloon angioplasty again, initially in coarctations carrying greater surgical risk (absence of collateral circulation) and, shortly afterwards, we used it as treatment of first choice in patients older than 3 months with localized coarctation.

## OBJECTIVES

The objectives of our work are: 1) to share our experience, regarding both the results and medium-term follow-up when using this technique; and 2) to compare retrospectively the results and complications of the angioplasties done in our service in the following 2 periods: between 1985 and 1988, and 1993 and 2003.

## SUBJECTS AND METHODS

The clinical, hemodynamic, and echocardiographic data of pediatric patients undergoing percutaneous angioplasty of native coarctation between March 1985 and April 2003 were analyzed retrospectively. The patients were classified into 2 groups according to when angioplasty had been done: group A (patients treated between March 1985 and July 1988) and group B (patients treated between May 1993 and April 2003). Table 1 shows the data of both groups. Group A included patients older than 3 months diagnosed with coarctation with a peak pressure gradient >20 mm Hg. Group B included patients of any age with localized lesions and a pressure gradient >20 mm Hg; patients with Turner's or Noonan's syndrome were excluded.

After obtaining informed consent from relatives, catheterization was done under sedation in Group A and under general anesthesia in group B. Percutaneous access was via the femoral artery and vein in all cases, with heparinization at 100 U/kg. After angiographic

TABLE 1. Characteristics of the Study Population

	Group A (1985-1988) (n=26)	Group B (1993-2003) (n=27)	P
Age, years	(0.04-15) 6.5±4.5	(0.06-16) 6.6±5.5	NS
Weight, kg	(4.8-60) 24±14.8	(3-66) 25±19.3	NS
Grad. pre, mm	(18-65) 43.1±12.2	(21-65) 37±11.4	NS
Grad. post, mm	(0-45) 13.9±12.6	(0-30) 12.5±8	NS
Diameter pre, mm	(1.7-12) 4.1±2.1	(1.3-10) 4.3±2.3	NS
Diameter post, mm	(2.3-16) 8±3.4	(4.5-21) 9.2±3.6	NS
Balloon diameter, mm	(4-18) 11.8±3.7	(5-20) 11.2±3.9	NS
Balloon/Co	(1.5-5) 3.2±0.9	(1.6-5) 2.9±1	NS
Balloon/Ao. diaphrag.	(0.75-1.4) 1.03±0.2	(0.66-1.2) 0.94±0.13	NS
Follow-up, years	(0.008-18) 5.5±4.9	(0.2-11) 3.59±2.8	NS

\* Balloon/Ao indicates balloon diameter-diaphragmatic aorta diameter relationship; balloon/Co, balloon diameter-stenosis diameter relationship; diameter pre, pre-angioplasty coarctation diameter; diameter post, postangioplasty coarctation diameter; grad. pre, preangioplasty ascending-descending aortic peak pressure gradient; grad. post, postangioplasty ascending-descending aortic peak pressure gradient; follow-up, follow-up time (years); NS, nonsignificant.

study [aortography, anteroposterior (AO) and left anterior oblique (LAO) projections) and establishing the pressure gradient, a balloon was selected whose diameter was 2-4 times greater than that of the stenosis, while ensuring that it did not exceed the caliber of the diaphragmatic aorta. The balloon was introduced via an exchange guidewire placed in the ascending aorta and, after percutaneous transluminal angioplasty (PTA), this was replaced, via the guidewire, by pigtail or multipurpose catheters which were used for AP and LAO angiographies and pressure measurements. The coarctation diameters, pre- and post-angioplasty pressure gradients, and balloon-stenosis and balloon-diaphragmatic aorta relationships are shown in Table 1. In Group A arterial sheaths between 5 Fr to 11 Fr ( $9.1 \pm 1.29$ ) were used, whereas in group B the sheaths were between 5 Fr and 10 Fr ( $6.5 \pm 1.27$ ), thanks to the low profile of the angioplasty catheters available in that period.

All patients underwent clinical check-ups and echocardiography at follow-up. Catheterization was repeated in 13 of the 26 patients in Group A and magnetic resonance imaging (MRI) in 3. In group B new catheterization was performed in 7 patients and MRI in 10. The cumulative incidence of recoarctation or aneurysm was assessed in particular, and the possible factors involved in their appearance analyzed. The following variables were explored as patient factors: age (more than or less than 1 year), lesion and diaphragmatic aorta diameters, and pressure gradient prior to angioplasty. The following variables were explored as technique-dependent factors: immediate result (pressure gradient more than or less than 20 mm Hg), diameter of the angioplasty balloon used, balloon diameter-stenosis diameter relationship, and balloon diameter-diaphragmatic aorta diameter relationship.

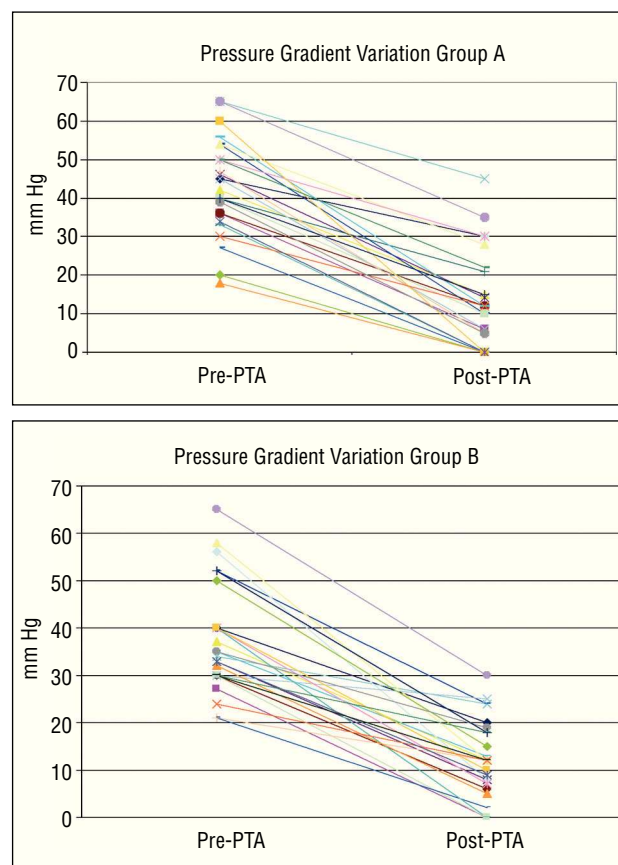
## Statistical Analysis

Continuous variables are expressed as mean  $\pm$  standard deviation and discrete variables as absolute value and percentage. The Student's *t* test was used to compare continuous variables and the Fisher exact test for discrete variables. The Kaplan-Meier test and log-rank test were used to compare the time elapsed up to the appearance of recoarctation or aneurysm in the patients in group A and B. A value of  $P < .05$  was considered statistically significant.

## RESULTS

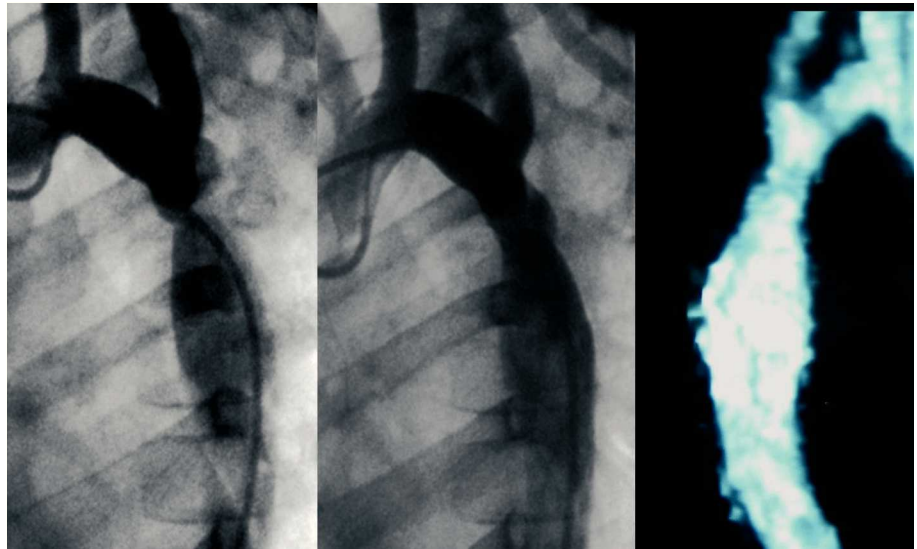
There were no significant differences between the 2 groups regarding decrease in pressure gradient (Figure 1 and Table 1) and increase in stenosis caliber (Table 1). Initially, angioplasty was successful (immediate postangioplasty peak pressure gradient  $< 20$  mm Hg) in

18 (69.2%) of 26 patients in group A versus 22 (81.5%) of 27 patients in group B (Figures 2 and 3). At follow-up, there were no significant differences in the observed incidence of recoarctation (hemodynamic or pressure gradient  $> 20$  mm Hg): 33% in group A versus 25.9% in group B. Possible factors related to the development of recoarctation were analyzed in both groups (Table 2); a greater incidence of recoarctation was found in the patients in whom angioplasty had been only partially effective (immediate postangioplasty residual pressure gradient  $> 20$  mm Hg) and in the patients with more severe coarctations (greater incidence of recoarctation to a greater pre-PTA pressure gradient,  $P = .015$ ; and to a smaller pre-PTA stenosis diameter,  $P = .007$ ). The incidence of recoarctation was greater in the patients younger than 1 year old, although this difference did not reach statistical significance; however, it did so with a *P*-value ( $P = .144$ ) close to significance (Table 2). Patients with recoarctation in group A were directly referred to surgery (Figure 4), whereas a second angioplasty was done in 5 patients from group B (balloon in 3 cases and stenting in 2), with a good result (Figure 4). At the end of the

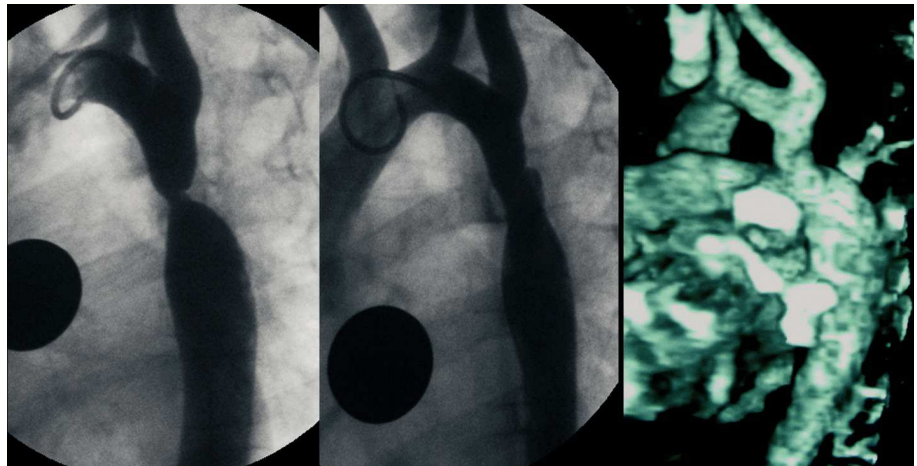


**Figure 1.** Variations in the pre- and postangioplasty ascending-descending aortic peak pressure gradient (mm Hg) in group A (angioplasties done between 1985 and 1988) and group B (angioplasties done between 1993 and 2003). PTA indicates percutaneous transluminal angioplasty.

**Figure 2.** Six-year-old patient (group B) with severe coarctation (peak pressure gradient 40 mm Hg) and hypertension (147/95) treated with angioplasty (postangioplasty pressure gradient 7 mm Hg). Left: preangioplasty aortography, 45° left anterior oblique projection. Center: postangioplasty aortography. Right: magnetic resonance imaging done 2 years after angioplasty shows no aneurysm image; the patient presents normal blood pressure values (110/65) and absence of arm-leg pressure gradient.



**Figure 3.** Five-year-old patient (group B) with severe coarctation (peak pressure gradient 50 mm Hg) and severe hypertension treated with angioplasty (postangioplasty pressure gradient 15 mm Hg). Left: preangioplasty aortography. Center: postangioplasty aortography. Right: magnetic resonance imaging done 2 years after the angioplasty, without aneurysm image.



**TABLE 2. Factors Related to the Development of Recoarctation at Follow-up\***

Residual Pressure Gradient	Recoarctation	P
Less than 20 mm Hg	6/38 (15.08%)	.001
Greater than 20 mm Hg	9/13 (69.2%)	
Age	Recoarctation	
Less than 1 year old	3/5 (60%)	.144
More than 1 year old	12/46 (26.1%)	

\*Fisher exact test.

Residual pressure gradient indicates immediate post-PTA residual pressure gradient.

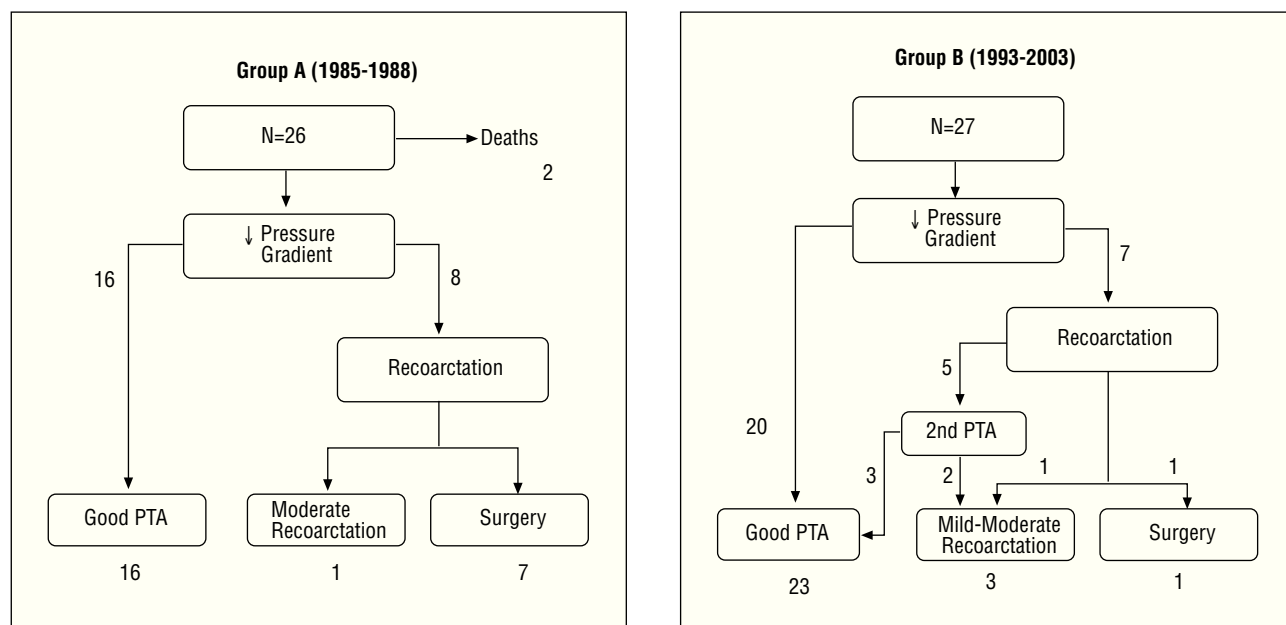
Note: the total number of patients in whom the development of recoarctation was evaluated is 51, since 2 patients from group A who died within 24 h of the procedure were excluded.

follow-up period (Figure 5), in group A, 16 (62%) patients remained free from recoarctation, 7 (26.9%) had been referred to surgery due to recoarctation or aneurysm, and 1 remained with moderate recoarcta-

tion having refused surgery or new angioplasty. Out of the 27 patients in group B, 23 (85%) remained asymptomatic and free of recoarctation at the end of the follow-up period (Figure 5); only 1 (3.7%) had needed surgery (1-month-old patient at the time of angioplasty), and 3 had presented mild-moderate recoarctation.

The incidence of serious complications was greater in group A (19.2%) than in group B (3.7%), although the difference was not statistically significant. There were 5 complications in Group A: 2 deaths in the 24 h following the procedure (an aortic dissection in 1 patient with Turner's syndrome, and 1 infant with associated subaortic stenosis), 1 heart failure in the catheterization unit, and 2 arterial ischemias that required surgical thrombectomy. An acute stroke was recorded in group B which the patient recovered from with mild sequelae.

The incidence of aneurysms was also less in group B (3.7%) than in group A (15%), although the difference was not significant. In the statistical study, no patient



**Figure 4.** Evolution during follow-up in patients in group A (angioplasties done between 1985 and 1988) and group B (angioplasties done between 1993 and 2003). PTA indicates percutaneous transluminal angioplasty.

factors (age, weight, severity of coarctation) nor angioplasty factors (balloon diameter-stenosis diameter relationship, balloon-diaphragmatic aorta relationship) were found to be related to the development of aneurysms. Of the 4 patients in group A who developed aneurysm, 2 underwent surgery because they also presented recoarctation in the other 2, we decided conservative treatment and no increase in aneurysm was observed after a follow-up time of 18 years and 15 years (Figure 6), respectively. No increase in aneurysm was found in the only patient in group B who developed this complication after a 2.5-year follow-up.

## DISCUSSION

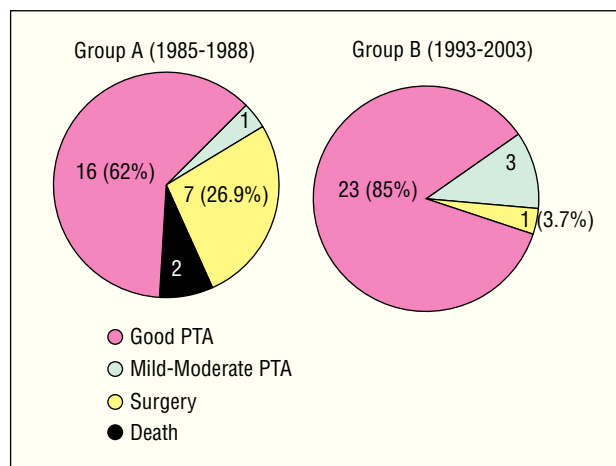
The results obtained from treating native coarctation with angioplasty in our series are comparable to the reported by other groups regarding the initial efficacy of the technique, incidence of recoarctation, and appearance of aneurysms.<sup>14,15,19,23</sup>

When comparing the results obtained in the 2 series (angioplasties performed between 1985 and 1988, and between 1993 and 2003), it is important to note that:

1. The population characteristics, the severity of coarctation, and the angioplasty technique (balloon-stenosis relationship, balloon-diaphragmatic aorta relationship) were very similar in both groups; this would explain the similarity of the initial result obtained in both series. The greater incidence of recoarctation found in the patients younger than 1 year old matches reports from other series,<sup>6,7,24</sup> and might be accounted for by the greater amount of ductal tissue in

these patients. Although the longer follow-up time in the patients in group A could act as a confounding factor when comparing the incidence of recoarctation or aneurysm between group A and B, the Kaplan-Meier analysis did not show significant differences regarding the time elapsed up to the appearance of recoarctation or aneurysm between the 2 groups (Figure 7). In fact, of the 15 patients (out of both groups) who developed recoarctation, 86.6% (13/15) did so within the first 2 years of follow-up.

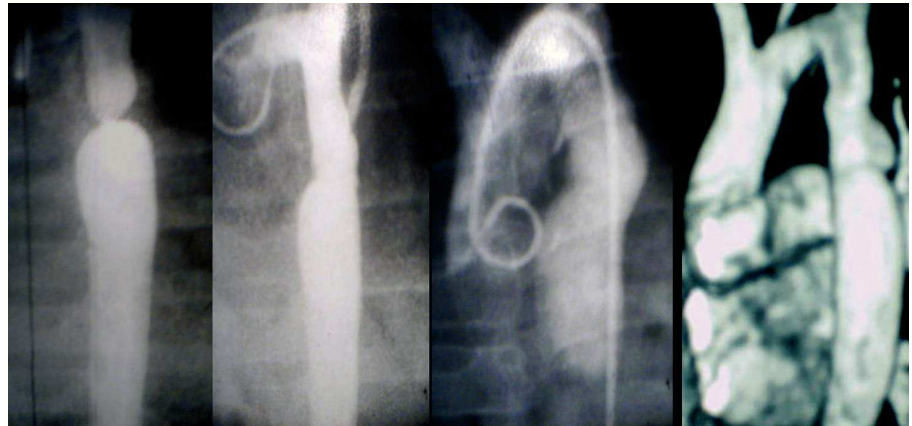
2. Performing a second angioplasty (simple or with *stent*) in 5 of the cases of recoarctation in group B accounts for the better results at the end of the follow-up time in group B (85% of patients free of restenosis)



**Figure 5.** Comparison of the angioplasty results in groups A and B at the end of the follow-up period.



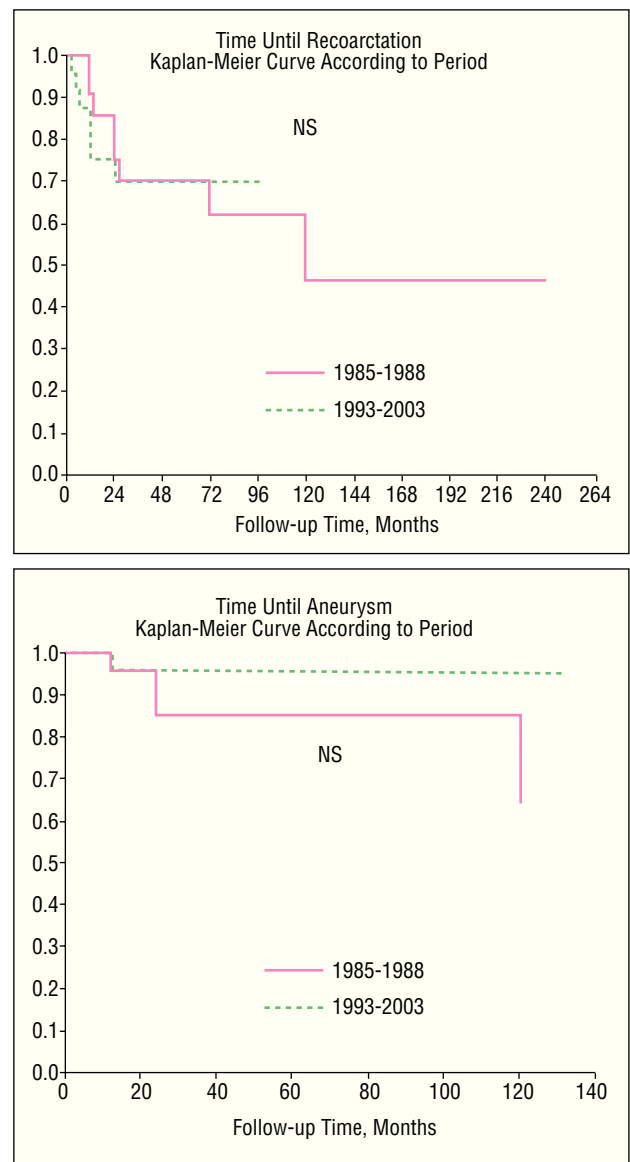
**Figure 6.** Patient (group A) with development of postangioplasty aneurysm. Left to right: pre-PTA angiography; immediate post-PTA angiography; angiographic control 6 years after PTA; MRI control 15 years after PTA. PTA indicates percutaneous transluminal angioplasty.



than in group A (62%), despite a similar incidence of recoarctation. The use of a second angioplasty drastically changed the percentage of patients who, after percutaneous angioplasty, needed surgery: 27% in group A versus 3.7% in group B (a single patient, with neonatal coarctation). Patients who had mild to moderate pressure gradients at the end of the follow-up period undergo a new angioplasty when indicated by the severity of the injury.

3. Another important difference between the groups was the lower incidence of complications found in group B (3.7% vs 19.2% in group A), although the difference was not statistically significant due to the relatively limited number of cases in each group. This reduction is explained by the better selection of cases (e.g. excluding patients with syndromes associated with anomalies of the aortic wall, such as Turner's syndrome), the use of low-profile balloons thus reducing arterial complications, as well as optimization of the general and anesthetic care received by the patient during catheterization and in the following 24 h.

4. Regarding the observed incidence of aneurysms, and in line with other works,<sup>10</sup> we did not find a relation between their appearance and the balloon-diaphragmatic aorta or balloon-stenosis relationship. Factors dependent on the patient and the lesion itself (presence and extension of the cystic medial necrosis<sup>8</sup>) may also influence the development of postangioplasty aneurysms. In any case, we consider that after percutaneous angioplasty of coarctation, long-term follow-up using MRI<sup>25</sup> is fundamental to rule out the appearance of aneurysms. One of the possible limitations of our study is precisely the fact that MRI/catheterization could not be done in 100% of the patients, which means that some small aneurysms could have passed unnoticed despite x-ray and echocardiography. We do not think that the shorter follow-up time of some patients in group B accounts for the lower incidence (although insignificant) of aneurysms in group B than in group A: the Kaplan-Meier analysis did not show significant dif-



**Figure 7.** Kaplan-Meier curves: comparison between the time elapsed until the appearance of recoarctation or aneurysm in groups A and B. NS indicates not significant.

ferences between the groups regarding the time elapsed until the appearance of the aneurysm (Figure 7). In fact, of the 5 patients (from both groups) who developed recoarctation, 80% (4/5) did so within the first 2 years of follow-up. Another interesting fact of our study is that the 2 patients with aneurysms who chose conservative treatment did not show significant increases in this regard at long-term follow-up (15 years), which has also been reported by other authors.<sup>11,15,19,26</sup>

The results of our study, as well as those published by other groups, lead to the following question: if, on the one hand, we are capable of effectively treating postangioplasty recoarctations percutaneously,<sup>24</sup> and improving the results by using stents<sup>27-29</sup> while taking into account that not all aneurysms found need surgical treatment; and, on the other hand, if the patients treated surgically also present recoarctations and can also develop aneurysms,<sup>20,21</sup> should surgery continue to be the treatment of choice for native and localized coarctation, after the neonatal period? To answer this question we need to undertake comparative studies of the 2 techniques,<sup>30-32</sup> preferably randomized prospective ones, with a large number of patients and long-term follow-up. These types of studies, although few,<sup>33,34</sup> seem to indicate that the 2 techniques have comparable efficacy, with a greater incidence of recoarctation after angioplasty versus a greater incidence of serious complications<sup>34</sup> and greater economic cost<sup>33</sup> with surgical treatment.

## Study Limitations

The relatively low number of patients in the study subtracted power from the statistical comparison; some very striking differences proved insignificant, such as the lower incidence of serious complications or of aneurysms in group B (3.7% vs 9.2% for complications, and 3.7% vs 15% for aneurysms). Although the greater follow-up time in the group A patients could act as a confounding factor when comparing the incidence of recoarctation or aneurysm between the 2 groups, the Kaplan-Meier analysis did not show significant differences between the 2 groups in the time elapsed up to the appearance of recoarctation or aneurysm (Figure 7).

## CONCLUSIONS

1. Balloon angioplasty is an effective alternative treatment for native, localized aortic coarctation.

2. Better selection of patients, low-profile balloons, and optimization of general care can reduce the incidence of complications.

3. A second angioplasty (simple or with stenting) in cases of recoarctation has improved the results of this technique in the medium-long term.

## REFERENCES

- Sos T, Sniderman KW, Rettek-Sos B, Strupp A, Alonos D. Percutaneous transluminal dilatation of coarctation of the aorta post-mortem. *Lancet*. 1979;2:970-1.
- Lock JE, Neimi BA, Burke B, Enzig S, Cataneda-Zuñiga WR. Transcatheter angioplasty of experimental aortic coarctation. *Circulation*. 1982;66:1280.
- Lock JE, Bass JL, Amplatz K, Fuhrman B, Castaneda-Zuñiga WR. Balloon dilation angioplasty of aortic coarctation in infants and children. *Circulation*. 1983;68:109-16.
- Lababidi Z, Daskalopoulos DA, Stoeckle H Jr. Transluminal balloon angioplasty: experience with 27 patients. *Am J Cardiol*. 1984;54:1288-91.
- Rao PS, Thapar MK, Kutaily F, Carey P. Causes of recoarctation after balloon angioplasty of unoperated aortic coarctation. *J Am Coll Cardiol*. 1989;13:109-5.
- Redington AN, Booth P, Shore DF, Rigby ML. Primary balloon dilatation of coarctation of the aorta in neonates. *Br Heart J*. 1990;64:277-81.
- Rao PS, Thapar MK, Galal O, Wilson AD. Follow-up results of balloon angioplasty of native coarctation in neonates and infants. *Am Heart J*. 1990;120:1310-4.
- Isner JM, Donaldson RF, Fulton D, Bhan I, Payne DD, Cleveland J. Cystic medial necrosis in coarctation of the aorta: potential factor contributing to adverse consequences after percutaneous balloon angioplasty of coarctation sites. *Circulation*. 1987;75:689-95.
- Fontes VF, Esteves CA, Braga SL, Da Silva MV, MA ES, Sousa JE, et al. It is valid to dilate native aortic coarctation with a balloon catheter. *Int J Cardiol*. 1990;27:311-6.
- Tynan M, Finley JP, Fontes V, Hess J, Kan J. Balloon angioplasty for the treatment of native coarctation: results of valvuloplasty and angioplasty of congenital anomalies registry. *Am J Cardiol*. 1990;65:790-2.
- Ray DG, Subraman R, Titus T, Tharakan J, Joy J, Venkitachalan CG, et al. Balloon angioplasty for native coarctation of the aorta in children and adults: factors determining the outcome. *Int J Cardiol*. 1992;36:273-81.
- Rao PS, Chopra PS. Role of balloon angioplasty in the treatment of aortic coarctation. *Ann Thorac Surg*. 1991;52:621-31.
- Ledesma M, Ramírez H, Aldana T, Acosta JL, Munayer J, Carpio JC, et al. Angioplastia transluminal percutánea de coartación aórtica en adolescentes y adultos. Resultados a mediano plazo. *Arch Inst Cardiol Méx*. 1992;62:339-43.
- Tyagi S, Arora R, Kaul UA, Sethi KK, Gambhir DS, Khalilullah M. Balloon angioplasty of native coarctation of the aorta in adolescents and young adults. *Am Heart J*. 1992;123:674-80.
- Fletcher SE, Nihill MR, Grifka RG, O'Laughlin MP, Mullins CE. Balloon angioplasty of native coarctation of the aorta: mid-term follow-up and prognostic factors. *J Am Coll Cardiol*. 1993;23:730-4.
- Mendelsohn AM, Lloyd TR, Crowley DC, Sandhu SK, Kocis KC, Beekman RH. Late follow-up of balloon angioplasty in children with a native coarctation of the aorta. *Am J Cardiol*. 1994;74:696-700.
- Smith PA, Wilson AD, Rao PS, Galal O. Five-to nine-year follow-up results of balloon angioplasty of native aortic coarctation in infants and children. *J Am Coll Cardiol*. 1996;27:462-70.
- Walhout RJ, Lekkerkerker JC, Ernst SM, Hutter PA, Plokker TH, Meijboom EJ. Angioplasty for coarctation in different aged patients. *Am Heart J*. 2002;144:180-6.
- Fawzy ME, Awad M, Hassan W, Al Kadhi Y, Shoukri M, Fadley F. Long-term outcome (up to 15 years) of balloon angioplasty of discrete native coarctation of the aorta in adolescents and adults. *J Am Cardiol*. 2003;43:1062-7.
- Knyshov GV, Sitar L, Glagola MD, Atamanyuk MY. Aortic aneurysm at the site of the repair of coarctation of the aorta: a review of 48 patients. *Ann Thorac Surg*. 1996;61:935-9.

21. Kodolitsch Y, Aydin MA, Koschyk DH, Loose R, Schalwat I, Karck M, et al. Predictors of aneurismal formation after surgical correction of aortic coarctation. *J Am Coll Cardiol.* 2002;39:617-24.
22. García-Aguado A, Benito F, Fernández A, García-Guereta L, Jiménez T, Sanz E, et al. Angioplastia y valvuloplastia transluminal percutánea en diversas cardiopatías congénitas: experiencia en 65 casos. *Rev Esp Cardiol.* 1988;41:223-32.
23. Phadke K, Dyet JF, Aber CP, Hartley W. Balloon angioplasty of adult aortic coarctation. *Br Heart J.* 1993;69:36-40.
24. Patel HT, Madani Y, Paris M, Warner ZM, Hijazi ZM. Balloon angioplasty of native coarctation of the aorta in infants and neonates. Is it worth the hassle? *Pediatr Cardiol.* 2001;22:53-7.
25. Brotons A, Céspedes P, Serrano M, López D, Casaldáliga J, Castellote A, et al. Utilidad de la resonancia nuclear magnética en el diagnóstico de la coartación de aorta y recoartación. *Rev Esp Cardiol.* 1995;48:807-11.
26. de Lezo JS, Sancho M, Pan M, Romero M, Oliveira C, Luque M. Angiographic follow-up after balloon angioplasty for coarctation of the aorta. *J Am Coll Cardiol.* 1989;13:689-95.
27. de Lezo J, Pan M, Romero M, Medina A, Segura J, Lafuente M, et al. Immediate and follow-up findings after stent treatment for severe coarctation of aorta. *Am J Cardiol.* 1999;83:400-6.
28. Alcívar J, Pena N, Onate A, Cabrera A, Galdeano JM, Pastor E, et al. Implantación primaria de *stent* en la coartación de aorta: seguimiento a medio plazo. *Rev Esp Cardiol.* 2000;53:797-804.
29. Hamdan M, Maheshwari S, Fahey JT, Hellenbrand WE. Endovascular stents for coarctation of the aorta: initial results and intermediate-term follow-up. *J Am Coll Cardiol.* 2001;38:1518-23.
30. Huggon IC, Qureshi SA, Baker EJ, Tynan M. Effect of introducing balloon dilatation of native aortic coarctation on overall outcome in infants and children. *Am J Cardiol.* 1994;73:799-807.
31. Rao PS, Chopra PS, Kosciuk R, Smith PA, Wilson AD. Surgical versus balloon therapy for aortic coarctation in infants < or =3 months old. *J Am Coll Cardiol.* 1994;23:1479-83.
32. Walhout RJ, Lekkerkerker JC, Oron GH, Bennink BWE, Meijboom EJ. Comparison of surgical repair with balloon angioplasty for native coarctation in patients from 3 months to 16 years of age. *Eur J Cardiothorac Surg.* 2004;25:722-7.
33. Shaddy RE, Boucek MM, Sturtevant JE, Ruttenberg HD, Jaffe RB, Tani LI Y, et al. Comparison of angioplasty and surgery for unoperated coarctation of the aorta. *Circulation.* 1993;87:793-9.
34. Hernández-González M, Solerio S, Conde-Carmona I, Rangel-Abundis A, Ledesma M, Munayer J, et al. Intraluminal aortoplasty vs surgical aortic resection in congenital aortic coarctation. A clinical study in pediatric patients. *Arch Med Res.* 2003;34:305-10.