

Cardiovascular Magnetic Resonance Evaluation of Left-to-Right Shunts Due to Cardiac Septal Defects in Patients With Pulmonary Arterial Hypertension

Martha A. Hernández-González,^a Nilda Espínola-Zavaleta,^b Sergio Solorio,^a Juan M. Malacara-Hernández,^c Víctor M. Jarquin,^a Verónica Díaz de León,^a and Pedro López-Valenzuela^a

^aUnidad Médica de Alta Especialidad Número 1, Bajío, Instituto Mexicano del Seguro Social, León, Guanajuato, Mexico

^bInstituto Nacional de Cardiología Ignacio Chávez, León, Guanajuato, Mexico

^cInstituto de Investigaciones Médicas, Universidad de Guanajuato, Mexico

Introduction and objectives. As cardiac septal defects are frequently associated with pulmonary arterial hypertension, hemodynamic assessment is essential before deciding on surgery. The aim of this study was to evaluate the use of cardiovascular magnetic resonance imaging for assessing cardiac shunts and for quantifying pulmonary artery systolic pressure in patients with cardiac septal defects.

Methods. This cross-sectional study involved patients with cardiac septal defects and clinically suspected severe pulmonary arterial hypertension who had an indication for cardiac catheterization and in whom magnetic resonance imaging was not contraindicated. Each test's results were evaluated independently by 2 expert radiologists and interventional cardiologists who were blinded to the results of the other test. The procedures were compared using confidence limits and intraclass correlation coefficients.

Results. The study involved 29 patients (18 female and 11 male) aged from 30 days to 18 years; 7 had an atrial septal defect, 14 had a ventricular septal defect, and 8 had an atrioventricular septal defect. The correlation coefficients for measurements made using the 2 procedures were 0.80, 0.75, 0.81, and 0.58 for pulmonary output, systemic output, flow ratio, and systolic pressure in the pulmonary artery, respectively. Cardiovascular magnetic resonance tended to underestimate systemic output by 0.80 L/min, pulmonary output by 1.35 L/min, left-to-right shunt flow by 0.12 L/min, and systolic pressure in the pulmonary artery by 16.5 mm Hg. The complication

rate with cardiac catheterization was 31% compared with 3.4% with cardiovascular magnetic resonance imaging.

Conclusions. The evaluation of patients with cardiac septal defects and pulmonary arterial hypertension should initially be performed using noninvasive diagnostic techniques.

Key words: Hemodynamics. Cardiac catheterization. Magnetic resonance imaging. Congenital heart defects.

Resonancia magnética cardiovascular en la cuantificación de los cortocircuitos de izquierda a derecha en los defectos septales cardíacos con hipertensión arterial pulmonar

Introducción y objetivos. Los defectos septales cardíacos con frecuencia se asocian con hipertensión arterial pulmonar, por lo que es indispensable su evaluación hemodinámica previa a la decisión quirúrgica. Llevamos a cabo un estudio para comparar la cuantificación del cortocircuito y de la presión sistólica de la arteria pulmonar mediante resonancia magnética cardiovascular en pacientes con defectos septales cardíacos.

Métodos. Se diseñó un estudio transversal en pacientes con defectos septales cardíacos y sospecha clínica de hipertensión arterial pulmonar grave, con indicación de cateterismo cardíaco, sin contraindicación de resonancia magnética. La valoración de los resultados de cada prueba fue realizada por dos expertos radiólogos y hemodinamistas, de manera independiente y que desconocían los hallazgos en la otra prueba. La comparación entre los procedimientos se llevó a cabo mediante los límites de concordancia y el coeficiente de correlación intraclase.

Resultados. Se incluyó a 29 pacientes, 18 mujeres y 11 varones, de 30 días a 18 años de edad, 7 con comunicación interauricular, 14 con comunicación interventricular y 8 con canal auriculoventricular completo. La correlación intraclase entre ambos procedimientos fue 0,80; 0,75; 0,81 y 0,58 para el gasto pulmonar, el gasto sistémico, la relación de flujos y la presión sistólica de la arteria pulmonar, respectivamente. La resonancia tiende a subestimar en 0,80 l/min el gasto sistémico, 1,35 l/min el gasto pulmonar, 0,12 l/min el desvío de flujo QP:QS y 16,5 mmHg la presión sistólica de la arteria pulmonar. La

SEE EDITORIAL ON PAGES 895-8

This project was funded in part by the Consejo Nacional de Ciencia y Tecnología of the Guanajuato State (CONCYTEG).

Correspondence: Dr. S.E. Solorio-Meza.
Unidad de Investigación en Epidemiología Clínica. Unidad Médica de Alta Especialidad n.º 1. Bajío. Instituto Mexicano del Seguro Social.
Boulevard Adolfo López Mateos e Insurgentes, s/n. Colonia Los Paraísos.
37320 León. Guanajuato. México.
E-mail: sergio.solorio@imss.gob.mx

Manuscript received November 29, 2006.
Accepted for publication May 4, 2007.

incidencia de complicaciones inherentes al cateterismo fue del 31% y de la resonancia del 3,4%.

Conclusiones. La evaluación de los pacientes con defectos septales cardiacos e hipertensión pulmonar deberá realizarse, en primera instancia, con métodos de diagnóstico no invasivos.

Palabras clave: Hemodinámica. Cateterismo cardíaco. Resonancia magnética. Defectos cardiacos congénitos.

ABBREVIATIONS

CC: cardiac catheterization
MRI: magnetic resonance imaging
PASP: pulmonary artery systolic pressure
PL: pulmonary load
PL:SL: flow ratio
SL: systemic load

INTRODUCTION

Cardiac septal defects, such as intra-atrial shunts, ventricular shunts, and endocardial cushion defects are among the most common presentations in congenital heart disease services.¹

In general terms, clinical diagnosis of cardiac septal defects is confirmed by echocardiography, a method which allows the anatomy of the defect and its hemodynamic repercussions to be accurately defined.^{2,3}

However, in some cases, cardiac catheterization is necessary before any decisions about surgery are taken. The exact indications for catheterization studies are as follows: suspicion of obstructive pulmonary vascular disease, associated cardiac malformations, abnormal visceral, or cardiac situs in endocardial cushion defects, multiple septal defects and, finally, disagreement between clinical signs and symptoms and the clinical diagnosis.^{4,5}

In comparison with echocardiography, cardiovascular magnetic resonance imaging (MRI) has been shown to be useful for providing an anatomical description of congenital cardiac malformations.^{6,7} However, there are few reports in the scientific literature in which the technique of MRI flow mapping is validated to measure cardiac load.

We compared cardiovascular MRI and cardiac catheterization in patients with cardiac septal defects, taking the invasive procedure as the reference method for measuring shunts and pulmonary artery systolic pressure (PASP).

METHODS

Patients

Twenty-nine pediatric patients were studied (18 girls and 11 boys) with ages ranging from 30 days to 18 years (mean [SD], 8 years, 11 months [6 years, 30 days]). In all patients, the cardiac septal defect had been diagnosed clinically and echocardiographically, and cardiac catheterization was indicated due to suspicion of severe pulmonary artery hypertension, visceral heterotaxia, presence of multiple ventricular septal defects, or atrial septal defects in patients who were candidates for an Amplatzer device. Using echocardiography, atrial shunting was diagnosed in 7 patients, complete endocardial cushion defects and pulmonary hypertension in 8, and ventricular septal defect in 14 (3 with subpulmonary ventricular shunts, 4 with multiple septal defects, and 7 with subaortic ventricular shunts and severe pulmonary hypertension).

Patients were excluded if they had associated cardiac or extracardiac lesions, cardiac arrhythmia, definitive pacemakers, implantable cardioverter defibrillators, intracranial ferromagnetic clips, and metallic intraocular foreign bodies.

Before the children were enrolled, consent in writing was obtained from the parents or legal guardians for inclusion, the hemodynamic study, and cardiovascular MRI. The studies were undertaken by experts blinded to the results.

The protocol was approved by the corresponding institutional review board.

Cardiac Catheterization

The invasive study was done in a General Electric Advantx catheterization laboratory (Wisconsin, USA).

Patients were sedated with intravenous midazolam at a dose of 0.5-0.10 mg/kg, 3 to 5 minutes before carrying out the diagnostic study, and ketamine at a dose of 1 mg/kg. Oxygen saturation, systemic blood pressure, heart rate, and respiratory rate were monitored during the procedure.

Right and left catheterization was undertaken in retrograde direction through the femoral artery and vein with selective angiography. The choice of conventional view was made according to the defect in question to provide the best images of the septal defects and cardiac anatomy. Venous and arterial blood samples were taken from all chambers to determine oxygen saturation and data on pulmonary and systemic artery load and the flow ratios were obtained using the Fick method.⁸

Pulmonary artery pressure was recorded directly in the trunk of the pulmonary artery.

All studies were recorded on compact discs.

Cardiovascular Magnetic Resonance Imaging

Magnetic resonance imaging studies were done using a 1.5 T Magnetom Sonata device (Siemens Medical Systems, Erlangen, Germany).

Patients were sedated with intravenous midazolam at a dose of 0.5 to 0.10 mg/kg and intubated for image acquisition with ketamine at a dose of 1 mg/kg. Data acquisition was done over a 9.5 second period while the patients held their breath for at least 2 respiratory cycles in order to improve the sharpness of the image and the accuracy of the flow measurements. During the entire procedure, systemic blood pressure, heart rate, respiratory rate, and oxygen saturation were monitored.

Morphological and functional cine sequences were acquired with a surface coil, using prospective cardiac synchronization under apneic conditions (TrueFISP, T1: 110 ms, TR: 190 ms, flip angle: 49°, matrix: 128×72).

Measurements in cardiac planes along the long and short axis for 2, 3, and 4 chambers were obtained with half-Fourier acquisition single-shot turbo spin-echo (HASTE) in order to provide an initial assessment of the arrangement, morphology, and size of the cardiac structures, their relation with the vascular structures, and the remaining structures of the mediastinum.

The functional information, the main objective of this article, was obtained from short-axis 4-chamber cine gradient-echo sequences from base to tip of outflow tract of both the right and left ventricle and oblique sagittal views of the aorta. With these data, the ventricular volumes and cardiac loads could be calculated (Argus®, Siemens System).

The systolic pressure of the pulmonary artery was inferred by measuring the peak velocity of the tricuspid valve jet, applying the Bernoulli formula ($4v^2$) in a similar fashion to the calculation with echocardiography and in accordance with that reported by other authors,^{9,10} using the 4-chamber and oblique coronal view covering the right atrium and ventricle, at an angle of 30°. In the event that there was no regurgitation, and in absence of pulmonary valve stenosis, systolic pressure was considered to be 10 mm Hg (right atrial pressure).¹⁰

To obtain the systemic load, MRI flow mapping of the ascending aorta was done with angular transversal cuts above the aortic valve. Similar measurements were done in the pulmonary artery to obtain the pulmonary load, in accordance with that described by Powell et al,¹¹ in a single measurement. The range of flow mapping velocities in the pulmonary artery and aorta was from 45 to 210 cm/s, with an angle to flow in the great vessels of 46° to 60°, and an approximate error of 4% to 12%.

The studies were recorded on compact disc for subsequent assessment by 2 expert radiologists who were unaware of the findings of the cardiac catheterization study.

Intraobserver and Interobserver Variability of Magnetic Resonance Imaging

In order to calculate interobserver variability, 15 patients with cardiac septal defects who did not form part of the series were included. In all these patients, an MRI study

was recorded on compact disc for subsequent independent evaluation by 2 experts who were unaware of the findings of the other study.

For the intraobserver variability, each hemodynamic variable was measured on 2 separate occasions with 1 week between measurements. This variability was obtained for each of the observers.

To calculate the interobserver variability, we took the average of the 2 measurements of each expert.

The results were expressed as percentages.

The intraobserver variability for quantifying the systemic load, the pulmonary load, and PASP, was 4.8% (95% confidence interval [CI], 3.71-5.81), 5.6% (95% CI, 4.54-6.65), and 5.3% (95% CI, 4.03-6.57), respectively. The interobserver variability was 8.9% (95% CI, 7.44-10.36), 10.2% (95% CI, 8.16-12.24), and 7.2% (95% CI, 5.85-8.55), respectively.

Statistical Analysis

The SPSS, version 11.0 and MedCalc version 9.2 statistical packages were used. The continuous quantitative variables were expressed as mean (SD) (or median and ranges for non-normal distributions). Categorical variables were presented as frequencies. Comparison between the 2 diagnostic methods for quantifying pulmonary load, systemic load, flow ratios, and systolic pressure of the pulmonary artery was done using the Bland-Altman analysis.¹² The intraclass correlation coefficient of these variables with their corresponding confidence intervals was also calculated.

RESULTS

The general characteristics of the patients are presented in Table 1.

Agreement Between Cardiovascular Magnetic Resonance Imaging and Diagnostic Catheterization

In the Bland-Altman analysis, both methods showed acceptable agreement in the assessment of pulmonary load, systemic load, and flow ratios, in accordance with the confidence intervals; the mean differences were very small and the dispersion plot showed points grouped around the mean, with few outlying values (Figure 1A-C).

It is worth noting that 1 of the patients had high values of pulmonary load (approximately 40 L/min with catheterization and 18 L/min with MRI). We think that this was due to a highly dilated right ventricle, almost without hypertrophy, secondary to volume overload due to an extensive subaortic ventricular septal defect, with no pulmonary valve stenosis, and the fact that the blood sample was taken from close to the septal defect. As a result, for calculation of PASP, the dispersion plot was

TABLE 1. Clinical and Hemodynamic Characteristic of the Patients With Cardiac Septal Defects*

Number	Type of Defect	Age, Months	Body Area, m ²	SL, L/min		PL, L/min		PASP, mm Hg	
				MRI	CC	MRI	CC	MRI	CC
1	Subpulmonary VS	158	1.35	10.29	10.19	5.4	5.3	22	98
2	AS	24	0.51	4.23	4.27	3.12	2.57	10	35
3	Endocardial cushion defects	122	1.13	3.9	5.14	6.3	3.58	90	28
4	Subaortic VS	195	1.28	4.8	13.48	3.92	5.22	10	60
5	Subaortic VS	12	0.31	2.1	1.12	1.1	1.88	10	60
6	Multiple VS	61	0.79	2.8	5.7	5.4	2.5	90	80
7	AS	36	0.51	0.6	1.3	1.2	1.2	10	23
8	Endocardial cushion defects	158	1.64	—	4.43	—	18.6	10	25
9	Subpulmonary VS	122	0.84	13.18	14.96	14.23	19.94	10	22
10	Subaortic VS	109	1.1	6.87	5.37	18.23	40.94	10	60
11	Endocardial cushion defects	6	0.28	1.39	1.8	1	1.8	44	44
12	AS	12	0.21	1.8	2.74	1.35	1.21	10	11
13	Subaortic VS	6	0.32	2.8	3.9	0.83	0.73	70	80
14	Endocardial cushion defects	12	0.41	1.2	1.26	—	1.4	10	48
15	Multiple VS	134	0.91	—	3.28	—	3.14	63	65
16	Endocardial cushion defects	73	0.63	4.19	1.27	1.17	1.27	77	77
17	Subpulmonary VS	194	1.49	9.29	2.87	13.2	13.26	20	55
18	Endocardial cushion defects	24	0.5	2	1.93	1.5	3.09	58	75
19	Multiple VS	121	1.42	2.46	1.36	2.1	2.16	72	105
20	AS	85	0.73	1.93	4.36	3.17	3.18	10	17
21	Endocardial cushion defects	24	0.38	1.75	2.35	1.69	8.02	64	65
22	Endocardial cushion defects	219	1.4	3.13	4.25	—	4.74	10	32
23	AS	49	0.6	1.83	5.78	—	8.26	10	30
24	Subaortic VS	36	0.64	1.03	4.44	3.8	3.17	10	73
25	Subaortic VS	122	1.41	2.8	3.45	3.79	2.01	90	81
26	Multiple VS	37	0.57	1.4	4.01	2.3	3.7	74	70
27	AS	219	1.56	—	2.75	—	6.49	38	36
28	VS	12	0.36	1.39	1.59	7.07	4.84	81	85
29	AS	219	1.4	3.13	4.25	—	4.74	10	32

*CC indicates cardiac catheterization; AS, atrial shunt; VS, ventricular shunt; PASP, pulmonary artery systolic pressure; PL, pulmonary load; SL, systemic load; MRI, magnetic resonance imaging.

more erratic and, therefore, showed lower agreement (Figure 2).

On analyzing the mean differences (Table 2), we can affirm that MRI tends to overestimate hemodynamic values obtained from catheterization by 0.80 L/min for quantification of systemic load, 1.35 L/min for pulmonary load, 0.12 L/min for flow ratios, and 16.5 mm Hg for PASP.

In the same Table we can see that, in accordance with the values of the intraclass correlation coefficient and its

respective confidence intervals, MRI was a good procedure for quantifying cardiac loads but not PASP, where the coefficient was 0.58 with very broad confidence intervals.

Complications

Complications occurred in 10 patients, representing 34.5% of the cases: 9 were related to the invasive procedure and only 1 attributable to MRI.

TABLE 2. Agreement Between Cardiovascular Magnetic Resonance Imaging and Diagnostic Catheterization for Quantifying Shunting*

Variable	No. of Patients	Mean (SD) Difference	Limits of Agreement		ICC (95% CI)
			MD – 2SD (95% CI)	MD + 2SD (95% CI)	
SL	29	–0.80 (2.62)	–5.94 (–7.78 to –4.11)	4.33 (2.50–6.17)	0.80 (0.58–0.91)
PL	29	–1.35 (5.25)	–11.65 (–15.70 to –7.61)	8.95 (4.90–13.00)	0.75 (0.48–0.88)
PL:SL	29	–0.12 (1.73)	–3.52 (–4.86 to –2.19)	3.28 (1.94–4.61)	0.81 (0.61–0.91)
PASP	29	–16.51 (26.81)	–69.06 (–86.69 to –51.43)	36.03 (18.39–53.66)	0.58 (0.12–0.80)

*ICC indicates intraclass correlation coefficient; CI, confidence interval; MD, mean difference; PASP, pulmonary artery systolic pressure; PL, pulmonary load; PL:SL, flow ratio; SL, systemic load.

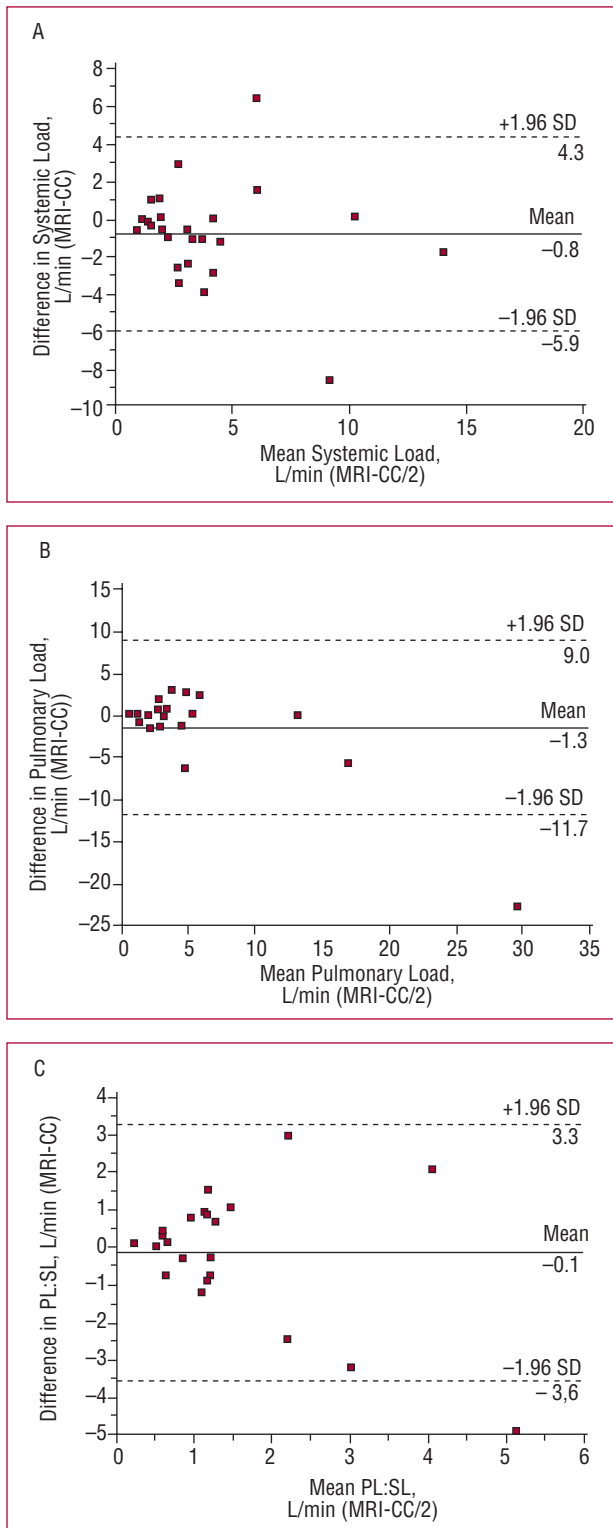


Figure 1. Agreement between magnetic resonance imaging (MRI) and cardiac catheterization (CC) according to Bland-Altman analysis. PL indicates pulmonary load; SL, systemic load.

With regard to catheterization, 3 patients needed blood transfusion within 24 hours of the procedure, 2 cases presented hematoma that did not require surgical

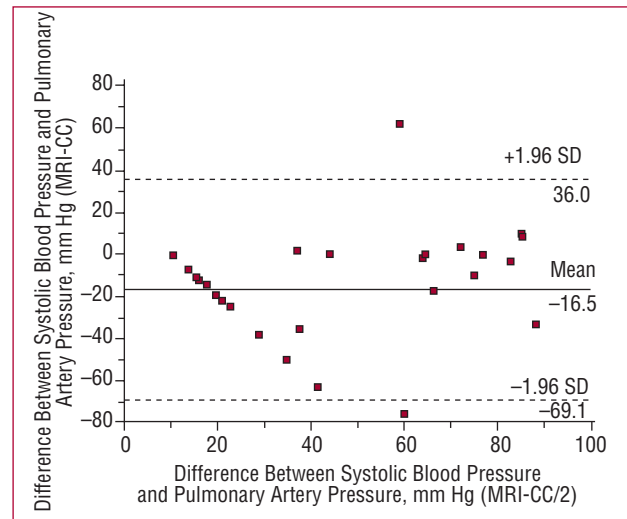


Figure 2. Bland-Altman analysis for systolic pressure of the pulmonary artery. CC indicates cardiac catheterization; MRI, magnetic resonance imaging.

intervention, 2 had severe desaturation that required mechanical ventilation support for not longer than 24 hours, 1 suffered mild dehydration and responded favorably to administration of intravenous fluids, and 1 had left femoral artery obstruction that improved 24 hours after heparin administration and local heat, without sequelae.

In the MRI, only 1 patient had a feeling of numbness in the tongue, which resolved spontaneously.

No deaths related to the diagnostic techniques were reported.

Duration of the Procedure

The average duration of cardiac catheterization was 30 minutes (median, 80 minutes; range, 30-190 minutes), whereas the MRI lasted a median of 38 minutes (range, 31-69 minutes).

The delay between one procedure and the other was, on average, 8 days (minimum 24 h, maximum 30 days).

DISCUSSION

Recently, new noninvasive cardiovascular imaging techniques, such as MRI, have become available. With these techniques, it is possible to visualize cardiac and extracardiac anatomic features in congenital heart disease.¹³

The usefulness of MRI for flow mapping has also been described—with an acceptable correlation with the findings of invasive oximetry—for quantification of the ratio of pulmonary load to systemic load and in atrial septal defects without pulmonary artery hypertension.^{14,15}

We show that the method correlates with cardiac catheterization in quantifying the size of cardiac shunting

and in cases of pulmonary artery hypertension associated with atrial, ventricular, or canal atrioventricular shunting. The intraclass correlation was greater than 0.7 for pulmonary load, systemic load, and the flow ratios. The reliability of the method is supported by the fact that the confidence intervals did not include 1.¹⁶ These findings were similar to those reported by other authors.^{17,18}

Although our results show that this noninvasive method tends to overestimate the quantification of systemic load by 21%, pulmonary load by 9.8%, and the flow ratio by 6.7%, as in 2-dimensional echocardiographic studies,¹⁹ variations of less than 30% can be considered acceptable.²⁰ While it is true that the size of the shunts in our case series was not very large, this may be explained by the fact that patients had severe pulmonary artery hypertension.

With regard to PASP, this error was greater still—16.5 mm Hg on average compared to cardiac catheterization, that is, an overestimation of 55.1%. This is clinically relevant, given that it might distinguish between a patient with moderate hypertension and 1 with severe pulmonary hypertension, that is, with interventions associated with high mortality rates and not susceptible to surgery. This underestimation might be explained by the way in which the PASP was inferred (considering the maximum velocity of the tricuspid jet). Thus the phenomenon of partial volume means that red blood cells traveling at different velocities coincide in the same voxel. This in turn would give rise to an underestimation of the results. In addition, the eccentricity of the tricuspid regurgitation jet would influence the errors in the measurement. In the scientific literature, there have been reports that the mean pressure in the pulmonary artery can be determined by measurement of the ventricular mass index, that is, the ratio of right ventricular mass to left ventricular mass, with a correlation with cardiac catheterization of 0.81.²¹

It has been postulated that the calculation of cardiac loads and ventricular volumes with the Argus MRI system is independent of the operator, although there is intraobserver and interobserver variability; our findings point to the reproducibility of the method and the internal validity of the procedure. In any case, variability is less than with echocardiography, for which interobserver variabilities of up to 15% have been reported.²²

In view of our findings, we can infer that both methods can be used indistinctly to calculate these hemodynamic variables.

On the other hand, MRI can precisely identify the size, site, and presence of multiple septal defects, extracardiac anomalies, and even the lack of spleen or polysplenia in cases of visceral heterotaxia, particularly in complete endocardial cushion defects.²³

Finally, the biggest advantage of the method is the low risk of complications—in our series, 3.4% had complications during MRI compared to 31% with cardiac catheterization.

Limitations of the Study

The type and site of the septal defect was not corroborated by surgical findings, mainly because that was not our primary objective.

The time lag between carrying out one procedure or another was up to 1 month, during which time the findings could have changed in view of progression towards maturation of the lungs and pulmonary hypertension. Furthermore, the use of anesthesia during the cardiac catheterization procedure in itself decreases the values of pulmonary artery pressure.

Another limitation is the sample size. However, we calculated the statistical power in support of our conclusions: this was 92% for the correlation with PASP, which is the hemodynamic variable with lowest correlation and agreement with mean (SD) values of 54.21 [25.77] mm Hg by catheterization and of 37.60 mm Hg by MRI, for a level of confidence of 95% and a 2-tailed analysis.

CONCLUSIONS

According to our findings, we can conclude that evaluation of the patients with intracardiac septal defects and pulmonary artery hypertension should be done in the first instance with noninvasive methods. The results of these methods (electrocardiograms, chest radiographs, echocardiograms, and MRI scans) are complementary. Cardiac catheterization should be reserved only for very special cases in which diagnostic uncertainty persists and surgery is indicated.

With the use of this imaging technique, we would reduce cardiac catheterization by 25% in patients with septal defects, by 19.2% in those with suspicion of extracardiac malformation, and by 7% in those with multiple septal defects. Cardiac catheterization in patients with endocardial cushion defects to rule out visceral heterotaxy would also be reduced by half.

The surgical approach may also be modified when there are associated malformations, according to an accurate diagnosis. For example, septal defect and patent ductus arteriosus, or aortic coarctation could be corrected in a single thoracotomy procedure. It would even help to make decisions when pulmonary artery hypertension is severe and irreversible and surgical correction of the defect is not indicated.

REFERENCES

1. Sistema Nacional de Información en Salud de México. Principales causas de mortalidad infantil (menores de un año), 2005 [accessed Mar, 15 2007]. Available from: http://sinais.salud.gob.mx/mortalidad/tabs/m_006.xls
2. Ludomirsky A, Huhta JC, Vick GW, Murphy DJ Jr, Danford DA, Morrow WR. Color Doppler detection of multiple ventricular septal defects. *Circulation*. 1986;74:1317-22.
3. Fellows KE, Westerman R, Keane JF. Angiocardiography of multiple ventricular septal defects in infancy. *Circulation*. 1982; 66:1094-9.

4. Bierman FZ, Williams RG. Subxiphoid two-dimensional imaging of the interatrial septum in infants and neonates with congenital heart disease. *Circulation*. 1979;60:80-90.
5. Magee A, Coutin Ch, McCrindle B, Smallhorn J. Echocardiography and cardiac catheterization in the preoperative assessment of ventricular septal defect in infancy. *Am Heart J*. 1998;135:907-13.
6. de Roos A, Roest AA. Evaluation of congenital heart disease by magnetic resonance imaging. *Eur Radiol*. 2000;10:2-6.
7. Meave A, Hernández-González M, Alexanderson E, Vázquez C, Ermenger J, Solorio S, et al. Diagnosis of complex congenital heart disease through magnetic resonance. *Arch Cardiol Mex*. 2005;75:435-40.
8. Wilkinson JL. Congenital heart disease. Haemodynamic calculations in the catheter laboratory. *Heart*. 2001;85:113-20.
9. Berger M, Haimowitz A, van Tosh A, Berdoff RL, Goldberg E. Quantitative assessment of pulmonary hypertension in patients with tricuspid regurgitation using continuous wave Doppler ultrasound. *J Am Coll Cardiol*. 1985;6:359-65.
10. Kayser HV, Stoel BC, van der Wall EE, van der Gest, Roos A. MR velocity mapping of tricusid floor: correction fr through-plane motion. *J Mag Reson Imaging*. 1997;7:669-73.
11. Powell AJ, Maier SE, Chung T, Gea T. Phase-velocity cine magnetic resonance imaging measurement of pulsatile blood flow in children and young adults: in vitro and in vivo validation. *Pediatr Cardiol*. 2000;21:104-10.
12. Bland JM, Altman DG. Statistical methods for assessing agreement between two methods of clinical measurement. *Lancet*. 1986;1:307-10.
13. Sahn DJ, Vick III GW. Review of new techniques in echocardiography and magnetic resonance imaging as applied to patients with congenital heart disease. *Heart*. 2001;86:ii41-ii53.
14. Beerbaum P, Körperich H, Barth P, Esdorn H, Gieseke J, Meyer H. Noninvasive quantification of left-to-right shunt in pediatric patients phase-contrast cine magnetic resonance imaging compared UIT invasive oximetry. *Circulation*. 2001;103:2476-82.
15. Esmaeili A, Hohn R, Koch A, Vogl TJ, Hofstetter R, Abolmaali N. Assessment of shunt volumes in children with ventricular septal defects: comparative quantification of MR flow measurements ad invasive oximetry. *Clin Res Cardiol*. 2006;95:523-30.
16. McGraw KO, Wong SP. Forming inferences about some intraclass correlation coefficients. *Psychol Methods*. 1996;1:30-46.
17. Beerbaum P, Körperich H, Gieseke J, Barth P, Peuster M, Meyer H. Rapid left-to-right shunt quantification in children by Phase-contrast Magnetic Resonance Imaging combined with Sensitivity Encoding (SENSE). *Circulation*. 2003;108:1355-61.
18. Körperich H, Gieseke J, Barth P, Hoogeveen R, Esdorn H, Peterschröder A, et al. Flow volume and shunt quantification in pediatric congenital heart disease by real-time magnetic resonance velocity mapping: a validation study. *Circulation*. 2004;109:1987-93.
19. Stevenson JG, Kawabori I, Dooley T, Guntheroth WG. Diagnosis of ventricular septal defect by pulsed Doppler echocardiography. Sensitivity, specificity and limitations. *Circulation*. 1978;58:322-6.
20. Critchley LAH, Critchley JAJH. A meta-analysis of studies using bias and precision statistics to compare cardiac output measurement techniques. *J Clin Monit*. 1999;15:85-91.
21. Saba TS, Foster J, Cockburn M, Cowan M, Peacock AJ. Ventricular mass index using magnetic resonance imaging accurately estimates pulmonary artery pressure. *Eur Respir J*. 2002;20:1519-24.
22. Boehrer JD, Lange RA, Willard JE, Grayburn PA, Hillis LD. Advantages and limitations of methods to detect, localize, and quantitative intracardiac left-to-right shunting. *Am J Heart*. 1992;124:448-55.
23. Yong Kook Hong, Young Whan Park, Sok Jong Ryu, Je Whan Won, Jae Young Choi, Jun Hee Sul, et al. Efficacy of MRI in Complicated Congenital Heart Disease with Visceral Heterotaxy Syndrome. *J Comput Assist Tomogr*. 2000;24:671-82.