

Image in cardiology

Characterization of a Mediastinal Thymic Seminoma Using Cardiac Magnetic Resonance

Seminoma tímico mediastínico caracterizado mediante resonancia magnética cardiaca

Leticia Fernández-Friera,^{a,b,c} Valentín Fuster,^{a,c} and Javier Sanz^{a,*}

^aThe Zena and Michael A. Wiener Cardiovascular Institute, and Marie-Josée and Henry R. Kravis Center for Cardiovascular Health, Mount Sinai School of Medicine, New York, United States

^bDepartamento de Cardiología, Hospital Universitario Marqués de Valdecilla-Instituto de Formación e Investigación Marqués de Valdecilla (IFIMAV), Santander, Spain

^cFundación Centro Nacional de Investigaciones Cardiovasculares Carlos III (CNIC), Madrid, Spain

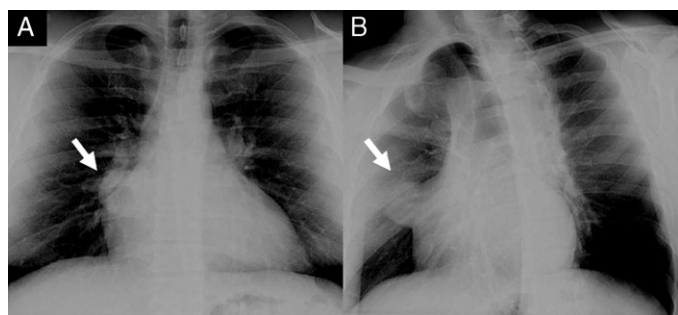


Figure 1.

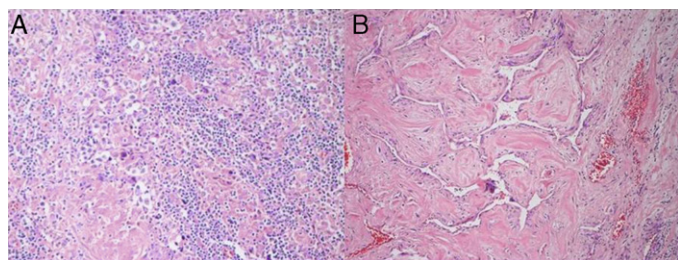


Figure 3.

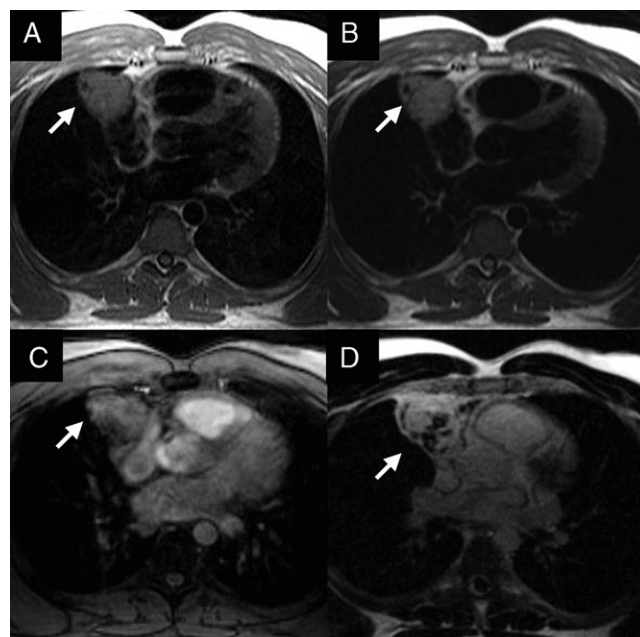


Figure 2.

A 34-year-old man was referred for evaluation of a mediastinal mass, detected on routine chest radiography (Figs. 1A and 1B). His past medical history, physical examination, and laboratory tests were unremarkable. Cardiac magnetic resonance confirmed a well circumscribed mass in the anterior mediastinum, measuring $6 \times 5 \times 5$ cm. It started at the level of the pulmonary artery bifurcation and extended laterally to the right atrium, without evidence of infiltration of surrounding tissues. In comparison with the myocardium, the mass was isointense on T1-weighted imaging (Fig. 2A) and hyperintense on T2 sequences (Fig. 2B), findings compatible with high fluid content. On the other hand, first-pass images showed hyperperfusion within the mass (Fig. 2C) and diffuse delayed enhancement (Fig. 2D), suggesting a highly vascular component with increased interstitial space. The patient underwent surgical mass resection. Histological specimens showed a central component of large polygonal cells with clear cytoplasm and central nuclei with prominent nucleoli (Figs. 3A and 3B). This morphologic finding together with immunohistochemical staining that was positive for placental alkaline phosphatase and negative for alpha-fetoprotein and human chorionic gonadotropin were consistent with thymic seminoma. Germ-cell tumors are the most common cancer in men between the ages of 15 and 35 years. The anterior mediastinum is the most common primary extragonadal site for seminoma. Because of its favorable prognosis, these variants should not be confused with other mediastinal tumors. A cardiac magnetic resonance provides a comprehensive characterization of this tumor, and should be considered when a mediastinal mass is discovered in a young male.

FUNDING

This study was funded in part by the *Sociedad Española de Cardiología* and the *Instituto de Formación e Investigación "Marqués de Valdecilla"* (IFIMAV) in Santander, Spain.

* Corresponding author:

E-mail address: Javier.Sanz@mssm.edu (J. Sanz).

Available online 11 June 2011