

## Chest Pain With an Elevated Troponin Level but Without Significant Coronary Artery Disease Is Not Usually Due to an Infarction

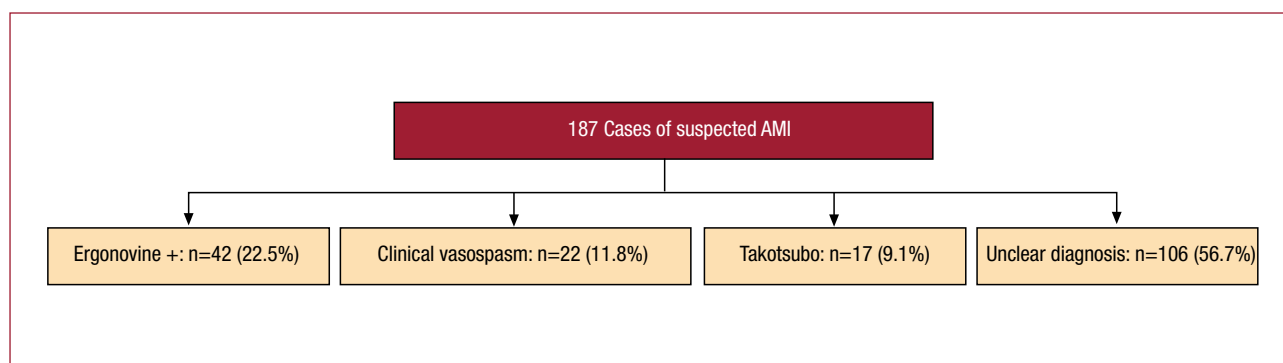
### To the Editor,

We have read with great interest the article by Cortell et al<sup>1</sup> in which the authors analyze the data of 64 patients with a presumed non-ST elevation acute myocardial infarction (NSTEMI) with coronary arteries with no significant lesions. These authors find certain predictors of normal coronary arteries for patients with NSTEMI which are highly coincident with the CPU-65 index (comorbid diabetes, typical pain, use of aspirin and age 65 years or more) that we described 5 years ago after analyzing

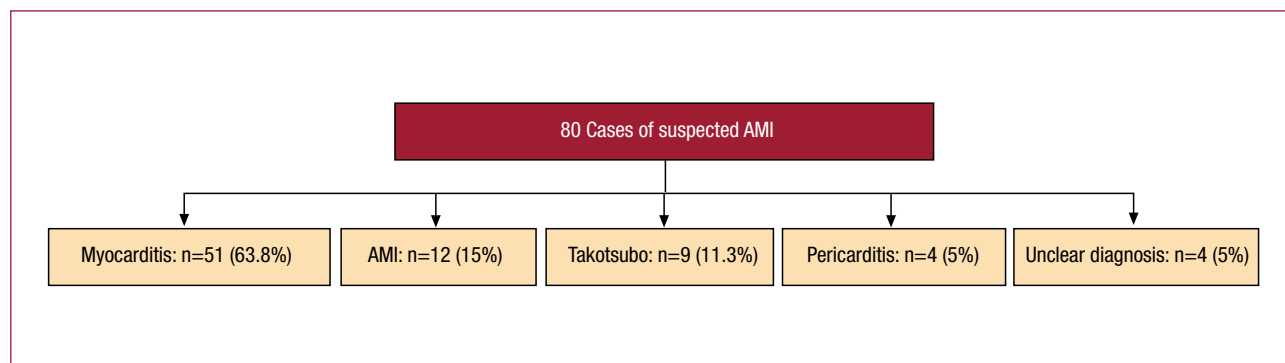
the data from the chest pain unit of our center.<sup>2</sup> A CPU-65 index equal to zero makes it possible to rule out the presence of coronary artery disease, with a negative predictive value of 99.9%<sup>3</sup> and, even in the case of patients with a positive ischemia test, 80% have normal coronary arteries.<sup>4</sup> However, we are surprised that the authors do not include the characteristics of the pain as predictors of a lesion-free coronary angiography. In our series, typical chest pain doubled the probability of significant coronary artery disease and, as a result, sex was no longer an independent predictor. We would like to know if the opposite occurred in the series of Cortell et al or whether the pain characteristics simply were not recorded.

On the other hand, we are not sure that all the patients in the series of Cortell et al. Had had an acute myocardial infarction (AMI) and we are also surprised by the fact that the authors provide no data on the incidence of coronary vasospasm. Recently, we published the data of the VIRIATO (Vasospasm Incidence Registered After Investigation with Angiography and Tested Objectively with Ergonovine) registry, which included 346 consecutive patients from our center with suspected acute coronary syndrome and coronary arteries with no significant lesions.<sup>5</sup> If we focus on the 187 patients with elevated troponin T levels, the majority without ST elevation, at least 9% of patients did not have an AMI, but takotsubo stress cardiomyopathy<sup>6</sup> (Figure 1). The new studies with cardiac magnetic resonance seem to demonstrate that most of the patients with suspected AMI but no significant coronary artery lesions, in reality, have myocarditis.<sup>7-9</sup> The series of Laradugoitia Zaldumbide et al,<sup>7</sup> with a clear predominance of patients without ST elevation, is particularly demonstrative in this respect (Figure 2).

We consider the data of Cortell et al to be very interesting as they help to identify patients with



**Figure 1.** Final diagnosis in the 187 patients of the VIRIATO (Vasospasm Incidence Registered after Investigation with Angiography and Tested Objectively with Ergonovine) registry with elevated troponin T concentrations.<sup>5,6</sup> Unclear diagnosis: diagnosis not clarified at the time of hospital discharge; ergonovine +: positive spasm provocation test with methylegonovine; AMI indicates acute myocardial infarction; takotsubo, takotsubo stress cardiomyopathy; clinical vasospasm, highly typical event that was ultimately treated with calcium channel blockers.



**Figure 2.** Final diagnosis in the 80 patients of the series of Laraudogoitia Zaldumbide et al.<sup>7</sup> AMI indicates acute myocardial infarction; takotsubo, takotsubo stress cardiomyopathy; unclear diagnosis, diagnosis not clarified at the time of hospital discharge

suspected NSTEMI whose coronary arteries show no significant lesion, but we think that the absence of these lesions should lead us to reconsider the initial diagnosis in many patients.

Manuel Martínez-Sellés, Tomás Datino, Álvaro Estévez,  
and Francisco Fernández Avilés  
Servicio de Cardiología, Hospital General Universitario Gregorio Marañón,  
Madrid, Spain

## REFERENCES

1. Cortell A, Sanchis J, Bodí V, Núñez J, Mainar L, Pellicer M, et al. Infarto de miocardio sin elevación del ST con coronarias normales: predictores y pronóstico. *Rev Esp Cardiol.* 2009;62:1260-6.
2. Martínez-Sellés M, Ortiz J, Estévez A, Andueza J, De Miguel J, Bueno H. Un nuevo índice de riesgo para pacientes con ECG normal o no diagnóstico ingresados en la unidad de dolor torácico. *Rev Esp Cardiol.* 2005;58:782-8.
3. Martínez-Sellés M, Bueno H, Sacristán A, Estévez A, Ortiz J, Gallego L, et al. Dolor torácico en urgencias: frecuencia, perfil clínico y estratificación de riesgo. *Rev Esp Cardiol.* 2008;61:953-9.
4. Martínez-Sellés M, Bueno H, Estévez A, De Miguel J, Muñoz J, Fernández-Avilés F. Positive non-invasive tests in the chest pain unit: importance of the clinical profile for estimating the probability of coronary artery disease. *Acute Card Care.* 2008;10:205-8.
5. Martínez-Sellés M, Datino T, Pello AM, Avilés FF. Predictors of coronary spasm in patients with chest pain and no significant coronary stenosis. *Int J Cardiol.* 2009 Jan 8 [Epub ahead of print].
6. Martínez-Sellés M, Datino T, Pello AM, Fernández-Avilés F. Ergonovine provocative test in Caucasian patients with left ventricular apical ballooning syndrome. *Int J Cardiol.* 2009 Jun 10 [Epub ahead of print].
7. Laraudogoitia Zaldumbide E, Pérez-David E, Larena JA, Velasco del Castillo S, Rumoroso Cuevas JR, Onaindia JJ, et al. Utilidad de la resonancia magnética cardíaca en el diagnóstico de los pacientes con síndrome coronario agudo y coronarias normales. *Rev Esp Cardiol.* 2009;62:976-83.
8. Assomull RG, Lyne JC, Keenan N, Gulati A, Bunce NH, Davies SW, et al. The role of cardiovascular magnetic resonance in patients presenting with chest pain, raised troponin, and unobstructed coronary arteries. *Eur Heart J.* 2007;28:1242-9.

9. Baccouche H, Mahrholdt H, Meinhardt G, Mehrer R, Voehringer M, Hills S, et al. Diagnostic synergy of noninvasive cardiovascular magnetic resonance and invasive endomyocardial biopsy in troponine-positive patients without coronary artery disease. *Eur Heart J.* 2009;30:2869-79.

## Response

### To the Editor,

We appreciate the interest shown by Martínez Sellés et al in our article dealing with acute myocardial infarction without ST segment elevation and coronary arteries with no significant stenoses.<sup>1</sup> In the first part of their letter, they express their surprise to the fact that we did not include the characteristics of the chest pain as predictors and refer to a predictive clinical model described by their group.<sup>2</sup> Several studies of our group have analyzed the prognostic value of the clinical data in patients who come to the emergency department with chest pain.<sup>3-6</sup> However, both these studies and those of Martínez Sellés et al have been carried out in patients with chest pain of uncertain origin and normal troponin T levels, and their objective was to optimize the clinical history to aid in making the difficult decision as to whether to admit or discharge the patient. This scenario is very different from that of the patients dealt with in our article, all of whom were admitted to the hospital with elevated troponin levels. Thus, the clinical models designed for populations with normal troponin T levels are not applicable to patients with elevated troponin. On the other hand, the index described by Martínez Sellés et al can not be considered a predictor of normal coronary arteries since coronary angiography was not performed in their study.

The introduction of troponins has revolutionized the diagnosis of myocardial infarction to such an

extent that two consensus documents have been published on its definition.<sup>7,8</sup> Still, as demonstrated by Laraudogoitia Zaldumbide et al,<sup>9</sup> cardiac magnetic resonance can identify diagnoses other than infarction in patients with elevated troponin levels. This, however, does not imply that it can be generalized to the extent to state that chest pain with troponin elevation and coronary arteries without significant lesions “is not usually an infarction.” In fact, we think this has not been the case in the majority of the patients in our series for the following reasons; *a)* all the patients had suggestive chest pain and the diagnosis of infarction was established by a cardiologist on the basis of the in-hospital study; *b)* no patient had ST segment elevation indicative of acute pericarditis; *c)* the troponin T level showed a pattern of elevation and reduction, as indicated in the document defining infarction; *d)* although coronary angiography did not detect significant stenoses, this fact does not imply the absence of arteriosclerosis; and *e)* the incidence of coronary arteries with no significant stenoses (13%) coincides with that reported in other larger series.<sup>10</sup> We have not recorded the incidence of possible coronary spasm, nor was the ergonovine test performed; thus, some patients may have had coronary spasm, but this would support the diagnosis of myocardial infarction and could be one of the mechanisms.

Sensitive troponins will reach our hospitals in the near future and will increase the number of diagnoses of infarction. We are convinced that this will generate a debate that will result in a new consensus document for the redefinition of infarction. In this respect, the letter of Martínez Sellés et al is very timely. However, according to the criteria currently accepted by the scientific societies, we suggest a modulation of their message, since “suggestive chest pain and increased troponin levels is usually a myocardial infarction.”

Juan Sanchis, Alejandro Cortell, and Ángel Llácer  
Servicio de Cardiología, Hospital Clínico Universitario,  
Departamento de Medicina, Universidad de Valencia,  
Valencia, Spain

## REFERENCES

1. Cortell A, Sanchis J, Bodí V, Núñez J, Mainar L, Pellicer M, et al. Infarto de miocardio sin elevación del ST con coronarias normales: predictores y pronóstico. *Rev Esp Cardiol.* 2009;62:1260-6.
2. Martínez-Sellés M, Ortiz J, Estévez A, Andueza J, de Miguel J, Bueno H. Un nuevo índice de riesgo para pacientes con ECG normal o no diagnóstico ingresados en la unidad de dolor torácico. *Rev Esp Cardiol.* 2005;58:782-8.
3. Sanchis J, Bodí V, Llácer A, Núñez J, Consuegra L, Bosch MJ, et al. Risk stratification of patients with acute chest pain and normal troponin levels. *Heart.* 2005;91:1013-8.
4. Sanchis J, Bodí V, Núñez J, Bertomeu-González V, Gómez C, Bosch MJ, et al. New risk score for patients with acute chest pain, non-ST-segment deviation and normal troponin concentrations. A comparison with the TIMI risk score. *J Am Coll Cardiol.* 2005;46:443-9.
5. Sanchis J, Bodí V, Núñez J, Bosch MJ, Bertomeu-González V, Consuegra L, et al. A practical approach with outcome for the prognostic assessment of non-ST-segment elevation chest pain and normal troponin. *Am J Cardiol.* 2007;99:797-801.
6. Sanchis J, Bodí V, Núñez J, Bosch X, Loma-Osorio P, Mainar L, et al. Limitations of clinical history for evaluation of patients with acute chest pain, non-diagnostic electrocardiogram and normal troponin. *Am J Cardiol.* 2008;101:613-7.
7. The Joint European Society of Cardiology/American Collage of Cardiology Committee. Myocardial infarction redefined. A consensus document of the joint European Society of Cardiology/American Collage of Cardiology Committee for the redefinition of myocardial infarction. *Eur Heart J.* 2000;21:1502-13.
8. Thygesen K, Alpert JS, White HD on behalf of the Joint ESC/ACCF/AHA/WHF Task Force for the Redefinition of Myocardial Infarction. Universal definition of myocardial infarction. *Eur Heart J.* 2007;28:2525-38.
9. Laraudogoitia Zaldumbide E, Pérez-David E, Larena JA, Velasco del Castillo S, Rumoroso Cuevas JR, Onaindía JJ, et al. Utilidad de la resonancia magnética cardiaca en el diagnóstico de los pacientes con síndrome coronario agudo y coronarias normales. *Rev Esp Cardiol.* 2009;62:976-83.
10. Roe MT, Harrington RA, Prosper DM, Pieper KS, Bhatt DL, Lincoff AM, et al. Clinical and therapeutic profile of patients presenting with acute coronary syndromes who do not have significant coronary artery disease. *Circulation.* 2000;102:1101-6.