

# Closure of Perivalvular Leaks Using an Amplatzer Occluder

Juan H. Alonso-Briales,<sup>a</sup> Antonio J. Muñoz-García,<sup>a</sup> Manuel F. Jiménez-Navarro,<sup>a</sup> Antonio J. Domínguez-Franco,<sup>a</sup> José M. Melero-Tejedor,<sup>b</sup> Isabel Rodríguez-Bailón,<sup>a</sup> José M. Hernández-García,<sup>a</sup> and Eduardo de Teresa-Galván<sup>a</sup>

<sup>a</sup>Servicio de Cardiología, Hospital Clínico Universitario Virgen de la Victoria, Málaga, Spain

<sup>b</sup>Servicio de Cirugía Cardíaca, Hospital Clínico Universitario Virgen de la Victoria, Málaga, Spain

Reoperation of patients with perivalvular leaks due to heart failure or hemolysis is associated with increased morbidity and mortality. Percutaneous closure using an Amplatzer device offers a promising alternative. We describe our initial experience between 2004 and 2006, during which we used an Amplatzer device in 8 patients for the percutaneous closure of perivalvular leaks (4 aortic and 4 mitral). The patients were all symptomatic and had a high surgical risk. Device placement was successful in all patients with mitral leaks and in 3 with aortic leaks. There were no periprocedural complications. With 4 of the 7 (57%) device placements, there was a significant reduction in the degree of regurgitation and, at 12-month follow-up, only these 4 patients showed clinical improvements. Of the other 3, 1 required reoperation and 2 died of non-cardiovascular causes. Percutaneous closure of perivalvular leaks was feasible and safe and can be regarded as a treatment option in patients with a high surgical risk.

**Key words:** Valvular prosthesis. Perivalvular leak. Percutaneous closure.

## Utilización de los dispositivos Amplatzer para el cierre de fugas perivalvulares

La reintervención de los pacientes con fugas perivalvulares por insuficiencia cardíaca o hemólisis está asociada a una elevada morbimortalidad. La utilización percutánea de los dispositivos Amplatzer supone una alternativa atractiva.

Presentamos nuestra experiencia inicial: entre 2004 y 2006 realizamos cierre percutáneo con dispositivo Amplatzer a 8 pacientes con fugas perivalvulares (4 aórticas y 4 mitrales), sintomáticos y con alto riesgo quirúrgico. La implantación del dispositivo fue posible en todas las mitrales y en 3 aórticas. No hubo complicaciones durante el procedimiento. En 4 (57%) de los 7 implantes se logró una reducción significativa del grado de regurgitación y, tras 12 meses de seguimiento, solamente estos pacientes mejoraron clínicamente. De los 3 restantes, 1 paciente precisó reintervención y 2 fallecieron por causa no cardiovascular.

El tratamiento percutáneo de las fugas perivalvulares es factible y seguro y puede considerarse como una opción terapéutica en subgrupos de alto riesgo quirúrgico.

**Palabras clave:** Prótesis valvular. Fuga perivalvular. Cierre percutáneo.

## INTRODUCTION

Perivalvular leaks (PVL) are common following surgery. If we use a transesophageal echocardiogram (TEE), they are detected in up to 17.6% of all cases after aortic valve replacement and in 22.6% of all cases after mitral valve replacement.<sup>1,2</sup> It normally develops when one of the sutures breaks, and is

more prevalent in patients with a diseased valve annulus, whether due to infectious endocarditis, calcium, or previous surgery.

These PVLs are normally small and have no significant clinical repercussions. They tend to improve or disappear over time, but they can occasionally give rise to serious complications, such as haemolytic anaemia requiring multiple blood transfusions or congestive heart failure.

Re-intervention due to PVL is uncommon (<2%), but it is the treatment of choice for the vast majority of patients,<sup>3</sup> even though mortality rates are high (>10%) and recurrence can be frequent.<sup>4,5</sup>

Currently, the use of Amplatzer occluders in the percutaneous treatment of certain congenital heart diseases is a very common practice.<sup>6-8</sup> Their use in

Correspondence: Dr. A.J. Muñoz-García.  
Campus de Teatinos, s/n. 29010 Málaga. España.  
E-mail: ajmunozgarcia@secardiologia.es

Received February 19, 2008.  
Accepted for publication July 15, 2008.

the treatment of PVLs in isolated cases or short series has been described recently.<sup>9-11</sup>

We would like to describe our initial experience with the use of Amplatzer occluders for the percutaneous closure of PVLs.

## METHODS

### Patients

Between 2004 and 2006, it was decided to perform percutaneous closure of PVLs in 12 patients, all of them suffering from severe regurgitation. After being evaluated for this procedure and cardiac surgery, percutaneous closure was recommended for 8 patients because they suffered from heart failure (NYHA class III-IV), severe haemolytic anaemia needing multiple blood transfusions, or from both conditions, in addition to having a high surgical risk level or technical difficulties being anticipated. Four patients were excluded due to having one or more of the following: multiple leaks, low surgical risk, or a baseline state with few systems.

A transthoracic echocardiogram and a TEE were performed to confirm the diagnosis and determine the size, location, and number of leaks. Regurgitation was determined as severe according to the parameters established by the American Society of Echocardiography, correlated with the Seller degree from the angiogram.<sup>12</sup>

The haemolytic anaemia was defined as having a concentration of haemoglobin <10g/dL in the last 2 weeks, with biochemical parameters compatible with haemolysis. Anaemia was considered to be severe when blood transfusions were necessary.

The EuroScore was calculated to predict operation mortality and evaluate the surgical risk.

Patients were monitored during the 24 hours following the procedure. Control echocardiograms were performed before the patients were discharged, and clinical and echocardiographic follow-ups were carried out after 6 and 12 months.

### Procedure Technique

Prior to the intervention, an infectious endocarditis prophylactic (cefminox 2g intravenously) and 5000 to 10000 IU of sodium heparin were administered. All procedures were carried out using local anaesthesia, and only in 1 case was TEE used as a guide measure.

The procedure was carried out according to the technique described previously.<sup>13,14</sup> Closure of mitral PVLs was performed with the anterograde approach, using transeptal catheterisation done with a Brockenbrough needle and Mullins introducer sheath. A diagnostic catheter (right

Judkins or multi-purpose) is advanced along the Mullins sheath to the left atrium. A Terumo hydrophilic guidewire was passed through the catheter to cross the PVL, the catheter was advanced across the PVL, and the hydrophilic guidewire was replaced with a 260 cm high support guidewire. Next, the Amplatzer delivery system was advanced along; once it was positioned over the opening, the Amplatzer duct occluder (AGA Medical Corporation, Golden Valley, United States) was released, after verifying that it would not interfere in the proper functioning of the prosthesis (Figure 1). The device was at least 2 mm larger than the estimated dimensions obtained by the echocardiogram and the angiogram.

The aortic PVLs were closed using the retrograde method through the right humeral artery, since the length of the Amplatzer delivery system (80 cm) makes femoral access impossible, except in very small patients. The hydrophilic guidewire was advanced through an Amplatz-type diagnostic catheter until it crossed the PVL, and the rest of the procedure was similar to that previously described (Figure 2).

## RESULTS

Four of the PVLs were aortic and the other 4 mitral. The baseline clinical characteristics are summarised in Table.

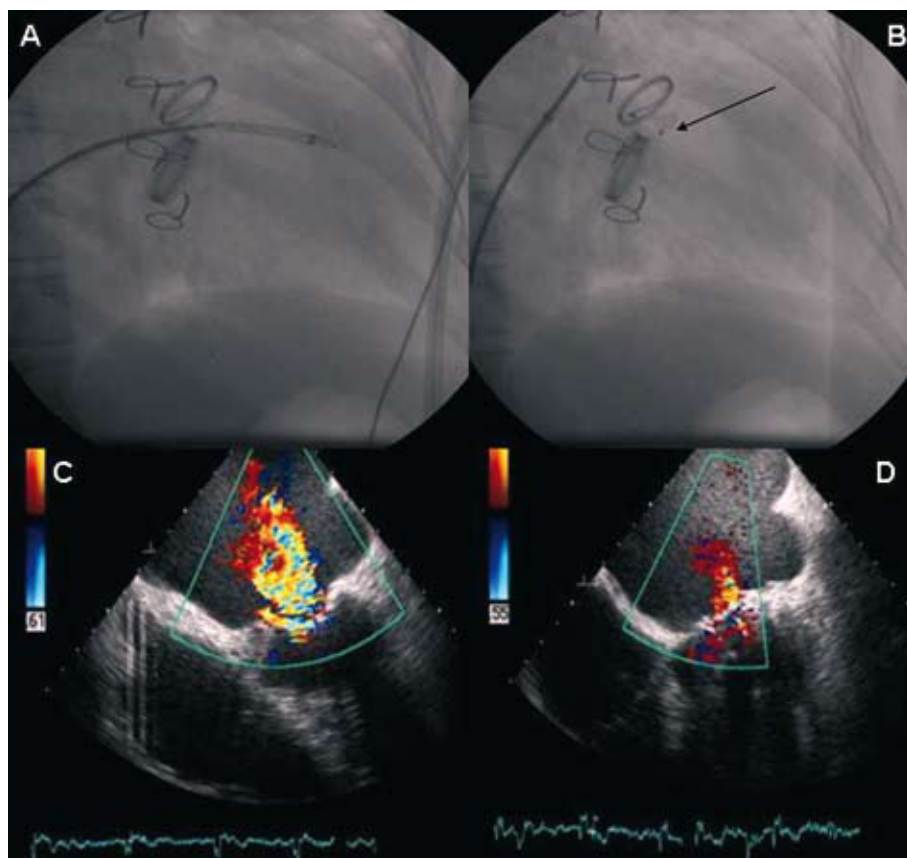
The average mortality rate based on a pre-operation estimate using the EuroSCORE was 21.5% (interval, 5.48%-54.82%). The patient with a EuroSCORE of 5.48% had undergone a second operation for PVL and had a history of infectious endocarditis.

### Implementation, Complications, and Immediate Results

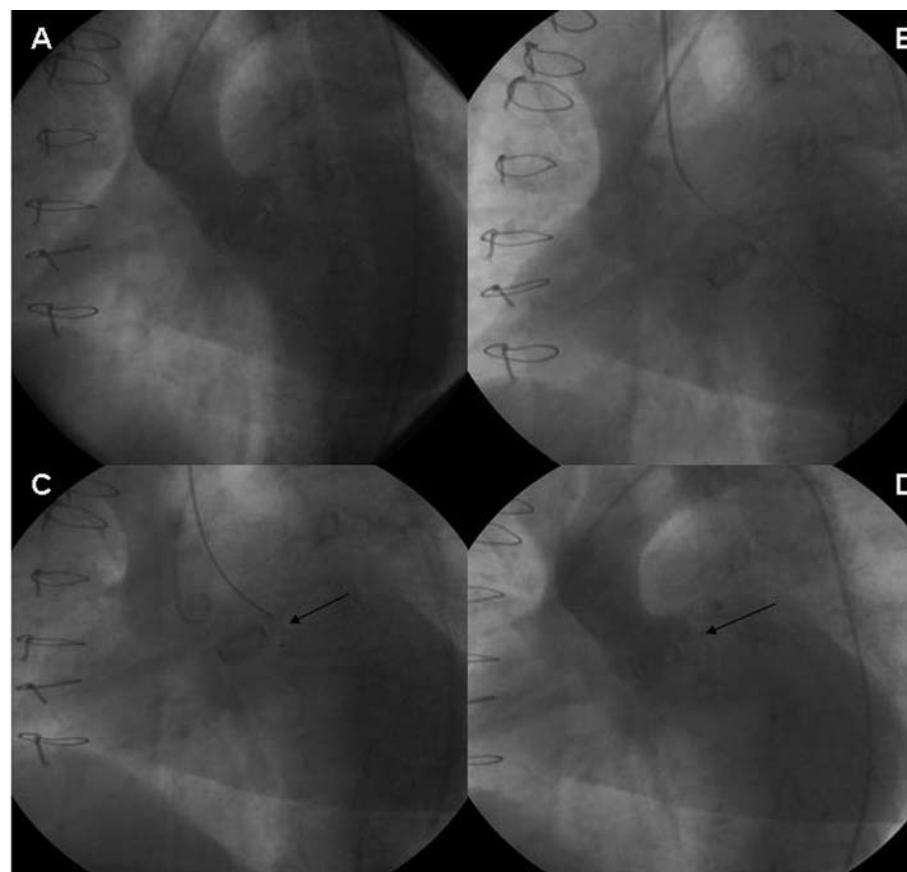
The percutaneous closure of the PVL was undertaken after a median of 79 months (7-264) since the most recent valve replacement. In 1 case of mitral PVL, a tricuspid valvuloplasty was performed simultaneously.

The implantation of the device was possible in 7 patients (87.5%), although in 1 case of aortic PVL a second procedure was necessary (the device used in the first attempt was not the right size, due to the PVL being larger than the estimate given by the echocardiogram). In 1 patient with aortic PVL, the implantation of the device was not feasible due to the difficulty of passing the delivery system through the PVL. There were no complications during the procedure.

In 2 of the 3 patients with aortic PVL and an implanted device, the decrease in the degree of



**Figure 1.** Procedure to close the mitral perivalvular leak guided by TEE due to presence of a mechanical aortic and mitral prosthesis. A: Advancing the delivery sheath through the opening. B: Occluder is released. C and D: The TEE during the procedure shows the decrease in the degree of mitral regurgitation.



**Figure 2.** Procedure to close the aortic perivalvular leak. A: Initial aortography. B: Passing the hydrophilic guidewire. C: Releasing the occluder. D: Final angiographic check showing a decreased degree of regurgitation.

**TABLA 1. Baseline Clinical Characteristics, Procedure, and Follow-up**

| Patient                                | 1   | 2  | 3   | 4                       | 5   | 6                       | 7   | 8                    |
|--|---|--|---|-------------------------|---|-------------------------|---|----------------------|
| Gender                                 | Male  | Male   | Male  | Female                  | Male  | Female                  | Male  | Male                 |
| Age, y                                 | 73  | 83   | 73  | 59                      | 82  | 59                      | 57  | 72                   |
| Type of prosthesis                     | Mechanical, CarboMedics                                   | Biological, Synergy  | Mechanical, CarboMedics                           | Mechanical, CarboMedics | Biological                                    | Mechanical, CarboMedics | Mechanical, CarboMedics                             | Mechanical, St. Jude |
| Location                               | Mitral  | Mitral   | Mitral  | Mitral and aortic       | Aortic  | Aortic                  | Aortic  | Aortic               |
| Perivalvular leak                      | Mitral  | Mitral   | Mitral  | Mitral                  | Aortic  | Aortic                  | Aortic  | Aortic               |
| Time prior to intervention, mo         | 192   | 7  | 105   | 156                     | 53  | 41                      | 45  | 264                  |
| NYHA functional degree                 | III   | III  | III   | IV                      | IV  | IV                      | III   | III                  |
| Haemolytic anaemia                     |   | Severe   |   |                         |   |                         |   | Severe               |
| EuroSCORE, %                           | 9.57  | 17.09  | 37.87   | 19.34                   | 54.82   | 5.48                    | 11.74   | 15.98                |
| Re-operated                            |   |  |   |                         |   | Yes                     |   |                      |
| History of endocarditis                |   |  | Yes   |                         |   | Yes                     |   |                      |
| Ejection fraction, %                   | 60  | 62   | 35  | 52                      | 54  | 61                      | 46  | 65                   |
| Fluoroscopy M time, min                | 23  | 20   | 38  | 47.5                    | 49.2  | 30                      | 39.1  | 68.2                 |
| Device, mm                             | 14/12   | 16/14  | 12/10   | 14/12                   | 12/10   | 10/8                    | 6/4   | 6/4                  |
| Implantation                           | Yes   | Yes  | Yes   | Yes                     | Yes, in the second procedure                  | Yes                     | Yes   | No                   |
| Degree of Regurgitation (before/after) | 4+/3+   | 4+/3+  | 4+/2+   | 4+/No                   | 4+/4+   | 4+/1+                   | 4+/2+   | –                    |
| Functional degree after 1 year         | –   | –  | II  | I                       | III   | I                       | I   | –                    |
| Follow-up on events                    | Re-operated 1 month later due to congestive heart failure | Died 1 month later due to pneumonia and congestive heart failure | Died of non-cardiovascular causes 15 months later | –                       | Died of digestive haemorrhage 14 months later | –                       | ICD implanted for sustained ventricular tachycardia | –                    |

+ indicates degree of regurgitation according to the Seller scale.

regurgitation was observable by angiogram and echocardiogram. In 2 of the 4 patients whose mitral PVL was treated, the degree of regurgitation lessened; severe perivalvular regurgitation continued in the others.

During the medium-term follow-up (Table), those patients whose degree of regurgitation had been reduced (4 of 7) showed a clinical improvement. One patient with severe ventricular dysfunction needed to have a defibrillator implanted due to sustained ventricular tachycardia.

Of the 3 patients whose degree of regurgitation did not improve, 1 underwent a procedure a month later with no complications and 2 died of non-cardiac causes (pneumonia 30 days later, and a digestive haemorrhage 14 months later).

## DISCUSSION

Symptomatic PVL, for which re-intervention is indicated, has a low incidence rate. Re-operation is the treatment of choice for the vast majority of patients, and many published surgical series refer to a mortality rate <10%, which is a better result than that given by medical treatment.<sup>15</sup> However, these results may be underestimated because some patients with a very high surgical risk are never referred for re-intervention when percutaneous treatment with Amplatzer occluders could be a therapeutic possibility.

In our study, the patients were very symptomatic and the operation risk was high with an average EuroSCORE of 21.5%. We successfully implanted

the device in 87.5% of the patients and in 57% of the cases, clinical improvement was observed which was associated with reducing periprosthetic regurgitation. This effect (GF I or II) continued after 12 months of follow-up. There were no cases of mortality or serious complications during the procedure (for example, embolisation of the occluder or interference with the prosthesis). This suggests that the technique may be safe. During follow-up, no cases of haemolytic anaemia were detected. The regurgitation that persisted in some patients was possibly due to incomplete obstruction of the opening, which in turn may be due to choosing the wrong size of occluder, multiple openings, and most of all, use of the circular Amplatzer occluder which is designed for closing certain congenital heart diseases and not PVLs, which may have a half-moon shape.

The clinical and angiographic improvements to the mitral and aortic valves were similar despite an aortic implantation error. Although technical differences exist in the treatment, which is more complex for mitral PVLs and may affect the result, the result does also depend on the type of PVL.

The literature describes isolated cases and series with reduced numbers, mostly involving mitral PVLs that are always treated under general anaesthesia and guided with TEE, which have results similar to our own. Shapira et al,<sup>9</sup> in a study of 11 cases (8 mitral) reached an implantation rate of 90.9% and a reduction of 60% in the degree of regurgitation. Pate et al,<sup>10</sup> in a study of 10 patients (9 mitral) reached an implantation rate of 70% and saw angiographic success in 60%, but 1 patient did require emergency surgery.

## Limitations

The principal limitations are that the series is small and studied in one centre, and that the results depend on the operator, given that the technique is complex.

In addition, the Amplatzer occluder is not specifically designed for treating PVLs, which could explain certain failures and difficulties with the technique.

In conclusion, the results seem to indicate that percutaneous treatment of PVLs, whether mitral or aortic, is technically feasible and safe, and can be used as an alternative treatment for patients with a high surgical risk level.

## REFERENCES

1. O'Rourke DJ, Palac RT, Malenka DJ, Marrin CA, Arbuckle BE, Plehn JF. Outcome of mild periprosthetic regurgitation detected by intraoperative transesophageal echocardiography. *J Am Coll Cardiol.* 2001;38:163-6.
2. Ionescu A, Fraser AG, Butchart EG. Prevalence and clinical significance of incidental paraprosthetic valvar regurgitation: A prospective study using transesophageal echocardiography. *Heart.* 2003;89:1316-21.
3. Miller DL, Morris JJ, Schaff HV, Mullany CJ, Nishimura RA, Orszulak TA. Reoperation for aortic valve periprosthetic leakage: identification of patients at risk and results of operation. *J Heart Valve Dis.* 1995;4:160-5.
4. Pansini S, Ottino G, Forsennati PG, Serpieri G, Zattera G, Casabona R, et al. Reoperations on heart valve prostheses: an analysis of operative risk of reoperative risks and late results. *Ann Thorac Surg.* 1990;50:590-6.
5. Cohn LH, Aranki SF, Rizzo RJ, Adams DH, Cogswell KA, Kinchla NM, et al. Decrease in operative risk of reoperative valve surgery. *Ann Thorac Surg.* 1993;56:15-20.
6. Fernández A, del Cerro MJ, Rubio D, Castro MC, Moreno F. Cierre percutáneo de la comunicación interauricular mediante dispositivo de Amplatz: resultado inicial y seguimiento a medio plazo. *Rev Esp Cardiol.* 2001;54:1190-6.
7. Rodríguez M, Suárez de Lezo J, Pan M, Romero M, Segura J, Pavlovic D, et al. Cierre percutáneo de comunicaciones interauriculares grandes. *Rev Esp Cardiol.* 2003;56:888-93.
8. Holzer R, Balzer D, Cao Q-L, Lock K, Hijazi ZM. Device closure of muscular ventricular defects using the Amplatzer muscular ventricular septal defect occluder. Immediate and mid-term results of U.S. registry. *J Am Coll Cardiol.* 2004;43:1257-63.
9. Shapira Y, Hirsch R, Kornowski R, Hasdai D, Assali A, Vaturi M, et al. Percutaneous closure of perivalvular leaks with Amplatzer occluders: feasibility safety, and short-term results. *J Heart Valve Dis.* 2007;16:305-13.
10. Pate GE, Al Zubaidi A, Chandavimol M, Thompson CR, Munt BI, Webb JG. Percutaneous closure of prosthetic paravalvular leaks: Case series and review. *Catheter Cardiovasc Interv.* 2006;68:528-33.
11. Hein R, Wunderlich N, Robertson G, Wilson N, Sievert H. Catheter closure of paravalvular leak. *Eurointerv.* 2006;2:318-25.
12. Zoghbi WA, Enriquez-Sarano M, Foster E, Grayburn PA, Kraft CD, Levine RA, et al. American Society of Echocardiography. Recommendations for evaluation of the severity of native valvular regurgitation with two-dimensional and Doppler echocardiography. *J Am Soc Echocardiogr.* 2003;16:777-802.
13. Piechaud JF. Percutaneous closure of mitral paravalvular leak. *J Interv Cardiol.* 2003;16:153-5.
14. Webb JG, Pate GE, Munt BI. Percutaneous closure of an aortic prosthetic paravalvular leak with an Amplatzer duct occluder. *Catheter Cardiovasc Interv.* 2005;65:69-72.
15. Genoni M, Franzen D, Vogt P, Seifert B, Jenni R, Künzli A, et al. Paravalvular leakage after mitral valve replacement: improved long-term survival with aggressive surgery? *Eur J Cardiothorac Surg.* 2000;17:14-9.