

# Diagnosis of Aortic Arch Thrombosis by Two-Dimensional Echocardiography from the Jugular Fossa in a Patient with Protein C Deficiency

Carlos Delgado Ramis and Fernando Barturen<sup>a</sup>

Servicio de Cardiología y <sup>a</sup>Unidad de Cuidados Intensivos. Policlínica Miramar. Palma de Mallorca. Baleares. España.

We describe the case of a 63-year-old man who suffered concomitant cerebral, mesenteric, and renal infarctions. Idiopathic dilated cardiomyopathy without intracardiac masses was diagnosed by transthoracic echocardiography. A cross-sectional view of the innominate artery from the jugular fossa notch position revealed a threatening thrombus in the proximal region of the aortic arch. Severe functional protein C deficiency was diagnosed by hematologic study.

**Key words:** *Protein C. Thrombosis. Aorta. Echocardiography.*

Full English text available at: [www.revespcardiol.org](http://www.revespcardiol.org)

## Visualización de un trombo en el cayado aórtico desde la fosa yugular en un paciente con déficit de proteína C

Presentamos el caso de un varón de 63 años que de forma simultánea presentó infartos cerebral, mesentérico y renal de carácter embólico. El estudio ecocardiográfico mostró una miocardiopatía dilatada idiopática sin fuentes embolígenas intracardíacas. La visualización de la porción proximal del cayado, alineando la arteria innominada desde la ventana de la fosa yugular, permitió observar el trombo «amenazante» casual. El estudio hematológico reveló un grave déficit de proteína C funcional.

**Palabras clave:** *Proteína C. Trombosis. Aorta. Ecocardiografía.*

## INTRODUCTION

Protein C is a glycoprotein that is dependent on vitamin K synthesized by the liver and acts as a physiological anticoagulant that hydrolyzes factors Va and VIIIa. It probably increases fibrinolytic activity by neutralizing the inhibition of plasminogen; consequently, protein C deficiency induces hypercoagulability. The genetic defect is a simple mutation in exon 7 of the protein C gene located on chromosome 2q13-q14.<sup>1</sup> Protein C deficiency is usually manifested as thrombosis of the venous system, with a prevalence of arterial thrombosis reaching 7.1% in a study of 337 heterozygotes.<sup>2</sup> Generally speaking, additional vascular risk factors must be present for arterial involvement to occur.<sup>3</sup> Although aortic thrombosis at different levels has been frequently reported, its association with protein C deficiency has not often been reported

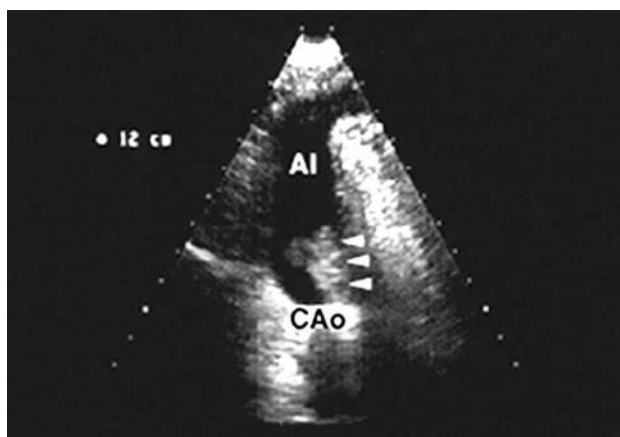
in the literature.<sup>4</sup> In the case presented here, the diagnosis and follow-up of aortic arch thrombosis was made using a window in the jugular fossa, a technique used more often in radiology than in routine echocardiography practice.

## CLINICAL CASE

The case presented was a 63-year-old man with no known cardiovascular risk factors who was referred from another hospital with the diagnoses of abdominal pain to be studied and repeated cerebrovascular accidents over a 13-day period. The Doppler study of the carotid was normal, cerebral CT performed at admission disclosed right temporal infarction, and transthoracic echocardiography revealed severe dilated cardiomyopathy with diffuse hypokinesia, ejection fraction 30%, and absence of cardiac valve disease or other possible sources of emboli. Since transesophageal echocardiography was not available, anticoagulation was begun with sodium heparin, which had to be discontinued 5 days later in view of CT evidence of a mild hemorrhagic transformation of the temporal infarction. The patient continued to present transient is-

Correspondence: Dr C. Delgado Ramis.  
C/ Reina Esclaramunda, 1, 2.º piso, puerta derecha.  
07003 Palma de Mallorca. España.  
E-mail: [delgadoramis@worldonline.es](mailto:delgadoramis@worldonline.es)

Received 12 December 2001.  
Accepted for publication 9 May 2002.



**Fig. 1.** 2-D echo image, obtained from the right jugular fossa, of the longitudinal long axis of the brachiocephalic trunk, from its origin on the proximal portion of the aortic arch. A large pediculated thrombus is visible (arrowheads), with zones of less echogenicity and a broad base of implantation (1 cm) on the lower wall of the aortic arch, before beginning anticoagulant treatment. AoA indicates aortic arch; BT, brachiocephalic trunk.

chemic events. His digestive semiology remained latent in the context of turbulent cerebrovascular instability. Thirteen days after admission, the patient was transferred to our center at the request of his family.

Upon admission to the intensive care unit, the patient, who had been breathing spontaneously without hypoxemia, had a Glasgow scale score of 12, dysarthria, left palpebral ptosis, and homolateral hemiparesis. The patient had no signs of heart failure, sinus rhythm 110 beats/min with LBBB, and no murmurs in cardiac auscultation. Aside from the neurological findings, the patient had abdominal distension and pain in the right iliac fossa. Cerebral CT demonstrated the presence of ischemic, low-density areas in the right temporal lobe and confirmed the disappearance of the residual hemorrhagic component. Abdominal CT revealed low-density images in both kidneys compatible with embolic ischemic infarctions and a thickened intestinal loop responsible for the occlusive condition. In view of these findings and suspecting mesenteric ischemia, emergency laparotomy was performed. It disclosed segmental ileal necrosis that did not affect the rest of the intestinal tract. The ileum was resected and side-to-side anastomosis was performed. In the postoperative period of abdominal surgery, which was free of complications, transthoracic echocardiography did not reveal any new findings with respect to the previous study. Before making the transesophageal study, the aortic arch and descendent thoracic aorta were evaluated. When the brachiocephalic trunk was aligned with the right jugular fossa, a thrombus 30 mm long by 20 mm wide was visible that was fringed, movable, and had a broad base of implantation on the aortic wall (10 mm) that «threatened» the *ostium* of the brachiocephalic trunk (Figure 1). Transesophageal study with a

multiplane probe showed an aorta of normal morphology, free of calcification throughout the thoracic segment and first regions of the abdominal segment. Zones of aneurysm, thrombosis, or dissection were excluded. Nevertheless, at the height of the proximal aortic arch, the image obtained from the jugular fossa suggested a thrombus of ominous appearance, with friable, snake-shaped, and vegetative characteristics (Figure 2A).

Due to the echocardiographic findings, the decision was made to give the patient anticoagulant treatment with sodium heparin for one week, continuing with acenocoumarol (INR 3.0 to 4.0). No new embolic episodes occurred. Coagulation tests made in the acute phase showed a functional protein C deficiency of less than 10% (normal values range from 70% to 130%) and hyperfibrinogenemia of 849 mg/dL. The prothrombin time, antithrombin III, coagulative protein S, homocysteine, and anticardiolipin and antinuclear antibodies were normal. Factor V (Leyden mutation), lupus anticoagulant, and mutation of the prothrombin gene were negative. The lipid profile was normal.

Two months after admission of the patient, transesophageal echography demonstrated an atheroma approximately 2-cm long located in the anterior wall of the aorta, which was concluded to be the probable cause for nesting of the aortic thrombus. The thrombus had disappeared, but the plaque had not been visualized in the study made in the acute phase of thrombosis (Figure 2B).

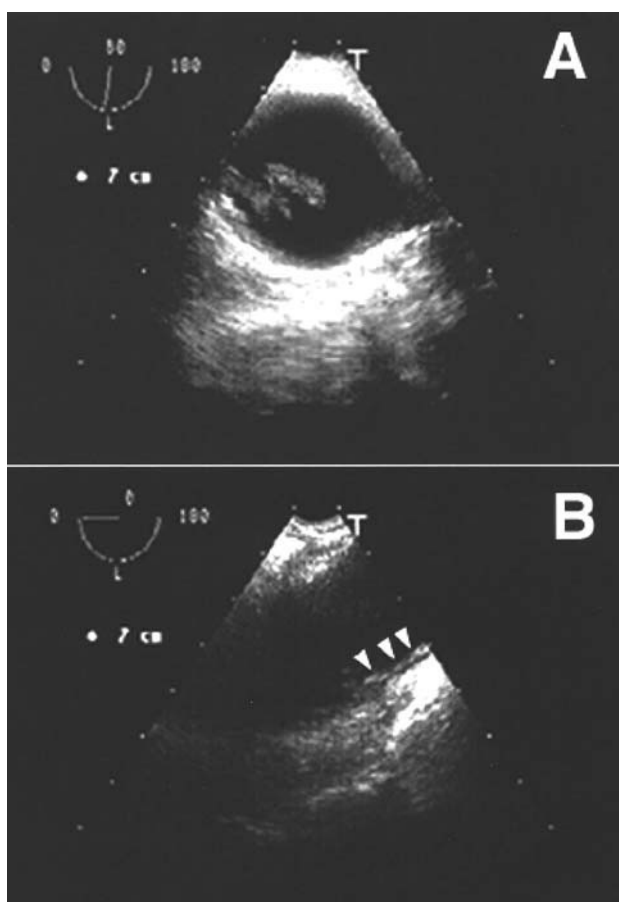
Due to the accessibility of the jugular fossa, in this patient, for visualizing the brachiocephalic trunk and the initial part of the aortic arch, the remission of the thrombus could be controlled (Figure 3A) until it had completely disappeared, which occurred 40 days after oral anticoagulant treatment began (Figure 3B).

After 5 months of treatment with acenocoumarol, it was replaced by subcutaneous enoxaparin at a dose of 75 mg/12 h for one week for the purpose of controlling protein C values. Functional protein C values of 29% (in normal conditions, from 70% to 130%) and of antigenic protein C of 1.60 mg/dL (in normal conditions, from 1.70 to 3.20 mg/dL) confirmed the previous finding of a severe and predominantly functional protein C deficiency in our patient.

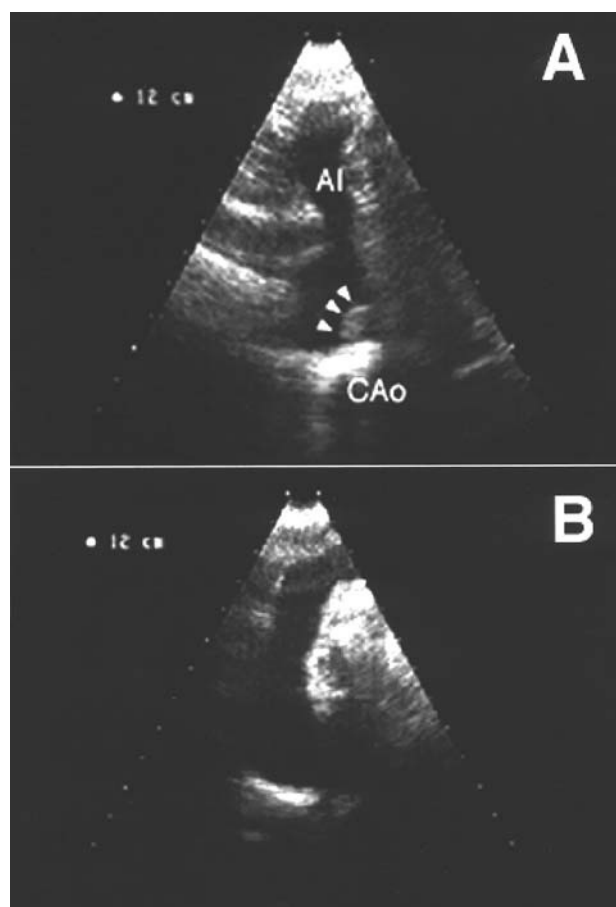
Familial coagulation studies did not reveal thrombophilia.

## DISCUSSION

Arteriosclerotic disease of the thoracic aorta is recognized as a potential source of cerebral and peripheral embolisms. Transesophageal echography is the technique of choice in these patients as a noninvasive intervention for both diagnosis and therapeutic follow-up.<sup>5,6</sup> Although thrombotic pathology of the aorta is habitually related to the classic cardiovascular risk



**Fig. 2.** A. Multiplane transesophageal 2-D echo image of the transverse axis of the proximal portion of the aortic arch obtained before beginning anticoagulant treatment. A «threatening» thrombus of friable, snake-shaped, and vegetative appearance is observed. B. At 8 weeks of treatment, after the thrombus had disappeared, a longitudinal atheroma plaque (arrowheads) at least 2 cm long by 0.2 cm thick is visible where the thrombus was previously located.



**Fig. 3.** Control, by 2-D echo acquired from the jugular fossa, of the remission of the thrombus of the aortic arch at 3 and 5 weeks, respectively, from the onset of anticoagulant treatment. A. Decreased size of the thrombus (arrowheads), which has a homogeneous echogenic appearance and smooth margins, indicating less fragility. B. Disappearance of thrombus. AoA indicates aortic arch; BT, brachiocephalic trunk.

factors, our growing familiarity with thrombophilic situations is making it possible to identify an appreciable number of patients with pathology of the coagulation factors, generally of genetic origin.

In the case presented here, several points merit comment, beginning with the thrombophilic etiology of the case. In the acute phase, while sodium heparin treatment was still being given, coagulation studies disclosed a primary protein C deficiency that was confirmed 5 months later, after discontinuing the oral anticoagulants that are known to interfere with protein C. Heterozygotic protein C deficiency is present in 2%-5% of patients with thrombosis and in up to 0.3%-0.5% of healthy subjects, suggesting the association of an increment in risk, which increases the incidence of venous thrombosis by up to 10-fold. Our patient had a type II deficiency because it affected mainly the functional activity of protein C, but not its antigenic activity (the parallel reduction of both activities corresponds to type I).<sup>7</sup> As reported in the literature,

additional vascular risk factors generally must be present in order for the arterial system to become involved in patients with protein C deficiency, as reflected by the finding of an atheroma plaque on the aortic arch of our patient (Figure 2B). In contrast with other congenital risk factors, protein C deficiency can be effectively treated. Whereas inhibitors of platelet aggregation, such as aspirin and ticlopidine, are ineffective, anticoagulation with coumarins prevents future thrombotic accidents.<sup>3</sup> The conservative therapeutic attitude in this case, consisting of the administration of anticoagulants in the presence of a threatening thrombus with high embolic potential, was taken in light of the high risk of surgery of the aortic arch in a patient with recent cerebral infarction.

Another interesting aspect of this case was the echographic window used for the diagnosis of aortic arch thrombosis and the therapeutic follow-up of anticoagulant treatment. In the field of transthoracic echocardiography, particularly pediatric, the accessibility by

2-D echo to the origin of the supra-aortic trunks from the aortic arch using the suprasternal and high left parasternal windows is well-known.<sup>8</sup> Nevertheless, the visualization of the trunks through the neck usually requires the intervention of radiologists using conventional echography. The region of the jugular fossa is located inside the supraclavicular fossa, delimited externally by the clavicular fascicle of the sternocleidomastoid and internally by the sternal fascicle of this muscle. Direct bidimensional examination of the brachiocephalic trunk from this window is not easy for radiologists and sometimes is fruitless, especially in obese patients. In contrast, the behavior of blood flow can be hemodynamically assessed by pulsed and continuous Doppler. In our case, probably the smaller size of the transducers used in cardiology and the fact that our patient was not obese and had a long neck allowed us to achieve a perfect alignment of the longitudinal axis of the brachiocephalic trunk from its origin on the proximal portion of the aortic arch. In this position it was possible to observe a thrombus of large size adhered to the lower aortic wall with a broad base of implantation. Transesophageal echography was used in this case to confirm the morphology of the thrombus, after the diagnosis had been reached using the window of the jugular fossa, and, later, to assess the aortic wall after resolution. However, the response to treatment was followed-up completely by echography of the jugular fossa, which made studies quicker and more comfortable for the patient.

In summary, we report an uncommon case of «spontaneous» thrombosis of the aortic arch in a patient with multiple central and peripheral embolic accidents and functional protein C deficiency. After 3 years of follow-up, conservative treatment with acenocoumarol has been shown to be fully satisfactory. The diagnosis

and follow-up of response to anticoagulant treatment was carried out noninvasively by bidimensional echography using the window of the jugular fossa.

## REFERENCES

1. Nakagawa K, Tsuji H, Masuda H, Kitamura H, Nakahara Y, Ogasahara Y, et al. Protein C deficiency found in a patient with acute myocardial infarction: a single base mutation 157 Arg (CGA) to stop codon (TGA). *Int J Hematol* 1994;60:273-80.
2. De Stefano V, Leone G, Micalizzi P, Teofili L, Falappa PG, Pollari G, et al. Arterial thrombosis as clinical manifestation of congenital protein C deficiency. *Ann Hematol* 1991;62:180-3.
3. Hacker SM, Williamson BD, Lisco S, Kure J, Shea M, Pitt B. Protein C deficiency and acute myocardial infarction in the third decade. *Am J Cardiol* 1991;68:137-8.
4. Gremse DA, Peevy KJ, Walterspiel JN, Johnson WH Jr. Aortic thrombosis in a neonate with undetectable protein C. *Pediatr Radiol* 1990;20:198-9.
5. Tunick PA, Rosenzweig BP, Katz ES, Freedberg RS, Pérez JL, Kronzon I. High risk for vascular events in patients with protruding aortic atheromas: a prospective study. *J Am Coll Cardiol* 1994;23(5):1085-90.
6. Laraudogoitia E, Evangelista A, García del Castillo H, Lekuona I, Palomar S, González-Alujas T, et al. Trombo en aorta torácica como causa de embolismo periférico diagnosticado por ecocardiografía transesofágica. *Rev Esp Cardiol* 1997;50:62-4.
7. Zöller B, García de Frutos P, Hillarp A, Dahlbäck B. Thrombophilia as a multigenic disease. *Haematologica* 1999;84:59-70.
8. Musewe NN, Smallhorn JF, Burrows PE, Izukawa T, Freedom RM. Echocardiographic and Doppler evaluation of the aortic arch and brachiocephalic vessels in cerebral and systemic arteriovenous fistulas. *J Am Coll Cardiol* 1988;12(6):1529-35.
9. Brunhölzl CH, Von Reutern GM. Hemodynamic effects of innominate artery occlusive disease. Evaluation by Doppler ultrasound. *Ultrasound in Med & Biol* 1989;15(3):201-4.