

Image in cardiology

Dislodgement and Embolization of a Left Atrial Appendage Thrombus



Desprendimiento y embolización de trombo de orejuela izquierda

Ignacio Hernández González, Miguel Ángel Navas Lobato,* and Jerónimo Farré Muncharaz

Servicio de Cardiología, Hospital Universitario Fundación Jiménez Díaz, IDC Salud, Universidad Autónoma de Madrid, Madrid, Spain

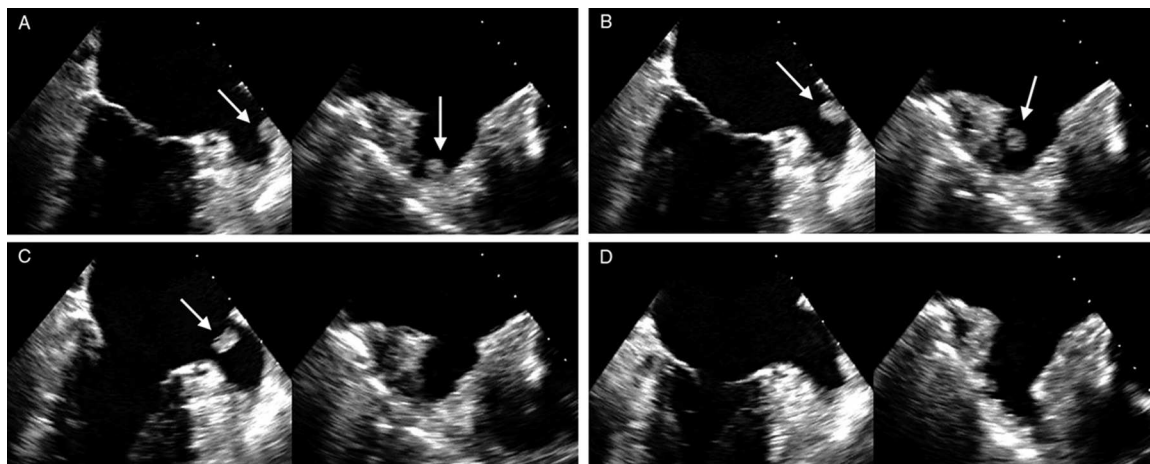


Figure.

An 80-year-old man was admitted to our center because of recurrent ischemic strokes. Notably, the patient had recently been diagnosed with adenocarcinoma of the lung and was waiting to start radiation therapy. In addition, he was receiving chronic anticoagulation therapy with a coumarin derivative for permanent atrial fibrillation and maintained adequate international normalized ratio (INR) control.

We performed a transesophageal study to evaluate the sources of embolism. The image, a 2-chamber view of the mid-esophagus and its orthogonal projection, obtained simultaneously by a 3-dimensional probe (Figure A, Video 1 of the supplementary material), showed a thrombus (10 mm × 8 mm) attached to the atrial appendage wall. During the procedure, we observed the precise moment when the thrombus became detached from its anchorage on the atrial appendage wall and its mobilization (Figures B and C, Video 2 of the supplementary material). Following the disappearance of the thrombus, the pectinate muscles were identified only at the level of the tip of the atrial appendage pouch (Figure D, Video 3 of the supplementary material). During the study, there were no changes in rhythm, which remained in atrial fibrillation. The patient had a splenic infarction, confirmed by computed tomography.

Thrombus formation in the left atrial appendage can occur in individuals with lung cancer, despite adequate anticoagulation with vitamin K antagonists. The findings in our patient led to a change in the anticoagulant therapy, and anticoagulation with low-molecular-weight heparin was initiated.

SUPPLEMENTARY MATERIAL



Supplementary material associated with this article can be found in the online version available at [doi:10.1016/j.rec.2014.02.018](https://doi.org/10.1016/j.rec.2014.02.018).

* Corresponding author:
E-mail address: manavaslol@gmail.com (M.& Navas Lobato).
Available online 12 June 2014