

Double-Wire Technique for Implanting a Left Ventricular Venous Lead in Patients With Complicated Coronary Venous Anatomy

Elena Arbelo, Alfonso Medina, José Bolaños, Antonio García-Quintana, Eduardo Caballero, Antonio Delgado, Francisco Melián, Celestina Amador, and Javier Suárez de Lezo

Servicio de Cardiología, Hospital Universitario de Gran Canaria Dr. Negrín, Las Palmas de Gran Canaria, Spain

Introduction and objectives. Occasionally, implanting a left ventricular pacing electrode for cardiac resynchronization therapy via the coronary sinus may be complicated by the presence of anatomical structures that obstruct the access to the target vein. Our objective was to report on experience using a double-wire technique for implanting left ventricular venous leads gained at the Dr Negrín Hospital in Gran Canaria, Spain.

Methods. In 20 (12%) of 170 consecutive patients (67 ± 9 years, 72% male) undergoing implantation of a cardiac resynchronization device, a second parallel hydrophilic guidewire had to be used during lead implantation in the target vein as implantation was impossible without using this technique.

Results. Implantation using a conventional approach was impossible because there was severe tortuosity at the vessel entrance in 5 patients (25%), a sharp angle at the entrance to the target vein in 7 (35%), a venous valve at the vessel entrance in 8 (40%), and, finally, poor support for the guiding catheter in four (20%), due to the presence of either a fenestrated Thebesian valve (2 patients) or a restrictive Vieussens valve (2 patients) that blocked passage of the guiding catheter or electrode. In 4 patients (20%), there was more than 1 factor. In all these cases, implantation was achieved in the target vein without complications after passage of a second hydrophilic guidewire.

Conclusions. The use of a second parallel guidewire (ie, the double-wire technique) provides a safe and effective way of implanting left ventricular venous pacing electrodes in patients with anatomical complications.

Key words: Heart failure. Electrical stimulation. Pacemakers. Cardiac resynchronization therapy. Biventricular pacing. Vein.

SEE EDITORIAL ON PAGES 97-100

Correspondence: Dr. E. Arbelo Lainez.
Ctra. General del Centro, 239.
35017 Las Palmas de Gran Canaria. España.
E-mail: elenaarbelo@secardiologia.es

Received August 28, 2006.
Accepted for publication November 2, 2006.

Técnica de la doble guía para el implante del electrodo venoso ventricular izquierdo en pacientes con anatomía venosa coronaria desfavorable

Introducción y objetivos. El implante de un electrodo ventricular izquierdo a través del seno coronario plantea, en ocasiones, cierta dificultad debido a obstáculos anatómicos que limitan el acceso a la vena diana. El objetivo es analizar la experiencia del Hospital Universitario de Gran Canaria Dr. Negrín con la técnica de la doble guía en el implante de un electrodo venoso ventricular izquierdo.

Métodos. De 170 pacientes consecutivos (67 ± 9 años, 72% varones) a los que se implantó un dispositivo de resincronización se recurrió, en 20 de ellos (12%), al uso de una segunda guía hidrofílica en paralelo para el implante del electrodo en la vena diana, dada la imposibilidad de implante sin esta técnica.

Resultados. Las causas de imposibilidad de implante con la técnica convencional fueron: tortuosidad extrema del vaso en su desembocadura (5 pacientes, 25%), ángulo marcado en la desembocadura de la vena diana (7 pacientes, 35%), presencia de una válvula venosa en dicha localización (8 pacientes, 40%) y, finalmente, escaso soporte del catéter guía (4 pacientes, 20%), bien por válvula de Tebesio fenestrada (2 pacientes) o por válvula de Vieussens restrictiva (2 pacientes) que no permitía el avance del catéter guía y/o del electrodo. En 4 casos (20%) hubo más de un factor. En todos los casos, tras avanzar una segunda guía hidrofílica se pudo realizar el implante en la vena diana sin complicaciones.

Conclusiones. El uso de una segunda guía en paralelo (técnica de la doble guía) es un procedimiento seguro y eficaz para el implante del electrodo ventricular izquierdo en pacientes con anatomía desfavorable.

Palabras clave: Insuficiencia cardíaca. Estimulación eléctrica. Marcapasos. Terapia de resincronización cardíaca. Estimulación biventricular. Venas.

INTRODUCTION

In recent years, heart failure has become one of most important public health problems of developed nations, both in terms of the increase in its incidence and the

enormous personal, social and economic repercussions it is likely to have in the near future.^{1,2} Currently, heart failure affects more than 22 million people worldwide,³ is the third most common cardiovascular cause of death, and is an important cause of morbidity and hospitalizations.⁴

Biventricular pacing is an option for patients with heart failure; its benefits have been shown in a number of prospective, randomized trials.⁵⁻¹¹ Improvements have been described in functional class, quality of life, and the distance covered in the 6 min walk test.⁵⁻⁷ More recently, reductions in overall mortality,¹¹ as well as in morbidity and mortality due to heart failure, have also been reported.¹²

The benefits of cardiac resynchronization, however, do not depend solely upon the careful selection of patients, but also on the final position of the implanted leads, especially of that which will stimulate the left ventricle. A number of animal¹³ and human studies¹⁴⁻¹⁶ have shown there to be a close relationship between the site of stimulation and the magnitude of the ventricular functional response to cardiac resynchronization. The available data show the ideal locations to be the lateral or posterolateral regions since it is here where the greatest contractile delay is seen under conditions of left bundle block.¹⁷

The implantation of a cardiac resynchronization device can be performed via the venous route without difficulty in about 80%-90% of patients—a consequence of the technological advances made in recent years and the greater experience of medical personnel in implanting left ventricular leads.^{3,18-22} However, problems can appear in some 10%-20% of cases, the consequences of which can be serious since the implantation of the left ventricular lead at an inadequate site can result in the failure of resynchronization therapy. The only alternative to intravenous implantation is that involving thoracotomy, an option currently regarded as being undesirable.

A number of obstacles can hinder the implantation of the venous coronary lead. The main causes of failure to implant this electrode include the impossibility of advancing the guidewire to the coronary sinus, a complicated venous anatomy, the presence of phrenic stimulation and/or the instability of the lead in the selected position, and (exceptionally) an inability to cannulate the coronary sinus ostium.²³⁻²⁵

The present work examines our experience of the double-wire technique for the implantation of over-the-wire electrodes in patients with complicated anatomy in whom the conventional implantation technique was unviable.

METHODS

The study subjects were 170 patients (age 66.7 ± 9.1 years, 72% men, New York Heart Association

[NYHA] functional class 2.98 ± 0.56 , left ventricular ejection fraction 29.2 ± 11.3 , QRS complex 156.3 ± 26.8 ms); between May 2002 and October 2006 all were fitted with cardiac resynchronization devices at our center. In 20 (11.8%) of these patients the use of a second, parallel, hydrophilic guidewire was required in order to implant the lead in the target vein; implantation of the lead was impossible with the conventional technique. Table 1 shows the clinical characteristics of the patients.

Implantation Technique

In all cases the coronary sinus was accessed with a wide angle guiding catheter (CS-Wide, Guidant Corp., St. Paul, MN, USA), a telescopic catheter, and a hydrophilic guidewire. The use of a hemostatic valve allowed the manipulation of the guidewire and the injection of the contrast medium. Firstly, the guidewire was advanced towards the coronary sinus, and after removing the telescopic catheter a balloon catheter was put in place following the guidewire. Occlusive sinus venography was then performed using 4 mL of contrast medium at a rate of 3 mL/s; images were obtained from the anteroposterior and anterior left oblique 20° views. After retracting the balloon catheter, the target vein was accessed by the guidewire and an attempt made to advance an over-the-wire electrode (Easy Track 2, Guidant Corp., St. Paul, MN, USA) following the guidewire. The conventional technique was considered to have failed if, once the guidewire was in the selected vein, it was impossible to advance the lead into the vein, the guidewire repeatedly retreating. Selective angiography was then used to determine the nature of the obstacle. Once this was complete, a second, polymer-coated, hydrophilic guidewire (Whisper or PT-Graphic) was inserted into the target vein and efforts to advance the lead reinitiated (Figure 1). During this maneuver a second operator controlled the second guidewire in order to prevent any undesirable progression; meanwhile, the first operator performed the implantation as normal. After implanting the lead, the second guidewire was retracted without difficulty and the guiding catheter removed after substituting the guidewire occupying the lumen of the lead for a finishing wire.

RESULTS

The lead was implanted in a lateral vein of the left ventricle in 18 (90%) of the 20 patients that underwent the double-wire procedure, in a secondary ascending branch (with a trajectory in the free wall of the left ventricle) of a vein with its origin close to the coronary sinus ostium in one patient (5%), and in an anterolateral vein (a tributary of the anterior interventricular vein) in one other (5%). The mean target vein diameter was 4.4 ± 1.3 mm.

TABLE 1. Clinical Characteristics of the Patients Treated With Cardiac Resynchronization Therapy Using the Double-Wire Technique (n=20)*

Age, y	70.9 (7.2)
Sex, male	12 (60%)
NYHA functional class	2.95 (0.7)
II	3 (15%)
III	13 (65%)
IV	4 (20%)
Etiology, %	
Idiopathic dilated cardiomyopathy	10 (50%)
Ischemic cardiomyopathy	6 (30%)
Valvular	2 (10%)
Other	2 (10%)
Rhythm, %	
Sinus	18 (90%)
Atrial fibrillation	2 (10%)
Electrocardiogram	
Duration QRS, ms	155.6 (34.3)
Duration PR, ms	198 (28.1)
LBBB, %	16 (80%)
EF (by angiography), %	26.6 (7.2)
Echocardiogram	
LVEDD, mm	67.5 (13.7)
LVESD, mm	62.8 (15)
LVEDV, mL	259.2 (97.7)
LVESV, mL	203.9 (87.2)
EF (Simpson formula), %	25.1 (6.2)
Medication, %	
ACE inhibitors/ARA-II	18 (90%)
Beta-blockers	17 (85%)
Spironolactone	15 (75%)
Loop diuretics	19 (95%)
Digoxin	2 (10%)

*ARA-II indicates angiotensin II receptor antagonists; LVEDD, left ventricular end-diastolic diameter; LVESD, left ventricular end-systolic diameter; EF, ejection fraction; ACE inhibitors, angiotensin converting enzyme inhibitors; LVEDV, left ventricular end-diastolic volume; LVESV, left ventricular end-systolic volume; LBBB, left bundle branch block.

In 2 patients the presence of a restrictive, fenestrated Thebesian valve caused the guiding catheter to provide insufficient support during implantation. In one patient it was impossible to advance the guiding catheter beyond the coronary sinus ostium because the Thebesian valve was very large and restrictive, covering 95% of the orifice. In the other, the guidewire passed through a fenestration of the Thebesian valve which, because of its small size, did not permit access to the guiding catheter. In both cases the lead was finally implanted –without adequate support from the guiding catheter–using a second, parallel, hydrophilic guidewire.

A prominent Vieussens valve was another anatomical factor that limited the advance of the guidewire inside the coronary venous system (2 patients). Although the guidewire managed to get past the Vieussens valve with some difficulty, the progress of the guiding catheter and/or the lead to be implanted was prevented. The introduction of a second, parallel guidewire allowed the opening of this valve and gave sufficient support for the lead to be implanted in the target vein. Figure 2 shows two examples in which the guiding catheter provides insufficient support in the presence of a restrictive Vieussens valve and a fenestrated Thebesian valve, and in which the use of a second guidewire was decisive in the successful implantation of the lead.

In the 20 patients in whom the conventional technique was unviable, the target vein showed characteristics that impeded the normal implantation of the lead. In five patients a tortuous origin of the vein was overcome with the use of the double-wire technique. In 7 cases the angle at the origin of the vein was greater than 90°, and the second hydrophilic guidewire was necessary to overcome this. Finally, when it was impossible to advance the lead through an apparently ideal target vein, the existence of a valve structure at the origin of the vein was inferred (eight patients). This was confirmed by the absence of a notch

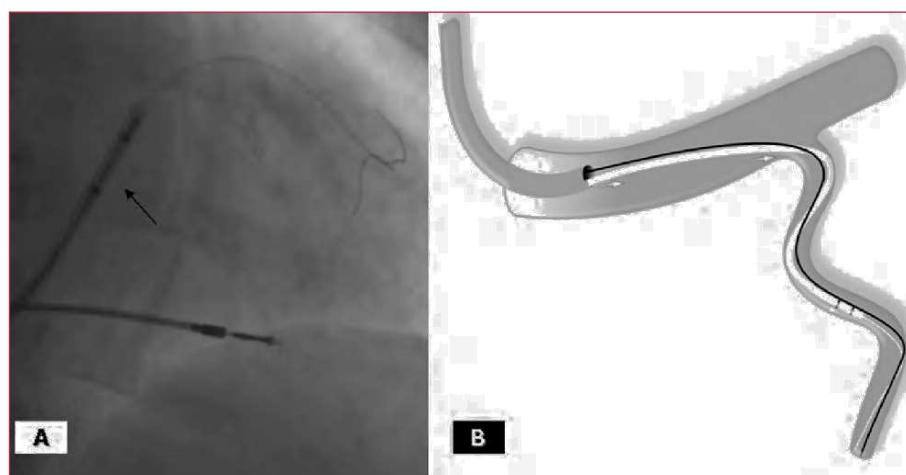


Figure 1. A: This figure shows the guiding catheter close to the mouth of the vein and two hydrophilic guidewires, one inside the lumen of the lead (arrow) and the other parallel to it. B: Diagram showing the guiding catheter with two guidewires (outside the catheter) and the lead in the target vein.

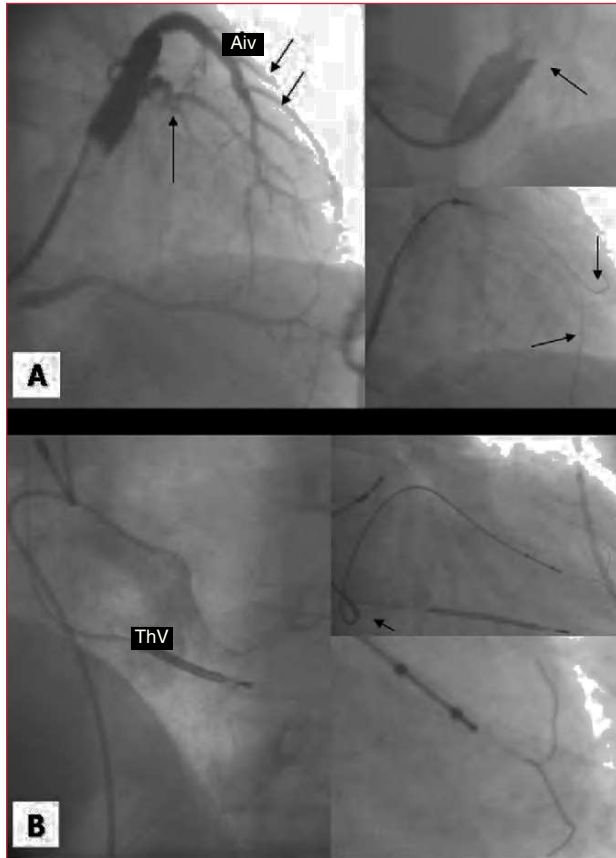


Figure 2. A. Occlusive coronary sinus venography showing a lateral target vein (arrow) and the anterior interventricular vein with multiple anterolateral veins (arrows). The upper right inset shows an amplified image of a very restrictive Vieussens valve impeding the progress of the guiding catheter. The lower inset shows two guidewires (arrows) aiding the advance of the lead. B. Non-selective angiography showing a very prominent Thebesian valve that impeded the advance of the guiding catheter tip. With the help of the second guidewire, it was finally possible to implant the lead in the target vein (previously identified by return venous angiography). Aiv indicates anterior interventricular vein; ThV, Thebesian valve

when a balloon was inflated in this area. The advance of the second guidewire, with the other still in place, allowed the valve to be opened, and the lead to be implanted. Figure 3 shows examples of obstacles associated with the target vein in which the double-wire technique was used (extreme tortuosity in the area of the origin of the vein, a pronounced angle at the origin of the target vein, and the presence of a restrictive venous valve at the origin of a large target vein). Table 2 shows a summary of the causes that made the use of the double-wire technique necessary.

The implantation of the lead in the target vein was possible after inserting a second hydrophilic guidewire in all 20 patients that required this technique. The amplitude of the local electrogram was 15.4 ± 7.9 mV, the stimulation threshold was 1.8 ± 1.2 V, and the

impedance 1089 ± 215.9 Ohms. Three patients showed phrenic stimulation with energies of above 8 V, but there was no need to relocate the lead since its stimulation threshold was <2 V. In 2 patients a small tattoo appeared after injecting the contrast medium, although this problem disappeared spontaneously within a few minutes and did not impede the implantation of the lead. No other complications were recorded during the procedure. At 21 months of follow-up (range, 6-37 months) all leads implanted were still in place.

DISCUSSION

Current evidence suggests that stimulation in the lateral region of the left ventricle is that which provides the greatest benefit in cardiac resynchronization therapy.¹³⁻¹⁶ However, different obstacles can appear in this region that impede the progress of the lead towards a target vein of adequate diameter and trajectory. These obstacles, which are often multiple, are identified by angiography and, in some cases (especially when they involve the Vieussens valve), can be inferred from the impossibility of progressing the system. In these situations, a second guidewire can be used after the impossibility of advancing the lead with the conventional technique is confirmed.²⁶

The size of the Thebesian valve in relation to the diameter of the coronary sinus ostium, as well as the presence of fenestrations, are the major difficulties in accessing the coronary venous system.²⁵ The presence of right atrial dilation along with dilation of the left ventricle adds a further degree of difficulty since the ostium is displaced away from the coronary sinus. The Vieussens valve, which is commonly associated with the presence of the oblique vein of Marshall, is another obstacle to progress the system since it must be crossed against the current.²⁴ Extreme tortuosity, a marked angle close to the origin of the vein, and/or a valve close to the origin of the target vein (all of which can be difficult to visualize by angiography) are other anatomical obstacles that can impede the progress of the guiding catheter and therefore prevent sufficient support being provided

TABLE 2. Reasons for Using the Double-Wire Technique (N=20)

Inadequate support provided by the guiding catheter	4 (20%)
Restrictive Vieussens valve	2 (10%)
Fenestrated Thebesian valve	2 (10%)
Target vein problems	20 (100%)
Tortuosity of the vein origin	5 (25%)
Angle of the origin of the vein	7 (35%)
Valve at the origin of the vein	8 (40%)
More than one cause	4 (20%)

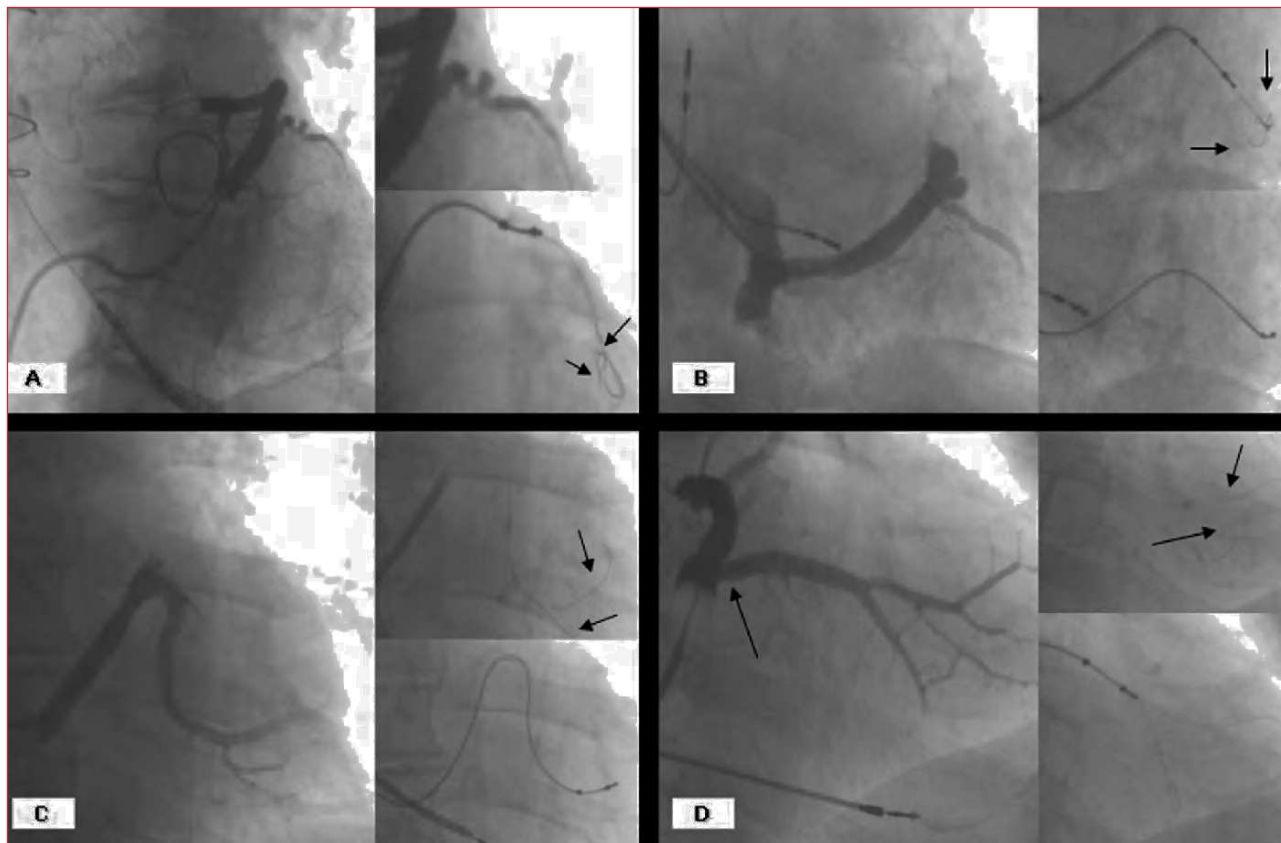


Figure 3. A. Occlusive coronary sinus venography showing a very tortuous target vein in which the double-wire technique (guidewires marked by arrows) permitted the advance of the lead. B. Pronounced tortuosity of a target vein in which implantation was possible thanks to the double-wire technique (see arrows). C. A very pronounced angle at the origin of the vein; this problem was also overcome with the use of the double-wire technique. D. The existence of a valve (arrow) at the origin of this large diameter vein was inferred; after being opened by the second guidewire (see arrows), the lead was able to advance.

to the lead.²⁶

The double-wire technique is a maneuver that has been used in the coronary arterial tree for other arteries for other purposes, such as the stabilization of a balloon in the treatment of intra-stent restenosis,²⁷ for advancing a coronary premounted stent in the case of complicated anatomy, and the protection of secondary branches in the treatment of bifurcations. It has also been used to facilitate navigation in other vascular areas, for example in the central nervous system.²⁸ However, in the coronary venous system its use has been described in only a single patient with a marked angle at the mouth of the target vein.²⁹

The advances made in the technology for implanting venous leads (better designed leads, guidewires and guiding catheters), and the greater experience of operators, now allow success rates of 90% to be achieved,^{3,18-22} although in at least 20% of cases implantation is laborious and requires the use of additional techniques.

In 169 of the 170 (99.4%) patients of the present study, the lead was successfully implanted in the left ventricle, although special techniques (the double-

wire technique, the push-and-pull technique, use of a balloon catheter, etc)³⁰ were required in some cases. In 1 patient (0.6%), extreme hypoplasia of the coronary sinus ostium prevented access to the coronary venous system.

This article describes a simple, safe and reproducible technique that allows different types of anatomical complication to be overcome when attempting lead implantation in the left ventricle. We exclusively use polymer-coated hydrophilic guidewires since these provide an appropriate platform for sliding the lead forward. We have never observed any deterioration of the lead due to friction caused by the second guidewire. Size 8 Fr catheters adequately allow the passage of the lead and guidewire while leaving sufficient residual volume for monitoring the procedure by selective injections of contrast medium (if required). The second guidewire should be controlled by another operator to prevent its excessive migration when advancing the lead.

In the future, the appearance of new guidewires may

allow the progression of the lead towards the target position with a reduced need for special maneuvers. However, for now, the double-wire technique is a useful tool that can aid in the implantation of a cardiac resynchronization device in patients with complicated venous anatomy.

CONCLUSIONS

The use of a second, parallel, hydrophilic guidewire (the double-wire technique) is a safe, efficient and reproducible procedure for implanting a left ventricular venous lead in patients with a target vein and/or coronary sinus showing complicated anatomy.

REFERENCES

- Crespo Leiro MG, Paniagua Martín MJ. [Management of advanced or refractory heart failure.] *Rev Esp Cardiol.* 2004;57:869-83.
- Massie BM, Shah NB. The heart failure epidemic: magnitude of the problem and potential mitigating approaches. *Curr Opin Cardiol.* 1996;11:221-6.
- Gras D, Leon A, Fisher WG. The Road to Successful CRT Implantation. A step-by-step approach. Westborough: Blackwell Futura; 2004.
- Boix Martínez R, Almazán Isla J, Medrano Albero MJ. Mortalidad por insuficiencia cardiaca en España, 1977-1998. *Rev Esp Cardiol.* 2002;55:219-26.
- Linde C, Braunschweig F, Gadler F, Bailleul C, Daubert J-C. Long-term improvements in quality of life by biventricular pacing in patients with chronic heart failure: results from the MULTISITE STimulation In Cardiomyopathy Study (MUSTIC). *J Am Coll Cardiol.* 2003;91:1090-5.
- Cazeau S, Leclercq C, Lavergne T, Walker S, Varma C, Linde C, et al. Effects of multisite biventricular pacing in patients with heart failure and intraventricular conduction delay. *N Engl J Med.* 2001;344:873-80.
- Abraham WT, Fisher WG, Smith AL, Delurgio DB, Leon AR, Loh E, et al. Cardiac resynchronization in chronic heart failure. *N Engl J Med.* 2002;346:1845-53.
- Young JB, Abraham WT, Smith AL, Leon AR, Lieberman R, Wilkoff B, et al. Combined cardiac resynchronization and implantable cardioversion defibrillation in advanced chronic heart failure: the MIRACLE ICD Trial. *JAMA.* 2003;289:2685-94.
- Auricchio A, Stellbrink C, Sack S, Block M, Vogt J, Bakker P, et al. Long-term clinical effect of hemodynamically optimized cardiac resynchronization therapy in patients with heart failure and ventricular conduction delay. *J Am Coll Cardiol.* 2002;39:2026.
- Bristow MR, Saxon LA, Boehmer J, Krueger S, Kass DA, de Marco T, et al. Cardiac-resynchronization therapy with or without an implantable defibrillator in advanced chronic heart failure. *N Engl J Med.* 2004;350:2140-50.
- Cleland JGF, Daubert JC, Erdmann E, Freemantle N, Gras D, Kappenberger L, et al. The effect of cardiac resynchronization on morbidity and mortality in heart failure. *N Engl J Med.* 2005;352:1539-49.
- Bradley DJ, Bradley EA, Baughman KL, Berger RD, Calkins H, Goodman SN, et al. Cardiac resynchronization and death from progressive heart failure: a meta-analysis of randomized controlled trials. *JAMA.* 2003;289:730-40.
- Burkhardt D, Oikawa RY, Sagawa K. Influence of pacing site on canine left ventricular contraction. *Am J Physiol.* 1986;251:H428-35.
- Auricchio A, Klein H, Tockman B, Sack S, Stellbrink C, Neuzner J, et al. Transvenous biventricular pacing for heart failure: can the obstacles be overcome? *Am J Cardiol.* 1999;83:136D-42D.
- Pappone C, Rosanio S, Oreto G, Tocchi M, Gulletta S, Salvati A, et al. Cardiac pacing in heart failure patients with left bundle branch block: impact of pacing site for optimizing left ventricular resynchronization. *Ital Heart J.* 2000;1:464-9.
- Rossillo A, Verma A, Saad EB, Corrado A, Gasparini G, Marrouche NF, et al. Impact of coronary sinus lead position on biventricular pacing. Mortality and echocardiographic evaluation during long-term follow-up. *J Cardiovasc Electrophysiol.* 2004;15:1120-5.
- Aranda JM Jr, Schofield RS, Leach D, Conti JB, Hill JA, Curtis AB. Ventricular dyssynchrony in dilated cardiomyopathy: the role of biventricular pacing in the treatment of congestive heart failure. *Clin Cardiol.* 2002;25:357-62.
- Leon AR. Practical issues in cardiac resynchronization therapy device implantation. *Rev Cardiovasc Med.* 2003;4:142-9.
- Kautzner J, Riedlbauchova L, Cihak R, Bytesnik J, Vancura V. Technical aspects of implantation of LV lead for cardiac resynchronization therapy in chronic heart failure. *Pacing Clin Electrophysiol.* 2004;27:783-90.
- Purerfellner H, Nesser HJ, Winter S, Schwierz T, Hornell H, Maertens S. Transvenous left ventricular lead implantation with the EASYTRAK lead system: the European experience. *Am J Cardiol.* 2000;86:157K-64K.
- Alonso C, Leclercq C, d'Allonnes FR, Pavin D, Victor F, Mabo P, et al. Six year experience of transvenous left ventricular lead implantation for permanent biventricular pacing in patients with advanced heart failure: technical aspects. *Heart.* 2001;86:40510.
- Leon AR, Abraham WT, Curtis AB, Daubert JP, Fisher WG, Gurley J, et al. Safety of Transvenous Cardiac Resynchronization System Implantation in Patients With Chronic Heart Failure: Combined Results of Over 2000 Patients From a Multicenter Study Program. *J Am Coll Cardiol.* 2005;46:2348-56.
- Worley SJ, Leon A, Wilkoff B. Anatomy and Implantation Techniques for Biventricular Devices. En: Ellenbogen KA, Kay GN, Wilkoff B, editors. *Device Therapy for Congestive Heart Failure.* Philadelphia, Pennsylvania: Elsevier Inc.; 2004. p. 118-231.
- Arbelo Lainez E, Medina Fernández-Aceytuno A, García Quintana A, Caballero Dorta E, Melián Nuez F, Delgado A, et al. Prevalencia de válvulas de Vieussens y válvulas venosas restrictivas en la desembocadura de la vena coronaria diana: observaciones anatómicas y angiográficas. *Rev Esp Cardiol.* 2005;58 Suppl 1:11.
- Arbelo Lainez E, Medina Fernández-Aceytuno A, Bolaños J, García Quintana A, Caballero Dorta E, Suárez de Lezo Herreros de Tejada J, et al. La válvula de Tebesio como determinante de la dificultad de acceso al seno coronario: observaciones anatómicas y angiográficas. *Rev Esp Cardiol.* 2004;57 Suppl 2:145.
- Medina Fernández-Aceytuno A, Arbelo Lainez E. Atlas de implante del electrodo venoso epicárdico. 1.a ed. Las Palmas de Gran Canaria: Idafe Estudio; 2005.
- Medina A, Hernández E, Suárez de Lezo J, Huertas R, Romero M, Pan M, et al. The importance of balloon stability and fractional flow reserve for the optimal management of instant restenosis. *Circulation.* 2001;107:3507.
- Lee TH, Choi CH, Park K-P, Sung SM, Lee SW, Lee B-H, et al. Techniques for Intracranial Stent Navigation in Patients with Tortuous Vessels. *AJNR Am J Neuroradiol.* 2005;26:1375-80.
- Chierchia GB, Geelen P, Rivero-Ayerza M, Brugada P. Double wire technique to catheterize sharply angulated coronary sinus branches in cardiac resynchronization therapy. *Pacing Clin Electrophysiol.* 2005;28:168-70.

30. Arbelo Lainez E, Caballero Dorta E, García Quintana A, Delgado A, Ortega Trujillo JR, Amador Gil C, et al. Resincronización cardíaca: necesidad de estrategias individualizadas para lograr una tasa de éxito elevada en el implante del electrodo en una vena coronaria. Rev Esp Cardiol. 2006;59 Suppl 2:50.