

ECG Contest

ECG, December 2015

ECG de diciembre de 2015

Carlos Antonio Álvarez-Ortega

Servicio de Cardiología, Hospital Universitario La Paz, Madrid, Spain



A 43-year-old man, originally from Ecuador, presented to his general practitioner with palpitations, denying symptoms of syncope or chest pain. He had a past history of untreated dyslipidemia and hypothyroidism on replacement therapy. His general practitioner performed an ECG with rhythm strip (Figures 1 and 2) and referred the patient for investigation to the regional cardiologist, who requested a 24-hour Holter (Figure 3) and transthoracic echocardiography (Figure 4), which showed mild ventricular dysfunction and an inferoposterior aneurysm.

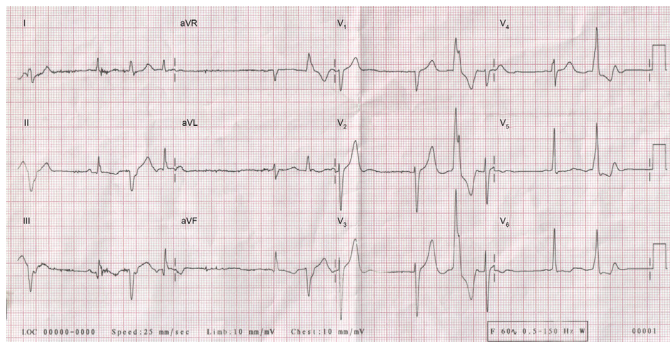


Figure 1.

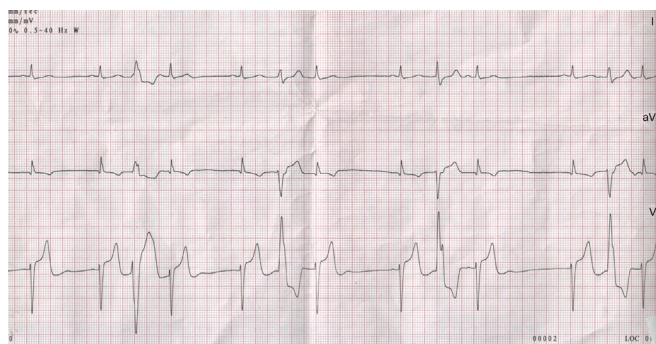


Figure 2.

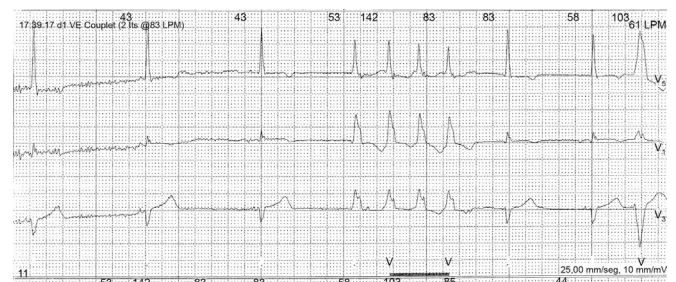


Figure 3.

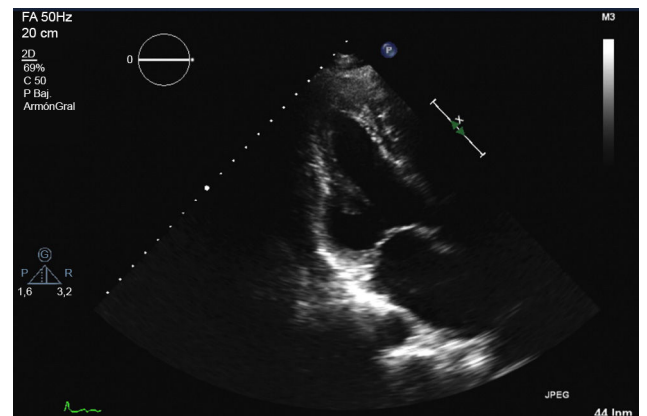


Figure 4.

Suggest a solution to this ECG Contest at <http://www.revespcardiol.org/es/electroreto/68/12> (only Spanish) The answer will be published in the next issue (January 2016). #RetoECG.

E-mail address: calvarezo@gmail.com

<http://dx.doi.org/10.1016/j.rec.2015.05.019>

1885-5857/© 2015 Sociedad Española de Cardiología. Published by Elsevier España, S.L.U. All rights reserved.