

## ECG Contest

## ECG, January 2016

## ECG de enero de 2016

Pablo Merás Colunga

Servicio de Cardiología, Hospital Universitario La Paz, Madrid, Spain



An 89-year-old woman, with a past history of arterial hypertension, Graves disease, and paroxysmal atrial fibrillation, with preserved ventricular function on her last echocardiogram, presented to the emergency department with palpitations, with good hemodynamic tolerance. On arrival, ECG 1 was performed (Figure 1). Shortly after, the tracing of ECG 2 was recorded (Figure 2).

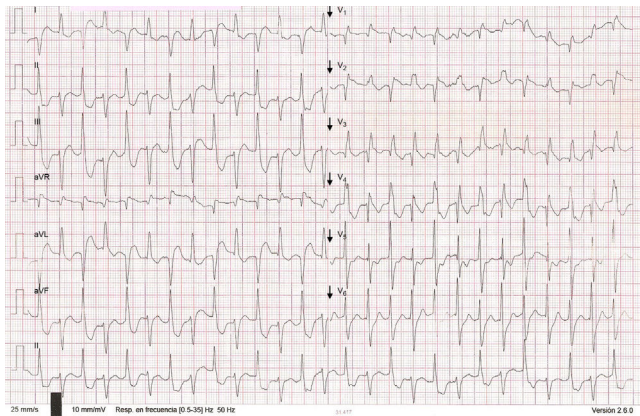


Figure 1.

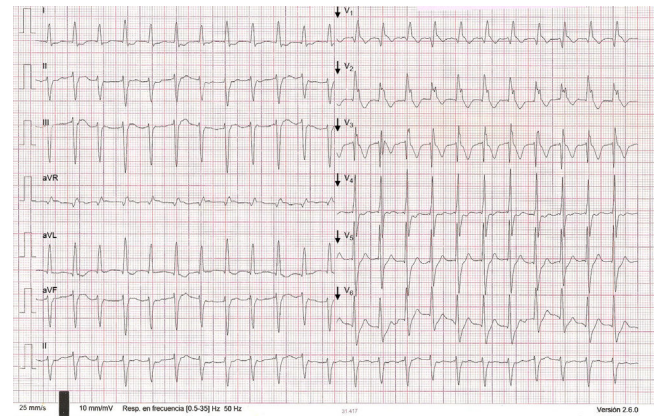


Figure 2.

Suggest a solution to this ECG Contest at <http://www.revespcardiol.org/es/electroreto/69/01> (only Spanish). The answer will be published in the next issue (February 2016). #RetoECG.

E-mail address: [merascolunga@gmail.com](mailto:merascolunga@gmail.com)