

## ECG Contest

## ECG, June 2016

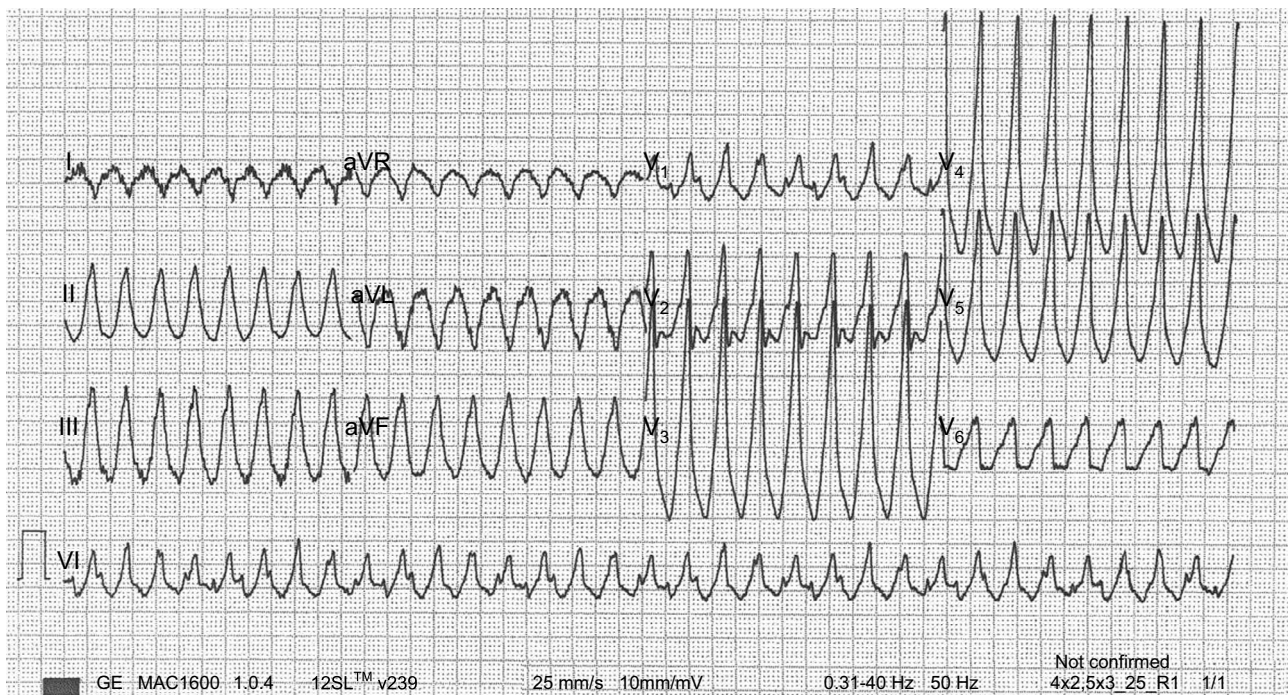


## ECG de junio de 2016

José Ángel Rodríguez-Fernández

Servicio de Cardiología, Hospital Universitario de A Coruña, A Coruña, Spain

The patient was an 81-year-old man who had undergone implantation of a mitral valve bioprosthesis for severe degenerative mitral regurgitation 2 years earlier. At the time of surgery, he was found to have moderate left ventricular systolic dysfunction (left ventricular ejection fraction of 40%); his coronary arteries were normal. He had no significant medical or surgery-related comorbidity. On this occasion, he had presented to the emergency department of his health area with a 15-day history of recurrent syncope. [Figure](#) shows the results of the ECG performed on his arrival at the emergency department. What arrhythmias does the patient have?



**Figure.**

Suggest a solution to this ECG Contest at <http://www.revespcardiol.org/es/electroreto/69/06> (only Spanish). The answer will be published in the next issue (July 2016). #RetoECG.