

## ECG Contest

## ECG, June 2019

## ECG de junio de 2019

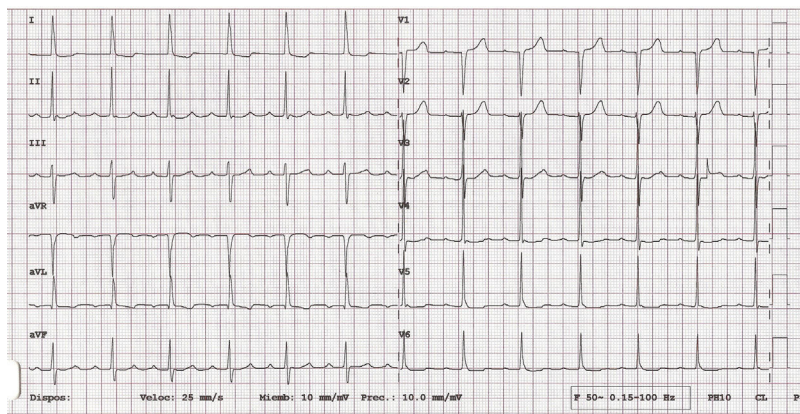


Gonzalo Fernández Palacios,<sup>a,b,\*</sup> Pablo Elpidio García-Granja,<sup>a,b</sup> and David Dobarro<sup>a,b</sup>

<sup>a</sup> Instituto de Ciencias del Corazón (ICICOR), Hospital Clínico Universitario de Valladolid, Valladolid, Spain

<sup>b</sup> Centro de Investigación Biomédica en Red de Enfermedades Cardiovasculares (CIBER-CV), Madrid, Spain

We present the case of a 70-year-old woman with hypertension and a history of paroxysmal episodes of palpitations for which she occasionally took bisoprolol. She suddenly had an episode of palpitations of greater severity and duration than previous ones, which were accompanied by dizziness and precordial oppression. The patient took 5 mg of bisoprolol and attended the emergency room. On arrival, she no longer had any cardiac symptoms and was hemodynamically stable. Chest X-ray and blood work were normal. Her electrocardiogram is shown in [Figure 1](#).



**Figure 1.**

What is the most appropriate approach to the immediate diagnostic process in this patient?

1. Electrocardiographic monitoring for 12 hours in the emergency room
2. Carotid sinus massage
3. Electrophysiological study
4. 24-hour outpatient Holter study

Submit your answer to <http://www.revespcardiol.org/en/electroreto/72/06>. The solution will be published in the next issue (July 2019). #ECGChallenge #RetoECG.

\* Corresponding author:  
E-mail address: [gfpalacios@hotmail.com](mailto:gfpalacios@hotmail.com) (G. Fernández Palacios).