

ECG Contest

ECG, March 2015



ECG de marzo de 2015

Albert Durán Cambra

Servicio de Cardiología, Hospital de la Santa Creu i Sant Pau, Barcelona, Spain

While at work, a 60-year-old man, former smoker with hypertension and dyslipidemia, experiences an onset of oppressive chest pain with sweating, nausea, and dizziness, and contacts the medical emergency system. At 15 minutes, pain persists, arterial pressure is 150/70 mmHg and heart rate was 110 bpm. Electrocardiography is performed (Figure). What would be your main suspected diagnosis and therapeutic approach?

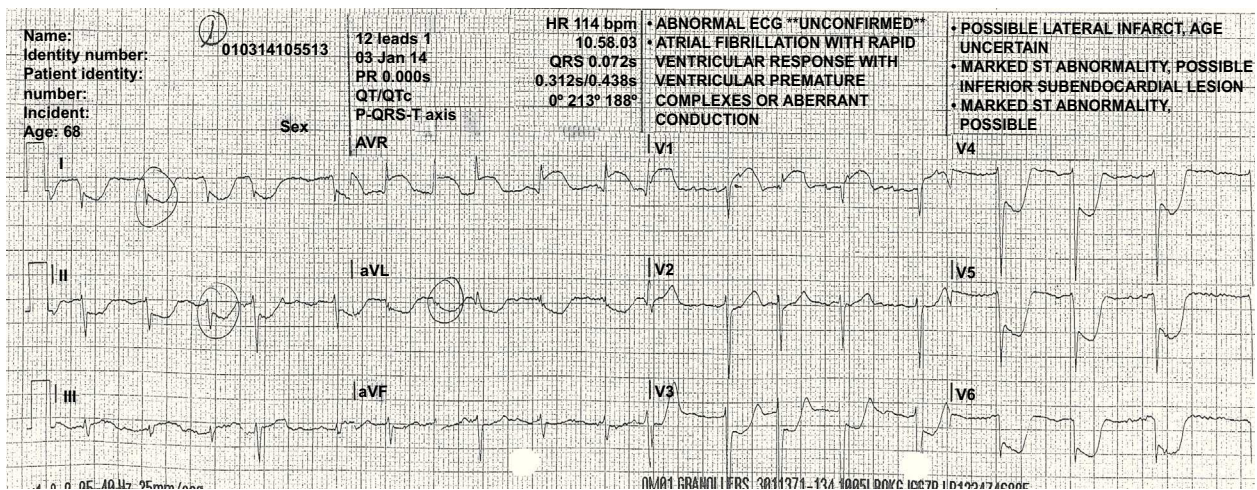


Figure.

Suggest a solution to this ECG Contest at <http://www.revespcardiologia.org/es/electroreto/68/03> (only Spanish). The answer will be published in the next issue (April 2015). # RetoECG.