

## ECG Contest

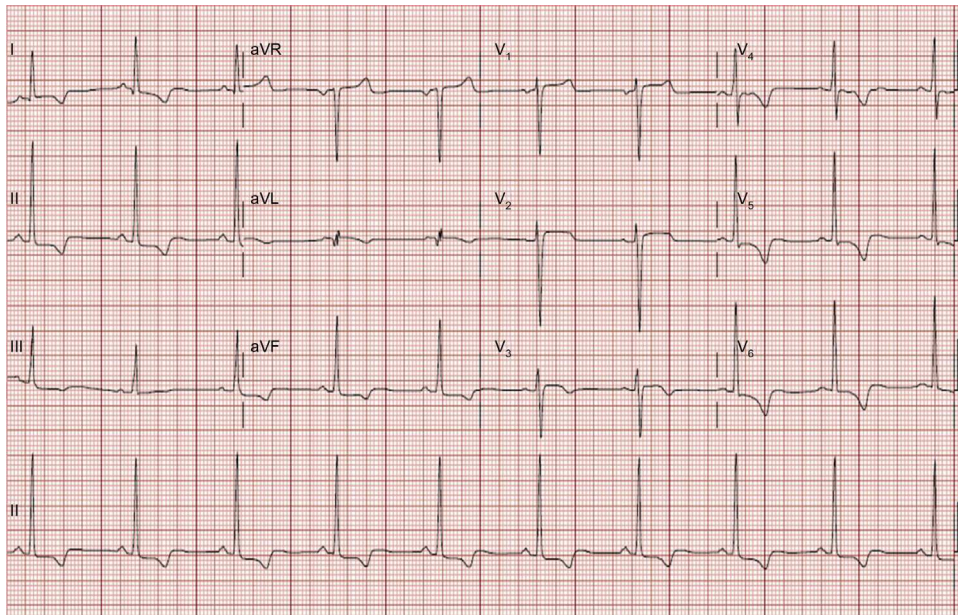
## ECG, May 2015

## ECG de mayo de 2015

Pablo García-Pavía

*Unidad de Insuficiencia Cardíaca y Cardiopatías Familiares, Servicio de Cardiología, Hospital Universitario Puerta de Hierro, Madrid, Spain*

A 53-year-old woman without cardiovascular risk factors consulted for dyspnea on moderate exertion. She reported no further symptoms. She had blood pressure of 130/75 mmHg and no edema or other signs of congestion. She had no skin lesions or muscular weakness, although she reported that “exertion was difficult”. Her mother died at 68 years of age after a stroke and a brother received a kidney transplant at 42. Both were told that they had “cardiac hypertrophy”. A maternal aunt is hypertensive, has mild concentric ventricular hypertrophy, and required a pacemaker at 60 years of age. This is the ECG obtained in the clinic (Figure). What would your diagnosis be?

**Figure.**

Suggest a solution to this ECG Contest at <http://www.revespcardiologia.org/es/electroreto/68/05> (only Spanish). The answer will be published in the next issue (June 2015). # RetoECG.

E-mail address: [pablogpavia@yahoo.es](mailto:pablogpavia@yahoo.es)

<http://dx.doi.org/10.1016/j.rec.2014.08.020>

1885-5857/© 2014 Sociedad Española de Cardiología. Published by Elsevier España, S.L.U. All rights reserved.