

ECG Contest

ECG, November 2014



ECG de noviembre de 2014

Juan Carlos García-Rubira

Unidad de Gestión de Cardiología, Hospitales Universitarios Virgen Macarena–Virgen del Rocío, Sevilla, Spain

The patient was a 53-year-old man who was receiving angiotensin-converting enzyme inhibitors for hypertension, smoked 20 cigarettes a day, and requested emergency care because of chest pain. He explained that he had been coughing more than usual for a week and that, at times, the cough was accompanied by a certain degree of pain. His cough was nearly unproductive, and the few secretions produced were whitish. He did not have fever. That morning, while he was getting dressed for work, he felt severe pain in the center of his chest, which continued to intensify. He found it difficult to breathe and experienced general malaise, nausea, and profuse sweating. The electrocardiogram (Figure) was performed 2 and a half hours after symptom onset.

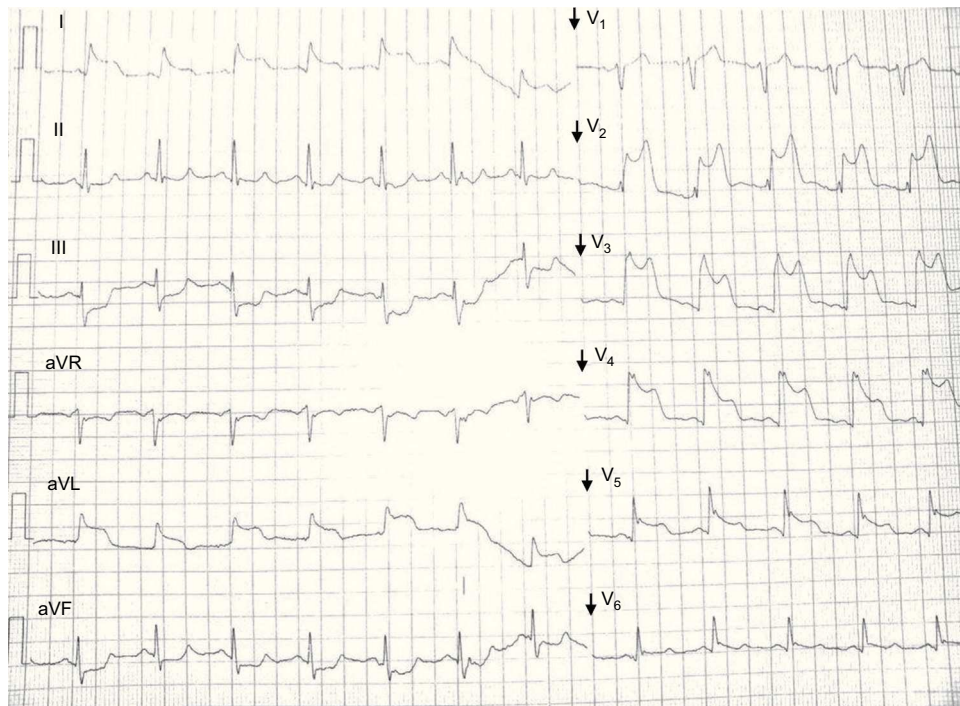


Figure.

Suggest a solution to this ECG Contest at <http://www.revespcardiol.org/es/electroreto/67/11> (only Spanish) #ECGNOV14. The answer will be published in the next issue (December 2014).