

ECG Contest

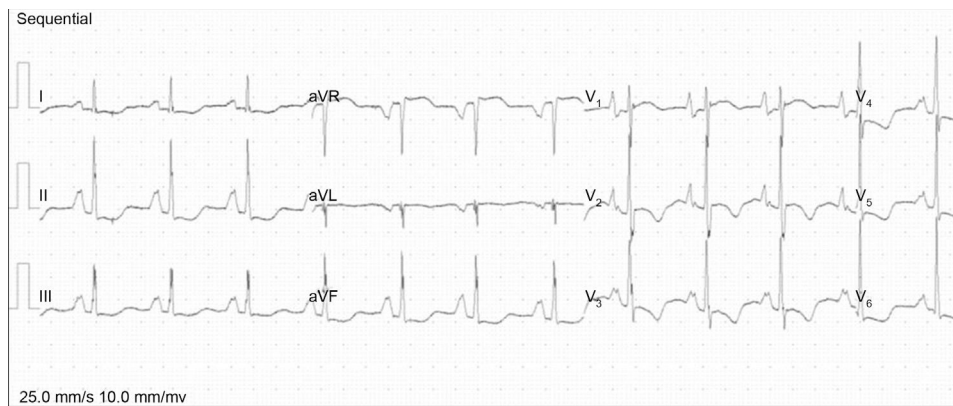
ECG, November 2015

ECG de noviembre de 2015

Sonia Mirabet

Servicio de Cardiología, Área de Miocardiopatías, Unidad de Insuficiencia Cardíaca y Trasplante Cardíaco, Hospital de Sant Pau, Barcelona, Spain

A 25-year-old woman, in active employment, with no history of substance abuse, and no reported past medical history of note. Her father died of a heart condition 13 years before. There was no family history of heart disease or sudden death. She reported 2 months of progressive exertional dyspnea, inability to lie flat, and abdominal distention. On examination, heart sounds were regular, with a fourth heart sound, a grade 2/6 systolic murmur in the tricuspid area, significant jugular venous distention, tender hepatomegaly of 2 fingerbreadths, and signs of mild ascites. Her ECG is shown in the [Figure](#). What would the diagnosis be?

**Figure.**

Suggest a solution to this ECG Contest at <http://www.revespcardiologia.org/es/electroreto/68/11> (only Spanish). The answer will be published in the next issue (December 2015). #RetoECG.

E-mail address: smirabet@santpau.cat