

ECG contest

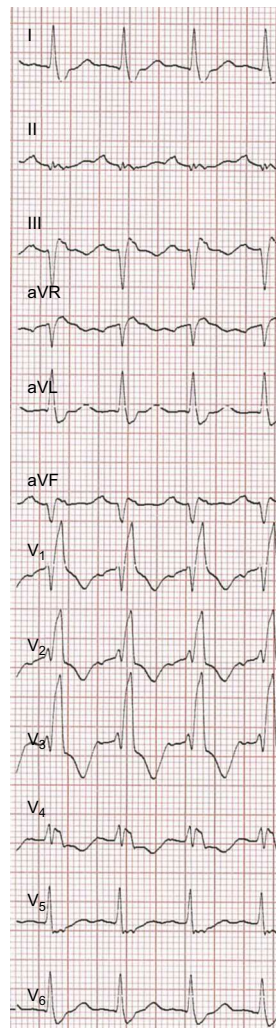
ECG, September 2015

ECG de septiembre de 2015

Manuel Martínez-Sellés

Departamento de Cardiología, Hospital Universitario Gregorio Marañón, Universidad Europea y Universidad Complutense, Madrid, Spain

An 80-year old man with no cardiovascular risk factors or past medical history of note, other than prostate cancer in complete remission, had a sudden cardiac arrest, with an initial nonshockable rhythm. Resuscitation was performed for 4 minutes, with spontaneous return of circulation, followed by intubation and transfer to our center, where blood pressure was 146/64 mmHg and heart rate was 123 bpm on arrival. He was admitted to the cardiac intensive care unit, where, based on the clinical picture and ECG, the team decided on the next investigation and subsequent plan (Figure).

**Figure.**

Suggest a solution to this ECG Contest at <http://www.revespcardiologia.org/es/electroreito/68/09> (only Spanish). The answer will be published in the next issue (October 2015). #RetoECG.

E-mail address: mmselles@secardiologia.es

<http://dx.doi.org/10.1016/j.rec.2015.04.013>

1885-5857/© 2015 Sociedad Española de Cardiología. Published by Elsevier España, S.L.U. All rights reserved.