

Image in cardiology

Eco-X Ray Fusion for Transseptal Puncture



Fusión eco-escopia, una ayuda durante la punción transeptal

Ariana González Gómez,* Rosana Hernández-Antolín, and José L. Zamorano

Servicio de Cardiología, Hospital Universitario Ramón y Cajal, Madrid, Spain

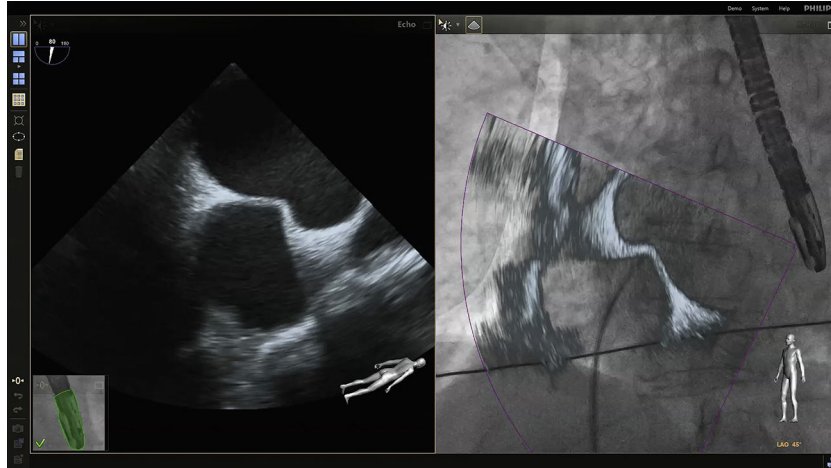


Figure.

In recent years, percutaneous procedures have been used increasingly to correct structural heart disease. Many of these procedures require transseptal puncture to access the left heart chambers, although complications such as cardiac tamponade and aortic perforation may occur. In certain situations, puncture of the atrial septum is required (for placement of a MitraClip device or closure of the left atrial appendage, for example). Fluoroscopy imaging cannot adequately display the position of anatomic landmarks, and often echocardiographic imaging is needed to guide puncture. An innovative system (EchoNavigator System, Philips) is now available. This system allows X-ray images and echocardiographic images to be combined in 2 or 3 dimensions in real time. The movement of the X-ray arc is synchronized with the transesophageal probe of the echocardiogram, and the different echocardiographic projections are sliced according to the position of the X-ray source. In the [Figure](#), the transducer of the transesophageal echocardiography system, shown in green, indicates the appropriate synchronization of the echocardiogram and X-ray image. The echocardiographic image during transseptal puncture is shown on the left. On the right, we see how the echocardiographic image is combined on the X-ray image in real time using the EchoNavigator system, thereby helping to guide the puncture procedure. This tool allows different types of image to be superimposed to facilitate the intervention and improve the safety of the procedure.

* Corresponding author:
E-mail address: arianaglz@hotmail.com (A. González Gómez).
Available online 28 January 2015