

# Electrocardiographic Prediction of the Site of Lesion in the Anterior Descending Artery in Acute Myocardial Infarction

José A. Prieto Solís<sup>a</sup>, Camilo González Fernández<sup>a</sup>, Miguel A. Hernández Hernández<sup>a</sup>, José M. de la Torre Hernández<sup>b</sup> and Javier Llorca Díaz<sup>c</sup>

<sup>a</sup>Unidad Coronaria y <sup>b</sup>Sección de Hemodinámica. Hospital Marqués de Valdecilla. Santander. España.

<sup>c</sup>Área de Medicina Preventiva y Salud Pública. Facultad de Medicina. Universidad de Cantabria. Santander. España.

**Introduction and objectives.** The goal of this study was to analyze the value of electrocardiography in predicting the site of the lesion in the left anterior descending coronary artery, in relation to the first septal and the first diagonal branches, in patients with acute anterior myocardial infarction.

**Method.** Ninety consecutive patients who were admitted to the coronary unit with acute anterior myocardial infarction from July 1998 to May 2000 were studied retrospectively. The electrocardiographic changes were analyzed and correlated with the site of the lesion in the anterior descending artery, as determined by coronary angiography.

**Results.** The most useful parameters in predicting the site of the lesion in the left anterior descending coronary artery in acute anterior myocardial infarction are: 1) For lesions proximal to the first septal branch, ST-segment elevation in aVR ( $p < 0.001$ ) and the absence of Q wave in V4-V6 ( $p = 0.01$ ). 2) For lesions proximal to the first diagonal branch, abnormal Q wave in aVL ( $p = 0.01$ ) and ST depression in III ( $p = 0.05$ ). 3) For lesions proximal to both the first septal and first diagonal branches, ST elevation in aVR ( $p < 0.001$ ), abnormal Q wave in aVL ( $p = 0.02$ ), and absence of Q wave in V4-V6 ( $p = 0.01$ ). 4) For lesions distal to both the first septal and first diagonal branches, abnormal Q wave in V4-V6 ( $p = 0.001$ ) and absence of ST depression in III ( $p < 0.001$ ).

**Conclusions.** In acute anterior myocardial infarction, electrocardiography is useful for predicting the site of the lesion in the left anterior descending coronary artery in relation to the first septal and the first diagonal branches.

**Key words:** Myocardial infarction. Coronary artery disease. Electrocardiography.

Full English text available at: [www.revespcardiol.org](http://www.revespcardiol.org)

## Predicción electrocardiográfica de la localización de la lesión en la arteria descendente anterior en el infarto agudo de miocardio

**Introducción y objetivos.** El objetivo de este estudio es analizar el valor del electrocardiograma (ECG) en la predicción del lugar de la lesión en la arteria descendente anterior, en relación a sus ramas primera septal y primera diagonal, en pacientes con infarto agudo de miocardio anterior.

**Método.** Se analiza de forma retrospectiva a 90 pacientes con infarto agudo de miocardio anterior ingresados consecutivamente en la Unidad Coronaria, desde julio de 1998 a mayo de 2000. Se estudian los cambios electrocardiográficos y se correlacionan con el lugar de la lesión de la arteria descendente anterior determinada por angiografía coronaria.

**Resultados.** Los parámetros más útiles para predecir el lugar de la lesión de la arteria descendente anterior en el infarto agudo de miocardio anterior son: a) para la lesión proximal a la primera septal: la elevación del segmento ST en aVR ( $p < 0.001$ ), y la ausencia de onda Q en V4-V6 ( $p = 0.01$ ); b) para la lesión proximal a la primera diagonal: la presencia de ondas Q anormales en aVL ( $p = 0.01$ ) y el descenso del ST en III ( $p = 0.05$ ); c) para la lesión proximal a ambas ramas, primera septal y primera diagonal: la elevación del ST en aVR ( $p < 0.001$ ), onda Q anormal en aVL ( $p = 0.02$ ) y ausencia de Q en V4-V6 ( $p = 0.01$ ), y d) para la lesión distal a ambas ramas: la presencia de onda Q en V4-V6 ( $p = 0.001$ ) y ausencia de descenso del ST en III ( $p < 0.001$ ).

**Conclusiones.** En el infarto agudo de miocardio anterior, el ECG es útil para predecir el lugar de la lesión de la arteria descendente anterior en relación con sus ramas primera septal y primera diagonal.

**Palabras clave:** Infarto de miocardio. Enfermedad coronaria. Electrocardiografía.

SEE EDITORIAL ON PAGES 1015-7

Correspondence: Dr. José Antonio Prieto Solís.  
Unidad Coronaria. Hospital Marqués de Valdecilla.  
Avda. de Valdecilla, s/n. 39008 Santander. España.  
E-mail: [ucopsj@humv.es](mailto:ucopsj@humv.es)

Received 17 August 2001.

Accepted for publication 1 April 2002.

## INTRODUCTION

The widespread and beneficial use of reperfusion therapy for acute myocardial infarction (AMI)<sup>1</sup> makes it essential to establish the location of the lesion responsible for the infarct prior to initiating treatment.<sup>2</sup> In anterior AMIs, location of the lesion in the anterior

## ABBREVIATIONS

ECG: electrocardiogram  
AMI: acute myocardial infarction  
AD: anterior descending  
1S: first septal  
1D: first diagonal  
IC: confidence interval

descending artery (AD) has been associated with the amount of myocardial necrosis and patient prognosis.<sup>3,4</sup> An acute proximal obstruction of the AD artery habitually causes extensive necrosis that is frequently accompanied by hemodynamic deterioration.<sup>2</sup> Therefore, early localization of the anatomical site of the arterial lesion can be useful in evaluating myocardial risk and in selecting the therapeutic strategy to be used.<sup>5</sup>

In recent years, frequent studies have appeared in the medical literature that aim to determine which electrocardiographic features allow identification of the artery responsible for the AMI and the location of the arterial lesion.<sup>2,5-14</sup>

Our study aims to evaluate various electrocardiographic criteria used for predicting the location of the DA artery lesion in terms of its first septal (1S) and first diagonal (1D) branches in patients with anterior AMIs.

## METHODS

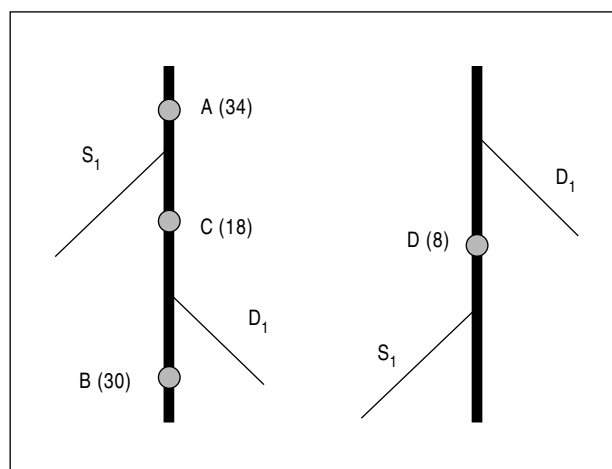
### Patients

We studied retrospectively 90 patients admitted consecutively to the Coronary Unit between July, 1998, and May, 2000, who had anterior AMI. The diagnosis was established by the presence of chest pain for more than 30 minutes accompanied by an ST segment elevation equal to or greater than 2 mm in leads V2 and V3, and confirmed by clinical enzyme values.

The study protocol included patients with anterior AMI admitted within 6 hours of the start of chest pain. Patients with a previous diagnosis of myocardial infarction, valve disease, myocardial disease and left branch block were excluded from the study. Patients who had undergone myocardial revascularization surgery and those who developed epistemic pericarditis were also excluded. Electrocardiographic and angiographic evaluations were performed by different researchers.

### Electrocardiography studies

All patients with anterior AMI underwent a conventional 12-lead electrocardiogram (ECG) upon admission to the Coronary Unit and this was repeated daily



**Fig. 1.** Graphic of the various types of AD artery lesions. A indicates lesion proximal to 1S+1D; B, lesion distal to 1S+1D; C, lesion distal to 1S and proximal to 1D; D, lesion distal to 1D and proximal to 1S; 1D, first diagonal; 1S, first septal.

for the first 3 days and subsequently any time the patient developed an episode of angina during their stay.

ST segment deviation was measured at 40 ms from point J. Of the various ECGs performed during the first 3 days, the one that showed the greatest changes was used for the study (usually the ECG performed upon admission).

By definition we included in the study those patients with an ST segment elevation  $\geq 2$  mm in leads V2 and V3. In the rest of the leads, an elevation or decrease was considered significant if it was  $>0.5$  mm. The presence of a Q-wave with an amplitude  $\geq 30$  ms was considered abnormal.<sup>15</sup>

The conduction disturbances that occurred during the development of the acute phase (the first 3 days) were also evaluated.

### Coronary angiography

All patients underwent coronary angiography within the first 2 weeks after the infarct: 81 patients within the first 3 days, with a mean of 1.1 days between the electrocardiography recording and angiography, and the 9 remaining patients between day 7 and day 15 after the beginning of the acute episode, with a mean of 9.2 days. The arterial lesion was considered significant when it produced a reduction in lumen size of 70%. The lesion that was identified as responsible for the necrosis was the most serious AD artery lesion, the lesion with local dissection, or the lesion with angiographic characteristics of residual thrombus or ulcerated plaque, or any combination of the three. We determined the location of the lesion with regard to its 1S or 1D branch outlets, grouping the lesions into 4 types (Figure 1): a) lesions proximal to both the 1S and 1D branches; b) lesions distal to both the 1S and 1D branches;

ches; c) lesions distal to 1S and proximal to 1D, and d) lesions distal to 1D and proximal to 1S.

### Statistical study

The data were analyzed with the Stata package, version 6 (Stata Corporation, College Station, Texas). The crude odds ratio (OR) was calculated for each variable (95% confidence interval [CI]) by logistical regression analysis, as well as OR adjusted by multivariate step-by-step logistical regression analysis. Beginning study criteria was  $P < .10$  and end of study criteria was  $P < .15$ . An ROC curve was created for each multivariate logistical regression model.

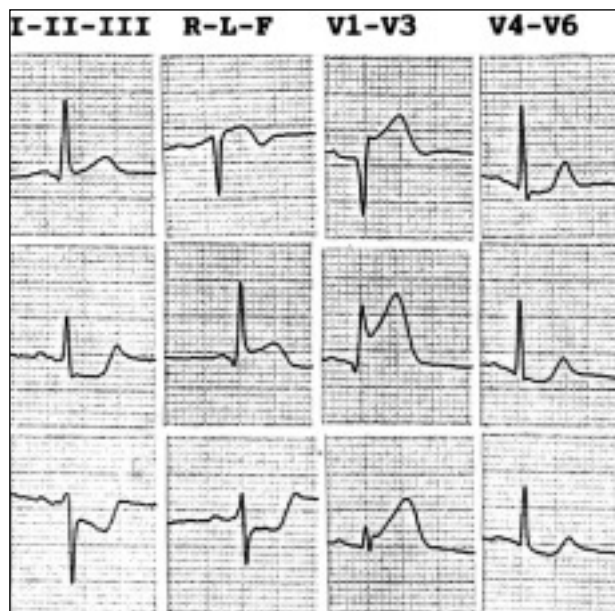
Electrocardiographic changes for the various types of lesions were analyzed and compared. Calculations were not performed for lesions distal to 1S and 1D because the values obtained would have been the same for the respective proximal lesions, but opposite.

For comparison of the continuous variables, we used the Mann-Whitney  $U$  test, and the exact Fisher test for the comparison of proportional variables. A value of  $P < .05$  was considered statistically significant.

### RESULTS

Basic patient data are shown in Table 1.

Of the 90 patients studied, 34 (37.7%) showed a lesion of the AD artery proximal to both the 1S and 1D branches (Figure 1A); in 30 patients (33.3%) the lesion was distal to 1S and 1D (Figure 1B); in 18 patients (20%) it was distal to 1S and proximal to 1D (Figure 1C), and in 8 patients (8.8%) the lesion was



**Fig. 2.** ECG of a patient with anterior AMI caused by lesion proximal to the first septal and first diagonal arteries. An ST segment elevation is observed in lead aVR, as is an ST depression of the inferior face, a Q-wave in lead aVL, and the absence of Q-wave in leads V4 through V6. AMI indicates acute myocardial infarction.

proximal to 1S and distal to 1D (Figure 1D) (in the latter, the 1S branch exited under the D1 branch).

The total number of patients with a lesion proximal to the 1S branch was 42 (34+8), and with a distal lesion was 48 (30+18). The total number of patients with a lesion proximal to the 1D branch was 52 (34+18) and with a distal lesion was 38 (30+8) (Figure 1).

### Lesion proximal to 1S (Figure 1 A+D)

The ST segment elevation in I is not useful for differentiating the proximal 1S (A+D) lesion from the distal (B+C) lesion, as its prevalence is similar in both cases. An ST segment elevation was present in the lead aVL in 90.4% of patients with proximal lesions and in 70.8% of patients with distal lesions ( $P = .03$ ).

In lead aVR, ST elevation occurred in 69.0% of the lesions proximal to 1S and in 2.0% of the distal lesions ( $P < .001$ ).

In leads II, III, and aVF, ST depression occurred in 66.6%, 73.8%, and 76.1% of the proximal lesions, respectively, and in 27.0% ( $P < .001$ ), 41.6% ( $P = .004$ ), and 41.6% ( $P = .001$ ) of the distal lesions, respectively.

As far as the precordial leads were concerned, only the absence of ST segment elevation in lead V6 was shown to be a significant marker for lesions proximal to 1S.

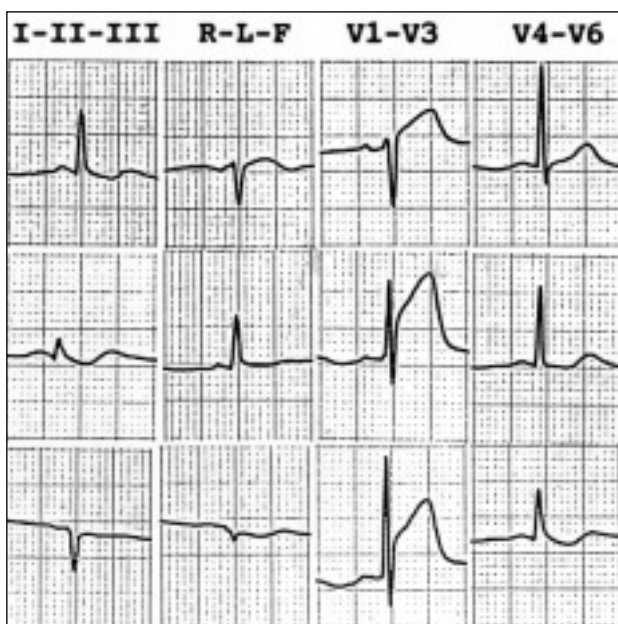
The presence of Q-waves in leads V4 through V6 was observed in 2.3% of the proximal lesions and in 52. % of the distal lesions ( $P = .001$ ).

The presence of an association between a right branch block and an anterior hemiblock occurred in

**TABLE 1. Clinical characteristics**

Variables	Number
Age, years	57 (35-82)
Men	64 (71.1%)
Previous angina	29 (32.2%)
Hypertension	39 (43.3%)
Hypercholesterolemia	36 (40%)
Diabetes	21 (23.3%)
Smokers	26 (28.8%)
Thrombolysis	30 (33.3%)
Primary angioplasty	53 (58.8%)
CK peak, U/L	2939 (365-6950)
Cardiac insufficiency	14 (15.5%)
Time of ECG recording ECG, h	1.9 (0.1-6.5)
Sinus rhythm	78 (86.6%)
Conduction disturbances	40 (44.4%)
Percentage of AD lesion	98 (70-100)
Right coronary lesion	12 (13.3%)
Circumflex lesion	9 (10%)
RC and CX lesion	8 (8.8%)
Left trunk lesion	0

RC indicates right coronary; CK, creatin kinase; CX, circumflex; AD, anterior descending.



**Fig. 3.** ECG of a patient with an anterior AMI due to a lesion proximal to the first septal artery and distal to the first diagonal artery. ST segment elevation is seen in lead aVR, and the absence of a pathological Q-wave in lead aVL and leads V4 through V6 is noted. AMI indicates acute myocardial infarction.

19% of patients with proximal lesions and only in 2.08% (1 patient) of patients who had distal lesions ( $P=.02$ ).

In the multivariate study, lead aVR ST segment elevation and the absence of Q-waves in leads V4 through V6 were shown to be the most useful markers for a lesion proximal to 1S; a lead aVR ST segment elevation showed an OR of 214.74 ( $P<.001$ ) (Table 2, Figures 2 and 3).

### Lesion proximal to 1D (Figure 1, A+C)

An ST segment elevation in lead I was observed in 69.2% of patients with lesions proximal to 1D and in 44.7% of patients who presented with a distal lesion ( $P=.03$ ). An ST segment elevation in lead aVL was present in 94.2% of patients with proximal lesions and in 60.5% of patients with distal lesions ( $P<.001$ ).

An ST segment elevation was observed in 50% of patients with proximal lesions and in 13.1% of patients with distal lesions ( $P<.001$ ).

An ST segment depression in leads II was observed in 63.4% of patients, III, in 75% of patients and aVF, in 76.9% of patients with proximal lesions and in 23.6% ( $P<.001$ ), 31.5% ( $P<.001$ ), and 31.5% ( $P<.001$ ), respectively. The presence of Q-waves in lead aVL occurred in 48.07% of patients with proximal lesions and in 18.2% of patients with distal lesions ( $P=.07$ ). An abnormal Q-wave in leads V4-V6 occurred more frequently in patients with distal lesions than in patients with proximal lesions (44.7% and 15.3%, respectively) ( $P=.004$ ).

Conduction disturbances were useful in differentiating the extent of lesions. In the multivariate study, the presence of Q-waves in lead aVL Q-waves and ST segment depression in lead III were the most useful parameters for predicting lesions proximal to the first diagonal artery (Table 2, Figures 2 and 4).

### Lesion proximal to 1S+1D (Figure 1, A)

In lead I there was a similar prevalence of ST segment elevation for proximal lesions of both branches (type A) and the rest of the lesion types (types B, C, and D) ( $P=.8$ ). In lead aVL the prevalence of ST segment elevation for type A was 94.1%, vs 71.4% for the remainder of lesions ( $P=.01$ ).

**TABLE 2. Electrocardiography markers for AD artery lesions**

Markers for lesions proximal to 1S			
Regression-adjusted odds ratio			
Variables	Logistical	95% CI	P
ST elevation in lead aVR	214.74	18.17-2538.4	<.001
No ST elevation in lead V6	51.43	0.76-38.82	.09
No Q-wave in leads V4-V6	89.26	2.57-3096.49	.01
ST elevation in lead V5	10.91	1.53-77.54	.02
Area under the ROC curve:0.9588			
Markers of lesion proximal to 1D			
Q-wave in lead aVL	4.32	1.34-13.89	.01
ST depression in lead III	3.15	0.99-9.98	.05
ST elevation in lead aVR	3.21	0.83-12.37	.09
ST segment elevation in lead I	2.80	0.85-9.21	.09
No Q-wave in leads V4-V6	2.96	0.83-10.62	.09
Area under the ROC curve:0.8451			

1D indicates first diagonal; AD, anterior descending; CI, confidence interval; 1S, first septal.

In lead aVR, ST segment elevation for type A lesions was 70.5% vs 10.7% for the remaining lesion types ( $P<.001$ ).

ST segment depression in leads II, III, and aVF occurred more frequently in type A lesions than in the other types of lesions (67.6% for leads II; [ $P=.002$ ], 73.5% for leads III [ $P=.02$ ], and 76.4% for leads III [ $P=.009$ ]).

Pathological Q-waves in lead aVL occurred in 47.0% of type A lesions and in 28.5% of the remaining types of lesions. In leads V4 through V6, pathological Q-waves were observed in only 2.9% (1 patient) of type A lesions vs 44.6% in the other types of lesions ( $P=.001$ ). Anterior hemiblock was seen in 52.9% of type A lesions vs 23.2% of the remaining types of lesions ( $P=.008$ ).

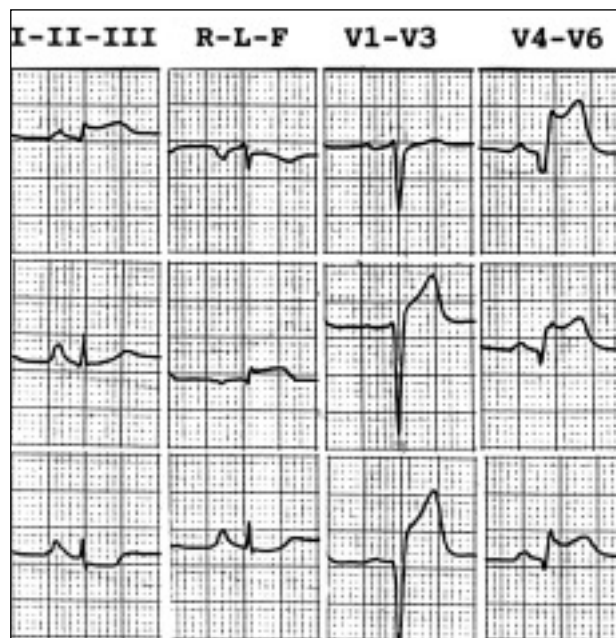
In the multivariate study, ST segment elevation in lead aVR, together with the presence of Q-waves in lead aVL and the absence of Q-waves in leads V4 through V6 were the most useful markers for predicting proximal lesions of both branches (Table 3, Figure 3).

### Lesion distal to 1S+1D (Figure 1, B)

ST segment changes in leads I and aVL were not shown to be useful markers for lesions distal to both branches (type B lesions). In lead aVR no patient with a type B lesion showed an elevation of the ST segment, compared with 50% of patients with other types of lesions (A+C+D) ( $P<.001$ ) who did.

In the inferior leads, ST segment depression in leads III and aVF was 20%, compared with 75% ( $P<.001$ ) and 76.6% ( $P<.001$ ), respectively, for the rest of the lesion types.

The presence of Q-waves in leads V4 through V6 occurred in 56.6% of patients with type B lesions,



**Fig. 4.** ECG of a patient with anterior AMI resulting from a lesion distal to the first septal artery and proximal to the first diagonal artery. The absence of ST segment elevation in lead aVR, Q-wave in leads V4-6, Q-wave in lead aVL, and ST depression in lead III is notable. AMI indicates acute myocardial infarction.

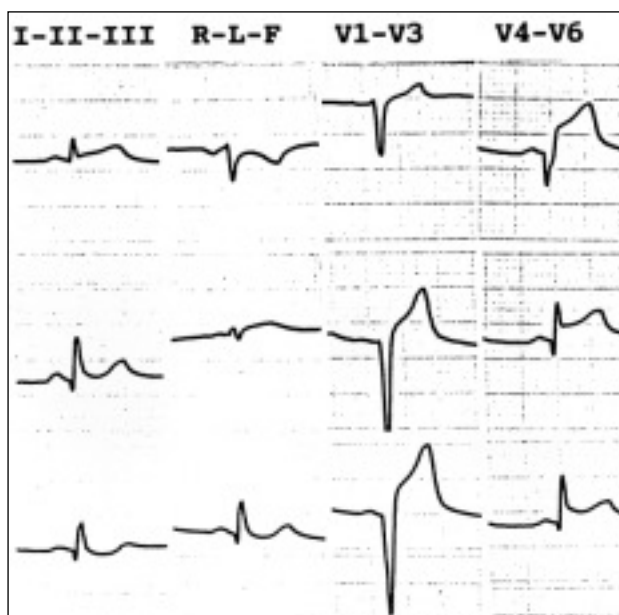
compared with 15% of patients with the remaining types of lesions ( $P<.001$ ). Conduction disturbances were not useful markers for locating type B lesions.

On multivariate analysis, the absence of ST segment depression and in leads III and aVF and the presence of Q-waves in V4-V6 were shown to be the most useful markers for locating distal lesions in both 1S and 1D branches (Table 3, Figure 5).

**TABLE 3. Electrocardiography markers for AD artery lesions**

Markers for lesions proximal to 1S+1D			
Regression-adjusted odds ratio			
Variables	Logistical	95% CI	P
ST elevation in lead aVR	25.58	5.72-114.37	<.001
Q-wave in lead aVL	5.19	1.37-19.65	.02
No Q-wave in leads V4-V6	27.30	1.97-378.43	.01
ST segment elevation in lead V5	3.75	0.82-17.18	.09
Area below the ROC curve:0.9081			
Markers for lesions distal to 1S+1D			
Q-wave in leads V4-V6	11.13	2.77-44.70	.001
No ST depression in leads III	18.28	4.78-69.93	<.001
Area below the ROC curve:0.8550			

1D indicates first diagonal; AD, anterior descending; CI, confidence interval; 1S, first septal.



**Fig. 5.** ECG of a patient with anterior AMI caused by a lesion distal to the first septal artery and first diagonal artery. Q-waves are observed in leads V4 through V6, as is the absence of Q-waves in lead aVL and the absence of ST segment depression on the inferior face. AMI indicates acute myocardial infarction.

#### Lesion distal to 1S and proximal to 1D (Figure 1, C)

ST segment elevation in lead I was present in 83.3% of patients with lesions distal to 1S and proximal to 1S (type C lesions), compared with 52.7% observed in patients with all other types of lesions (A+B+D) ( $P=.03$ ).

In lead aVR only 1 patient (5.5%) with a type C lesion had an elevated ST segment vs 40.2% of the rest of patients ( $P=.01$ ). In leads III and aVF, the prevalence of ST segment depression in patients with type C lesions was 77.7% compared with 51.3% ( $P=.07$ ) and 52.7% ( $P=.09$ ), respectively, in the remaining patients.

On multivariate analysis, ST segment depression in leads III and aVF and the absence of ST segment ele-

vation in lead aVR proved to be the most useful markers for predicting type C lesions (Table 4, Figure 4).

#### Lesion distal to 1D and proximal to 1S (Figure 1, D)

The prevalence of ST segment elevation in lead aVR for lesions distal to 1D and proximal to 1S was 62.5% vs 30.4% for the remainder of lesions ( $P=.1$ ). We did not observe the presence of Q-waves in leads aVL or V4 through V6 in any patient with a type D lesion but did observe an occurrence rate of 39.0% ( $P=.06$ ) and 31.7% ( $P=.1$ ), respectively, in the remaining patients.

The association of a right branch block with an anterior hemiblock was observed in 37.5% of patients with type D lesions compared with 7.31% of patients with the remaining types of lesions ( $P=.03$ ). On multivariate analysis, the most useful marker for locating this type of lesion was ST segment elevation in lead aVR ST (Table 4, Figure 3).

## DISCUSSION

The findings of this study show that the electrocardiographic changes produced by an AMI can prove to be useful for determining the extent of the lesion present in the anterior descending artery with regard to its 1S and 1D branch outlets.

#### Lateral member leads

In previous studies, ST segment elevation in leads I and aVL has been shown to have a high prevalence rate in lesions proximal to 1D and 1S.<sup>2,5,8</sup> ST segment elevation in these leads, particularly in lead aVL, has been considered a significant marker for identifying lesions of the AD artery proximal to its 1D branch,<sup>5,8,13</sup> which is attributed to the fact that these leads capture the potentials of the anterolateral wall of the left ven-

**TABLE 4. Electrocardiography markers for lesions of the AD artery**

Markers for lesions proximal to 1S+1D			
Regression-adjusted odds ratio			
Variables	Logistical	95% CI	P
No ST elevation in leads aVR	42.91	3.58-514.7	.003
ST elevation in lead V6	11.92	1.82-78.21	.01
ST depression in lead III	11.23	1.92-65.76	.007
No ST segment depression in lead V5	8.55	1.06-68.97	.04
Area under the ROC curve:0.586			
Markers for lesions distal to 1D and proximal to 1S			
ST elevation in lead aVR	6.44	1.22-34.04	.03
Area below the ROC curve:0.7162			

1D indicates first diagonal; AD, anterior descending; CI, confidence interval; 1S, first septal.

tricle, which is irrigated by the AD artery, and that a lesion of the AD artery proximal to the diagonal artery would cause transmural ischemia with ST segment elevation in leads I and aVL.<sup>8</sup>

Researchers have shown that ST segment depression in lead aVL is specific for a lesion distal to 1D.<sup>14</sup> This finding, together with the high prevalence of ST segment elevation in this type of lesion, has given rise to questions as to whether the ST changes in lead aVL depend on the presence or absence of an anterolateral branch.<sup>14</sup> In our study, we observed an ST segment decline in lead aVL in only 3 patients, and we did not find this value useful for predicting the extent of the lesion.

### aVR lead

The aVR lead has been generally ignored as a predictor, from the electrocardiographic viewpoint, of the location of coronary artery lesions. Some authors have observed an ST segment elevation in unstable angina with three-vessel coronary lesions and in patients with lesions of the common trunk.<sup>16,17</sup> Others have observed ST segment elevation during stress tests in patients with anterior myocardial infarcts<sup>18</sup> or during balloon inflation in coronary angioplasty, in the setting of an extensive area of ischemia.<sup>19</sup>

Several recent studies in the literature have reported a slight relationship between ST segment elevation in lead aVR and lesions of the AD artery proximal to its 1S branch.<sup>14,20</sup> The findings of our study concur with these observations, and show that ST segment elevation in lead aVR is the most significant marker for predicting lesions of the AD artery proximal to 1S. ST segment elevation in lead aVR has been attributed to transmural ischemia in the basal septal area, a hypothesis that is supported by the finding that those patients with lesions proximal to 1D but distal to 1S uniquely show an ST segment elevation in lead aVR.<sup>14</sup>

The relatively low incidence of this finding has been attributed to the infrequent predominance of basal septal ischemia, in contrast to common areas of ischemia in the left ventricle irrigated by the AD artery, such as the lateral and apical areas.<sup>14</sup>

### Inferior leads

There is controversy in the medical literature about the significance of ST depression in the inferior leads during anterior AMI. Inferior ST segment depression has been correlated with the severity of anterior wall ischemia,<sup>10,21</sup> with proximal lesions of the AD artery,<sup>10</sup> and with the existence of inferior ischemia added by critical lesion of the right coronary or circumflex artery.<sup>22,23</sup>

The high prevalence of ST segment elevation in leads I and aVL, which capture potentials from the high anterolateral face, and their strong correlation with the ST segment decline in inferior leads,<sup>8</sup> which capture oppo-

sing potentials, has led to the theory that ST segment depression in inferior leads is a phenomenon that is reciprocal to the ST segment elevation in leads I and aVL.<sup>8</sup> In the same manner, the constancy of inferior ST segment decline in patients with AD artery lesions who do not have additional lesions of other coronary arteries<sup>24,25</sup> supports the hypothesis that ST segment depression in the inferior leads represents the reciprocal image of the transmural ischemia in the high anterobasal area.<sup>9,25</sup>

ST segment depression of the anterior face is actually considered to be a significant marker for a proximal lesion of the AD artery.<sup>8,11,14</sup> Our study findings indicate that ST segment depression of the inferior face, especially in leads III and aVF, is a significant marker for lesions of the AD artery proximal to the first diagonal artery.

### Precordial leads

According to our findings, qualitative analysis of the right precordial leads is not useful for locating lesions of the AD artery, as 100% of patients presented with an ST segment elevation in leads V1-V3. An ST segment elevation >2.5 mm in lead V1 is considered a marker for a lesion proximal to 1S, but with a very low occurrence rate (12%).<sup>14</sup>

In our study, only the absence of ST segment elevation in lead V6 was shown to be a significant marker for lesions proximal to 1S. ST segment decline in lead V5 was previously considered to be a very specific marker for a lesions proximal to 1S and has been interpreted as a reciprocal change of the transmural ischemia in the high antero-septal area.<sup>14</sup> In our study, ST segment decline in lead V5 showed a higher prevalence of a lesion proximal to 1S than to a distal lesion, but without statistical significance.

### Abnormal Q-waves

The presence of an abnormal Q-wave in lead aVL behaves as a significant marker for a lesion proximal to 1D, and in leads V4 through V6, as a significant marker for a lesion distal to 1S. It has been suggested that in a lesion distal to the AD artery, ventricular and septal activation usually remain intact.

In cases in which necrosis is produced under the anterolateral leads, the septal vector may facilitate the formation of Q-waves in leads V5 through V6. On the other hand, in lesions proximal to 1S, the septal vector can diminish and even disappear, and therefore impede the formation of Q-waves.<sup>14</sup>

### Conduction disturbances

The presence of an anterior hemiblock is not a parameter that is of much use in locating lesions of the AD

artery. Nevertheless, the association of an anterior hemiblock with a right branch block acts as a significant marker for a proximal IS lesion. A proximal IS lesion has been correlated with a right branch block according to the anatomical distribution of the artery that perfuses the proximal portion of the branches and the distal branch of the bundle of His.<sup>14</sup>

## Study limitations

1. We have correlated the anterior myocardial infarct with the location of the anatomical lesion with coronary angiography; we know that coronary artery occlusion is a dynamic process and that spontaneous as well as therapeutic fibrinolysis can distort coronary angiographic evaluation. Similarly, the fact that in some cases angiography is performed several days after the start of clinical infarction can limit the interpretation of results, as can the lack of evaluation of collateral circulation.

2. The electrocardiography tracings were studied by choosing the one that showed the most changes of the tracings obtained during the first 3 days following the start of the clinical episode and, therefore, our findings may not be reproducible in situations where only one echocardiography tracing is available. With regard to the presence of Q-waves, the fact that the electrocardiographic study was performed within 3 days of the infarct could constitute a limitation, since the development of the infarct may not be complete at such an early stage.

We also must mention as a clinical limitation the fact that the evaluation of ST segment changes was qualitative, and we did not include in our study the relationship between the degree of ST segment changes and the site of the coronary lesion.

## CONCLUSIONS

In anterior AMIs, an ECG may be relatively useful for the localization of the AD artery lesion with respect to its IS and ID branches.

In clinical practice, it may be helpful in situations where it is only necessary to treat the lesion causing the ischemia.

## REFERENCES

- Pabón P, Arós F, San José JM, Bermejo J, López L, Monton AJ. Trombósis en el anciano con infarto agudo de miocardio. El estudio PRIAMHO. *Rev Esp Cardiol* 2000;53:1443-52.
- Iwasaki K, Kusachi S, Kita T, Taniguchi G. Prediction of isolated first diagonal branch occlusion by 12-lead electrocardiography: ST segment shift in leads I and aVL. *J Am Coll Cardiol* 1994;23:1557-61.
- Gaudron P, Eilles C, Kugler I, Ertl G. Progressive left ventricular dysfunction and early predictors. *Circulation* 1993;87:755-63.
- White HD, Norris RM, Brown MA, Brandt PW, Whitlock RM, Wild CJ. Left ventricular end-systolic volume as the major determinant of survival after recovery from myocardial infarction. *Circulation* 1987;76:44-51.
- Birnbaum Y, Sclarousky S, Solodky A, Tschori J, Herz I, Sulkes J, et al. Prediction of the level of left anterior descending coronary artery obstruction during anterior wall acute myocardial infarction by the admission electrocardiogram. *Am J Cardiol* 1993;72:823-25.
- Prieto JA, San José JM. Diferenciación electrocardiográfica entre la lesión de la arteria coronaria derecha y circunfleja en el infarto agudo de miocardio inferior. *Rev Esp Cardiol* 1996;49:174-83.
- Prieto JA, Martín R, San José JM. A new electrocardiographic approach to identify the coronary artery responsible for acute inferior myocardial infarction: A study in 100 patients. *Rev Port Cardiol* 1998;17:133-42.
- Birnbaum Y, Solodky A, Herz I, Kusniec J, Rechavia E, Sulkes J, et al. Implications of inferior ST-segment depression in anterior acute myocardial infarction: electrocardiographic and angiographic correlation. *Am Heart J* 1994;127:1467-73.
- Fletcher WO, Gibbons RJ, Clements IP. The relationship of inferior ST depression, lateral ST elevation, and left precordial ST elevation to myocardium at risk in acute anterior myocardial infarction. *Am Heart J* 1993;126:526-35.
- Lew S, Hod H, Cercek B, Shah PK, Ganz W. Inferior ST segment changes during acute anterior myocardial infarction: a marker of the presence or absence of concomitant inferior wall ischemia. *J Am Coll Cardiol* 1987;10:519-26.
- Tamura A, Kataoka H, Mikuriya Y, Nasu M. Inferior ST-segment depression as a useful marker for identifying proximal left anterior descending coronary artery occlusion during acute anterior myocardial infarction. *Eur Heart J* 1995;16:1795-9.
- Sapin PM, Musselman DR, Dehmer GJ, Cascio WE. Implications of inferior ST-segment elevation accompanying anterior wall acute myocardial infarction for the angiographic morphology of the left anterior descending coronary artery morphology and site of occlusion. *Am J Cardiol* 1992;69:860-5.
- Birnbaum Y, Hasdai D, Sclarousky S, Herz I, Strasberg B, Rechavia E. Acute myocardial infarction entailing ST-segment elevation in lead aVL: Electrocardiographic differentiation among occlusion of the left anterior descending, first diagonal, and first marginal coronary arteries. *Am Heart J* 1996;131:38-42.
- Engelen DJ, Gorgels AP, Cheriex EC, De Muinck ED, Oude AJ, Dassen WR, et al. Value of the electrocardiogram in localizing the occlusion site in the left anterior descending coronary artery in acute anterior myocardial infarction. *J Am Coll Cardiol* 1999;34:389-95.
- Selvester RH, Wagner GS, Hindman NB. The Selvester QRS scoring system for estimating myocardial infarct size: The development and application of the system. *Arch Intern Med* 1985;145:1877-81.
- Gorgels AP, Vos MA, Mulleneers R, Zwaan C, Bar FW, Welens JJ. Value of the electrocardiogram in diagnosing the number of severely narrowed coronary arteries in rest angina pectoris. *Am J Cardiol* 1993;72:999-1003.
- Prieto JA, Domínguez LA, Campo AB. El electrocardiograma en la lesión del tronco coronario izquierdo. *Clin Cardiovasc* 1999;17:15-20.
- Nakamori H, Iwasaka T, Shimada T, Kamihata H, Matsuura T, Koito H, et al. Clinical significance of ST segment elevation in lead aVR in anterior myocardial infarction. *Cardiology* 1995;86:147-51.
- Karakawa M, Iwasaka T, Kamihata H, Matsui Y, Nakamori H, Matsuura T, et al. Transient ST elevation in lead aVR during left anterior descending artery angioplasty as a marker of the adequacy of the coronary circulation. *J Cardiovasc Technol* 1992;10:233-9.
- Prieto JA, González C, Hernández M, Miñambres E. Valor de la elevación del ST de aVR en la localización de la lesión arterial en el infarto agudo de miocardio anterior. *Clin Cardiovasc* 2001;19:19-23.
- Ferguson DW, Pandian N, Kioschos JM, Marcus ML, White CW. Angiographic evidence that reciprocal ST-segment depression during acute myocardial infarction does not indicate remote ischemia: analysis of 23 patients. *Am J Cardiol* 1984;53:55-62.
- Haraphongse M, Tanomsup S, Jugdutt BI. Inferior ST segment depression during acute anterior myocardial infarction: clinical and angiographic correlations. *J Am Coll Cardiol* 1984;4:467-76.
- Kyriakidis M, Antonopoulos A, Barbetseas J, Aspiotis N, Georgiakis F, Sfrikakis P, et al. Correlations of reciprocal ST segment depression after acute myocardial infarction with coronary angiographic findings. *Int J Cardiol* 1992;36:163-8.
- Willems JL, Willems RJ, Willems GM, Arnold AER, Van de Werf F, Verstraete M. Significance of initial ST segment elevation and depression for the management of thrombolytic therapy in acute myocardial infarction. *Circulation* 1990;82:1147-58.
- Quyyumi AA, Rubens MB, Rickards AF, Crake T, Levy RD, Fox KM. Importance of «reciprocal» electrocardiographic changes during occlusion of left anterior descending coronary angioplasty. *Lancet* 1986;1:347-50.