

deterioration in liver function tests. The relevant device parameters were 3200 rpm and flow 5 L/min but the mixed venous oxygen saturation was 47%, indicating insufficient cardiac output despite adequate flow.

Despite cardiogenic shock, transthoracic echocardiography revealed normal right ventricular function and severe AR, which was confirmed on transesophageal echocardiography (figure 1A); there were no signs of endocarditis. We decided to perform emergency transcatheter aortic valve implantation with an EVOLUT device (Medtronic; Minneapolis, Minnesota, United States) (figure 1B–D). The patient's subsequent clinical course and blood tests were favorable and he was discharged with good functional status, which continued until at least 6 months after the implantation.

The HeartMate 3 long-term LVAD is a continuous flow device that can be used as destination therapy. Experience with this type of LVAD is slight. Accordingly, early identification of complications can be a challenge.

Although technological advances have reduced device thrombosis and embolic events,<sup>2</sup> AR occurrence is still common. Its development is related to a fall in the percentage of valve opening (which favors commissure fusion and tissue remodeling) and the effects of the nonpulsatile flow on the aortic root, which is subjected to hemodynamic stress during the entire cardiac cycle. The end result is valve failure and the establishment of an inefficient cycle—LVAD-aorta-left ventricle-LVAD (figure 2)—with decreased peripheral perfusion and recurrent symptoms of heart failure. Various patient-dependent factors predispose its development: small body surface, female sex, and advanced age. Other factors are the age of the LVAD, a persistently closed valve, excessive left ventricular unloading, and the anastomosis angle from the outflow graft. No significant differences have been found among devices.<sup>1</sup>

Diagnosis can be complicated due to a sometimes atypical and deceptive clinical presentation. The acoustic window is usually limited and traditional echocardiographic parameters underestimate the severity of the regurgitation, given that the AR continues throughout the entire cardiac cycle, increasing the regurgitant volume. New parameters have been described for its quantification: the systolic-to-diastolic peak velocity ratio and the outflow cannula diastolic acceleration.<sup>3</sup>

The management of this complication is challenging because surgical risk can sometimes be prohibitive in these patients. Accordingly, percutaneous devices are becoming a therapeutic option, despite limited evidence. Both transcatheter aortic prostheses<sup>4</sup> and percutaneous occlusion devices<sup>5</sup> have been used. Both approaches achieve favorable short-term hemodynamic outcomes.

For this patient, transcatheter aortic valve implantation was chosen due to the experience of our center and the availability of the technique.

In conclusion, the atypical clinical presentation, early development of valve disease, and comorbidity of this patient are another example of the challenge posed by LVAD therapy and of the importance of a multidisciplinary approach.

## CONFLICTS OF INTEREST

C. Morís de la Tassa is a proctor for Medtronic.

Amaia Martínez León,<sup>a,\*</sup> Beatriz Díaz Molina,<sup>a</sup>  
José Alonso Domínguez,<sup>b</sup> Jacobo Silva Guisasola,<sup>c</sup>  
Jose Luis Lambert Rodríguez,<sup>a</sup> and César Morís de la Tassa<sup>a</sup>

<sup>a</sup>Área del Corazón, Servicio de Cardiología, Hospital Universitario Central de Asturias, Oviedo, Asturias, Spain

<sup>b</sup>Área del Corazón, Unidad de Cuidados Intensivos Cardiológicos, Hospital Universitario Central de Asturias, Oviedo, Asturias, Spain

<sup>c</sup>Área del Corazón, Servicio de Cirugía Cardíaca, Hospital Universitario Central de Asturias, Oviedo, Asturias, Spain

\*Corresponding author:

E-mail address: [amaiamtzleon@gmail.com](mailto:amaiamtzleon@gmail.com) (A. Martínez León).

Available online 11 January 2020

## REFERENCES

1. Bouabdallaoui N, El-Hamamsy I, Pham M, et al. Aortic regurgitation in patients with a left ventricular assist device: A contemporary review. *J Heart Lung Transplant.* 2018;37:1289–1297.
2. Mehra MR, Goldstein DJ, Uriel N, et al. Two-year outcomes with a magnetically levitated cardiac pump in heart failure. *N Engl J Med.* 2018;378:1386–1395.
3. Bouchez S, Van Belleghem Y, De Somer F, et al. Haemodynamic management of patients with left ventricular assist devices using echocardiography: the essentials. *Eur Heart J Cardiovasc Imaging.* 2019;20:373–382.
4. Van der Werf HW, Schurer RA, Vonck TE, et al. Emergency transcatheter aortic valve implantation in patients with severe aortic regurgitation and a left ventricle assist device: A case report and systematic review. *Eur Heart J Acute Cardiovasc Care.* 2017;6:719–727.
5. Parikh KS, Mehrotra AK, Russo MJ, et al. Percutaneous transcatheter aortic valve closure successfully treats left ventricular assist device-associated aortic insufficiency and improves cardiac hemodynamics. *JACC Cardiovasc Interv.* 2013;6:84–89.

<https://doi.org/10.1016/j.rec.2019.10.022>  
1885-5857/

© 2019 Sociedad Española de Cardiología. Published by Elsevier España, S.L.U. All rights reserved.

## Gadolinium based contrast agent-free cardiac magnetic resonance imaging for the assessment of heart anatomy. A feasibility study

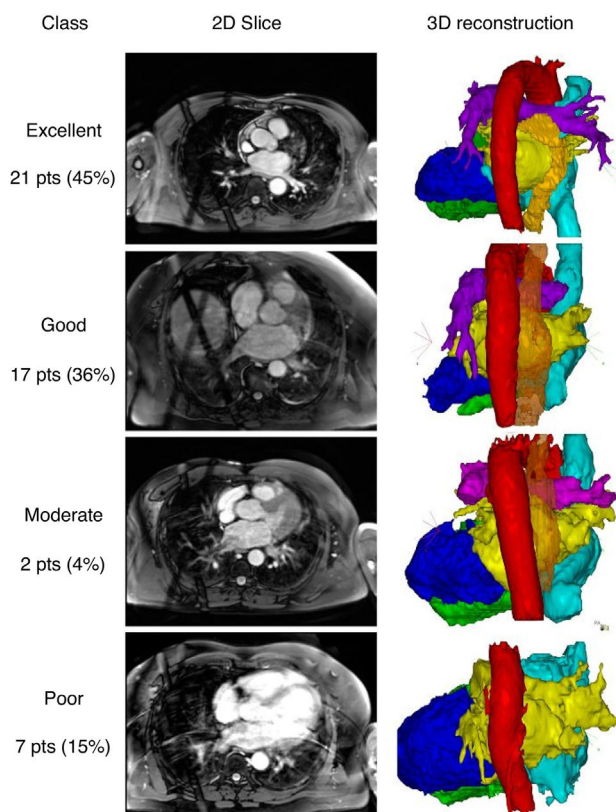


### Imágenes de resonancia magnética cardíaca sin contraste basadas en gadolinio para la evaluación de la anatomía del corazón: un estudio de viabilidad

#### To the Editor,

Cardiac magnetic resonance imaging (MRI) is an established diagnostic tool in medicine. To improve image quality, gadolinium-based chemicals are commonly used. Since gadolinium-based

contrast agents (GBCA) are primarily excreted by the kidney, patients with decreased kidney function showed an increased risk of GBCA retention leading to a potential risk of nephrogenic systemic fibrosis. In the last few years, magnetic resonance signal hyperintensity due to gadolinium retention was observed in the central nervous system in patients having received multiple GBCA doses over time even in patients with normal renal function.<sup>1</sup> This resulted in warnings by the US Food and Drug Administration, Japan's medical device agency, and the European Medicines Agency. In cardiology, imaging also plays an important role in the rapidly growing area of catheter ablation for atrial fibrillation (AF). The aim of the current study was to evaluate the feasibility



**Figure 1.** Examples of the 2-dimensional (2D) slices and 3-dimensional (3D) reconstructions. Classifications: excellent (without manual interaction); good (little manual interaction), moderate (extensive manual interaction); poor (left atrium anatomy and pulmonary vein orientation could not be reconstructed). Red, aorta; yellow, left atrium; orange, esophagus; bright blue, right atrium; dark blue, left ventricle; green, right ventricle; pts, patients.

and applicability of a GBCA-free protocol for the anatomical assessment of the heart for pulmonary vein isolation.

In a series of consecutive patients referred for catheter ablation of atrial fibrillation, MRI acquisition was performed using a GBCA-free protocol. The study was conducted according to the criteria set by the declaration of Helsinki and informed consent was obtained from all individual participants included in the study.

MRI was performed on 1.5 T scanners (Magnetom Avanto/Espreo, Siemens, Erlangen, Germany). A 3D free-breathing respiratory navigator gated steady-state free precession sequence was performed. This approach minimized respiratory motion by acquiring data within a small gating window at a predefined respiratory position. MRI parameters were: TR 206.50 ms, TE 1.2 ms, flip angle 90°. The acquisition window and trigger delay were depended on the individual patient. The voxel size was 0.9 x 0.9 x 2.0 mm<sup>3</sup>. Slice thickness was 2 mm with 20% slice oversampling. MRI acquisition time was assessed from the start of the first scan to the end of the last scan and scan duration was assessed from the start to the end of the steady-state free precession sequence.

Segmentation and reconstruction were performed using CartoMerge software (Biosense Webster, Diamond Bar, United States). First, a threshold filter was set based on the image intensity to exclude voxels with a lower image intensity than the voxels of the relevant cardiac structure. Second, chambers of interest were tagged with points on their surface for the segmentation based on a region-growing algorithm. If the chambers were not separated correctly, manual processing to cut away irrelevant structures or

**Table 1**  
Baseline parameters

|                         | N = 47  |
|-------------------------|---------|
| Age, y                  | 61 ± 8  |
| Male sex                | 38 (81) |
| BMI, kg/m <sup>2</sup>  | 27 ± 5  |
| Hypertension            | 26 (55) |
| PAF                     | 24 (51) |
| PLAX, mm                | 42 ± 6  |
| LAVI, ml/m <sup>3</sup> | 39 ± 10 |
| LVEF, %                 | 59 ± 13 |

BMI, body mass index; LAVI, left atrial volume indexed; LVEF, left ventricular ejection fraction; paroxysmal AF; PAF, paroxysmal atrial fibrillation; PLAX, left atrial size in parasternal long axis.

The data are expressed as No. (%) or mean ± standard deviation.

create detectable boundaries was allowed. Finally, 3-dimensional surface reconstructions were performed. Qualitative assessment was performed based on the ease of segmentation and the quality of the reconstructed heart chambers to accurately represent the pulmonary vein anatomy and orientation up to the first bifurcation. Reconstructions were categorized as: excellent (without manual interaction); good (little manual interaction); moderate (extensive manual interaction); and poor (left atrium (LA) anatomy and pulmonary vein orientation could not be reconstructed). Representative examples of the categories are shown in figure 1. Segmentation of the esophagus was performed after cardiac segmentation due to its lower signal intensity.

We included 47 patients in our study. The patients' baseline and echocardiographic data are shown in table 1. Whole heart visualization including all chambers and the esophagus was possible in 40 patients. The acquisition time and scan duration was 25.8 (22.0–32.5) minutes and 8.3 (6.3–11.5) minutes, respectively. Image quality was adequate (excellent, good, and moderate) with all cardiac structures and segments in 85% of the patients. The esophagus was visible and could be segmented in 91% of the patients. No difference between scans with adequate or poor quality in any of the baseline or procedural data could be identified.

The main findings of this study are: a) The GBCA-free acquisition protocol was feasible in all patients referred for catheter ablation of atrial fibrillation without complications. b) Anatomical assessment of the heart and in particular of the LA for electrophysiological procedures using a contrast-free native MRI protocol is usable in 85% of the patients. c) The course of the esophagus was visible in 91% of the patients.

In addition to the potential toxicity of GBCA, other rare complications such as allergic reactions have been documented.<sup>2</sup> With a GBCA-free acquisition protocol, these complications can be prevented. Furthermore, no venous access is required to enable contrast injection. In addition to the potential reduction in complications, right-sided cavities can be visualized, which facilitates catheter placement and transseptal puncture. To visualize the course and the width of the esophagus, electro-anatomical mapping using the ablation catheter<sup>3</sup> or radiological visualization of the swallowed barium paste has been reported.<sup>4</sup> Preprocedural, noninvasive assessment is possible using for instance a 3-dimensional late gadolinium enhanced MRI sequence, which allows the visualization of the course and the width of the esophagus in addition to the fibrosis in the LA.<sup>5</sup> In contrast to these complex or invasive strategies, the GBCA-free MRI approach has the potential to be used as simplified preprocedural assessment of the heart and the surrounding structures. Ideal candidates might be patients who are able to lie supine

comfortably and who have a regular breathing pattern and RR intervals. However, it remains to be determined whether the visualization of the esophagus and its location with regards to the LA and the ablation set might prevent complications such as atrioesophageal fistula.

In conclusion, anatomical assessment of the entire heart and in particular of the LA for electrophysiological procedures using a contrast-free native MRI protocol is sufficient in 85% of the patients. Despite the relatively long acquisition duration, the protocol is especially useful for patients with renal insufficiency or to visualize the course of the esophagus in addition to the heart anatomy.

#### CONFLICTS OF INTEREST

M. Kühne is proctor for Medtronic, speakers bureau for Boston Scientific, St Jude Medical, and Biotronik. C. Sticherling is advisory board of Medtronic and Biotronik, received educational grants from Biotronik and research grant from Biosense Webster, outside the submitted work.

Sven Knecht,<sup>a,b,\*</sup> Philip Haaf,<sup>a,b</sup> Florian Spies,<sup>a,b</sup> Antonio Madaffari,<sup>a,b</sup> Michael Kühne,<sup>a,b</sup> and Christian Sticherling<sup>a,b</sup>

<sup>a</sup>Cardiology/Electrophysiology Department, University Hospital Basel, University Basel, Basel, Switzerland

<sup>b</sup>Cardiovascular Research Institute Basel, University Hospital Basel, University Basel, Basel, Switzerland

\*Corresponding author:  
E-mail address: [sven.knecht@usb.ch](mailto:sven.knecht@usb.ch) (S. Knecht).

Available online 13 December 2019

#### REFERENCES

1. Kanal E, Tweedel MF. Residual or retained gadolinium: practical implications for radiologists and our patients. *Radiology*. 2015;275:630–634.
2. Becket K, Moriarity A, Langer J. Safe Use of Contrast Media: What the Radiologist Needs to Know. *Radiographics*. 2015;35:1738–1750.
3. Arana-Rueda E, Alonso Pedrote, Manuel Frutos-López, et al. Electroanatomical Mapping of the Esophagus in Circumferential Pulmonary Vein Isolation. *Rev Esp Cardiol*. 2009;62:1189–1192.
4. Bahnson T. Strategies to minimize the risk of esophageal injury during catheter ablation for atrial fibrillation. *Pacing Clin Electrophysiol*. 2009;32:248–260.
5. Knecht S, Sticherling C, Reichlin T, et al. Reliability of luminal oesophageal temperature monitoring during radiofrequency ablation of atrial fibrillation: insights from probe visualization and oesophageal reconstruction using magnetic resonance imaging. *Europace*. 2017;19:1123–1131.

<https://doi.org/10.1016/j.rec.2019.11.005>  
1885-5857/

© 2019 Sociedad Española de Cardiología. Published by Elsevier España, S.L.U. All rights reserved.

#### Minimally invasive approach for biventricular assist device with centrifugal pump: first experience in Spain



#### Abordaje mínimamente invasivo para la asistencia biventricular con bombas centrífugas: primera experiencia en España

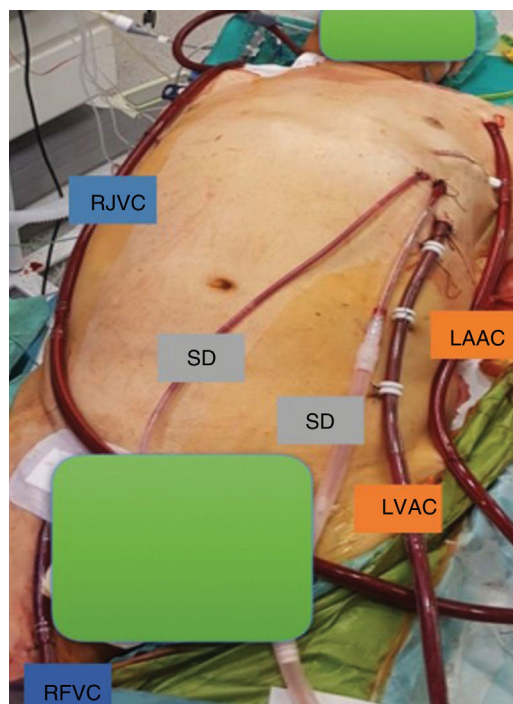
To the Editor,

In recent years, the field of cardiovascular surgery has witnessed an increasing use of minimally invasive procedures, aimed at minimizing surgical aggression and favoring patient recovery. Minimally invasive surgery has been shown to offer comparable safety and survival outcomes to conventional surgery, as well as a lower incidence of postoperative bleeding and shorter hospital stays.<sup>1</sup>

The increasing use of minimally invasive surgery for the implantation of long-term left ventricular assist devices (LVADs) has been favored by the smaller size of new models. Apart from improving cosmetic outcomes, minimally invasive LVAD implantation has been found to reduce postoperative bleeding rates and hospitalization time, resulting in considerable cost savings and similar short- and long-term survival outcomes to those seen in conventional surgery.<sup>2</sup> Minimally invasive and percutaneous approaches are also being increasingly used for the implantation of short- and intermediate-term VLADs.<sup>3</sup> The conventional approach for intermediate-term centrifugal biventricular assist device (BiVAD) implantation is median sternotomy. We present a case in which a Levitronix CentriMag BiVAD was implanted using minimally invasive surgery.

A 60-year-old man with a history of idiopathic dilated cardiomyopathy with severe left ventricular dysfunction was admitted for heart failure with signs of systemic congestion and decreased cardiac output. Despite treatment with vasoactive amines, diuretics, and ultrafiltration, the patient's condition deteriorated and he remained at level 3 of the INTERMACS

(Interagency Registry for Mechanically Assisted Circulatory Support) scale. Clinical and echocardiographic findings also



**Figure 1.** Cannulation and drainage setup following biventricular assist device implantation. LAAC, left axillary artery cannula (left ventricular assist device [LVAD] return cannula); RFVC, right femoral vein cannula (right ventricular assist device [RVAD] drainage cannula); LVAC, left ventricular apex cannula (LVAD drainage cannula); RJVC, right jugular vein cannula (RVAD return cannula); SD, surgical drain.