

Original article

# Gated-SPECT Myocardial Perfusion Imaging as a Complementary Technique to Magnetic Resonance Imaging in Chronic Myocardial Infarction Patients

Gemma Cuberas-Borrós,<sup>a</sup> Victor Pineda,<sup>b</sup> Santiago Agudé-Bruix,<sup>c</sup> Guillermo Romero-Farina,<sup>a</sup> M. Nazarena Pizzi,<sup>a</sup> Gustavo de León,<sup>a</sup> Joan Castell-Conesa,<sup>c</sup> David García-Dorado,<sup>a</sup> and Jaume Candell-Riera<sup>a,\*</sup>

<sup>a</sup>Servicio de Cardiología, Hospital Universitari Vall d'Hebron, Institut de Recerca (VHIR), Universitat Autònoma de Barcelona, Barcelona, Spain

<sup>b</sup>Servicio de Radiología, Hospital Universitari Vall d'Hebron, Institut de Recerca (VHIR), Universitat Autònoma de Barcelona, Barcelona, Spain

<sup>c</sup>Servicio de Medicina Nuclear, Hospital Universitari Vall d'Hebron, Institut de Recerca (VHIR), Universitat Autònoma de Barcelona, Barcelona, Spain

Article history:

Received 22 February 2013

Accepted 29 April 2013

Available online 23 July 2013

Keywords:

Magnetic resonance

Scintigraphy

Myocardial infarction

Hibernation

Palabras clave:

Resonancia magnética

Gammagrafía

Infarto de miocardio

Hibernación

ABSTRACT

**Introduction and objectives:** The aim of this study was to compare magnetic resonance and gated-SPECT myocardial perfusion imaging in patients with chronic myocardial infarction.

**Methods:** Magnetic resonance imaging and gated-SPECT were performed in 104 patients (mean age, 61 [12] years; 87.5% male) with a previous infarction. Left ventricular volumes and ejection fraction and classic late gadolinium enhancement viability criteria (<75% transmural) were correlated with those of gated-SPECT (uptake >50%) in the 17 segments of the left ventricle. Motion, thickening, and ischemia on SPECT were analyzed in segments showing nonviable tissue or equivocal enhancement features (50%-75% transmural).

**Results:** A good correlation was observed between the 2 techniques for volumes, ejection fraction ( $P<.05$ ), and estimated necrotic mass ( $P<.01$ ). In total, 82 of 264 segments (31%) with >75% enhancement had >50% single SPECT uptake. Of the 106 equivocal segments on magnetic resonance imaging, 68 (64%) had >50% uptake, 41 (38.7%) had normal motion, 46 (43.4%) had normal thickening, and 17 (16%) had ischemic criteria on SPECT.

**Conclusions:** A third of nonviable segments on magnetic resonance imaging showed >50% uptake on SPECT. Gated-SPECT can be useful in the analysis of motion, thickening, and ischemic criteria in segments with questionable viability on magnetic resonance imaging.

© 2013 Sociedad Española de Cardiología. Published by Elsevier España, S.L. All rights reserved.

## Gated-SPECT de perfusión miocárdica como técnica complementaria de la resonancia magnética para pacientes con infarto de miocardio crónico

RESUMEN

**Introducción y objetivos:** El objetivo de este estudio es comparar los resultados de la resonancia magnética y la gated-SPECT de perfusión miocárdica en la valoración de la función ventricular y la viabilidad en pacientes con infarto de miocardio en fase crónica.

**Métodos:** Se estudió con resonancia magnética y gated-SPECT a 104 pacientes (media de edad, 61 ± 12 años; el 87,5% varones) con infarto previo. Se correlacionaron los volúmenes y la fracción de eyección del ventrículo izquierdo y los criterios clásicos de viabilidad con realce tardío con gadolínio (< 75% de transmuralidad) con los de la SPECT (captación > 50%) en los 17 segmentos del ventrículo izquierdo. Se valoró la motilidad, el engrosamiento y la isquemia en la gated-SPECT de los segmentos no viables o con criterios dudosos con el realce (un 50-75% de transmuralidad).

**Resultados:** Se observó buena correlación entre ambas exploraciones para los volúmenes y la fracción de eyección ( $p < 0,05$ ) y para la masa necrótica estimada ( $p < 0,01$ ). De los 264 segmentos con realce > 75%, 82 (31%) tenían captación > 50% en la SPECT. De los 106 segmentos con criterios dudosos de viabilidad (un 50-75% de realce) en la resonancia magnética, en la SPECT 68 (64%) tenían una captación > 50%; 41 (38,7%), motilidad conservada; 46 (43,4%), engrosamiento conservado, y 17 (16%), criterios de isquemia.

**Conclusiones:** Una tercera parte de los segmentos considerados no viables en la resonancia magnética muestran captación > 50% en la SPECT. El análisis de la motilidad, engrosamiento y presencia de isquemia en la gated-SPECT es de utilidad en los segmentos de dudosa viabilidad en la resonancia magnética.

© 2013 Sociedad Española de Cardiología. Publicado por Elsevier España, S.L. Todos los derechos reservados.

\* Corresponding author: Servicio de Cardiología, Hospital Universitari Vall d'Hebron, Institut de Recerca (VHIR), Universitat Autònoma de Barcelona, Pg. Vall d'Hebron 119-129, 08035 Barcelona, Spain.

E-mail address: jcandell@vhebron.net (J. Candell-Riera).

### Abbreviations

LGE: late gadolinium enhancement  
 LV: left ventricle  
 LVEF: left ventricular ejection fraction  
 MRI: magnetic resonance imaging  
 PET: positron emission tomography  
 SPECT: single-photon emission computed tomography

## INTRODUCTION

Magnetic resonance imaging (MRI) imaging allows analysis of volumes and left ventricular ejection fraction (LVEF) and, via late gadolinium enhancement (LGE), evaluation of the myocardium at risk and determination of the transmural extent of myocardial necrosis.<sup>1-3</sup> A transmural extent of necrosis greater than 75% of the myocardial wall<sup>2,4</sup> or >4.5 mm<sup>5</sup> is an indicator of nonviable tissue or irrecoverable contractile function after revascularization. In addition, an uptake of < 50% of the maximum uptake of the left ventricle (LV) is being adopted as an indicator of nonviability in single-photon emission computed tomography (SPECT) of myocardial perfusion<sup>6</sup> and in fluorodeoxyglucose positron emission tomography (PET) evaluation of metabolism.<sup>5</sup> However, there are intermediate values (between 50% and 75% of transmural extent for MRI and between 30% and 50% uptake for isotope studies) that raise doubts on the optimal threshold for the more accurate prediction of the possibility of contractile recovery. Thus, some authors have suggested that uptakes of 40% for SPECT with technetium compounds<sup>7</sup> and 37% for PET<sup>8</sup> are better cutoff values. In addition, on induction of physical or pharmacological stress, these tracer techniques can be used to evaluate the degree of regional systolic wall thickening and the presence of ischemia to further aid the assessment of myocardial viability.<sup>9</sup>

The aim of this study was to compare the results of stress perfusion MRI and SPECT in a series of patients in the chronic phase of myocardial infarction and to determine the parameters of gated-SPECT that could be useful in the evaluation of viable myocardium.

## METHODS

### Patients

The present study evaluated 104 nonconsecutive clinically stable patients (mean age, 61 [12] years; 87.5% male) previously diagnosed with myocardial infarction according to international guidelines.<sup>10,11</sup> All patients were included in an MRI study of postinfarction ventricular remodeling, approved by the ethics committee of the center (PR-HG-36/2000) and underwent <sup>99m</sup>Tc-tetrofosmin gated-SPECT at the discretion of the treating physician, with a maximum interval between the 2 scans of less than 1 year.

The clinical and coronary angiographic characteristics of the 104 patients are shown in Table 1. The mean intervals between the acute myocardial infarction and myocardial perfusion SPECT and between SPECT and the MRI scan were 8 (6) months and 6 (4) months, respectively. There were no complications or readmissions due to acute coronary syndrome between the scans.

**Table 1**

Clinical, Ergometric, and Coronary Angiograph Characteristics of the Patients

Age, years	61 ± 12
Male sex	91 (87)
Diabetes mellitus	13 (12.5)
Hypertension	53 (50.9)
Hypercholesterolemia	55 (52.9)
Smokers	55 (52.9)
Nitrates	9 (8.7)
Beta blockers	53 (51.0)
ACE inhibitors or ARB	43 (41.3)
Previous revascularization	44 (42.3)
Stress test (n=101)	
MET	7.10 ± 2.84
%HR <sub>max</sub>	80.04 ± 11.75
SBP <sub>max</sub>	145 ± 26
HR <sub>max</sub> ×SBP <sub>max</sub>	18,534 ± 4,888
Angina	2 (1.9)
Coronary angiography (n=86)	
Single-vessel disease	46 (53.5)
Double-vessel disease	23 (27)
Triple-vessel disease	17 (19.5)

ACE, angiotensin-converting enzyme; ARB, angiotensin receptor blockers; HR, heart rate; MET, metabolic equivalent of task; SBP, systolic blood pressure. Data are expressed as no. (%) or mean±standard deviation.

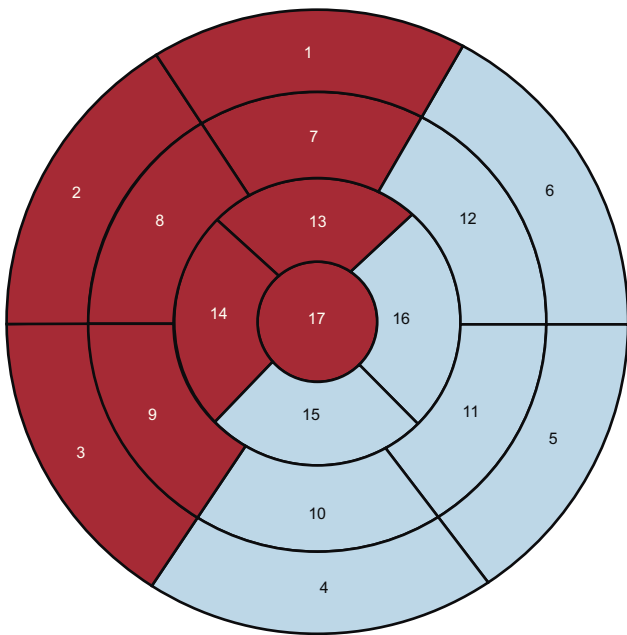
## Magnetic Resonance Imaging

MRI were obtained with a 1.5-T system (Avanto, Siemens; Germany) with a 4-element phased-array coil. All sequences were performed with electrocardiographic gating and during a breath hold. Segmented cine-MRI sequences were acquired (TrueFISP; echo time [TE], 1.4 ms; repetition time [TR], 55 ms; flip angle, 52°; bandwidth, 977 Hz/pixel; matrix, 256×212; slice thickness, 8 mm) in the short-axis (from the base to the apex of the LV), 2-chamber, and 4-chamber views. Ten minutes after contrast agent administration (gadolinium, 0.15 mmol/kg), late enhancement images were acquired with a segmented inversion-recovery sequence (TurboFlash; TE, 1.2 ms; TR, 450 ms; flip angle, 50°; bandwidth, 1180 Hz/pixel; matrix, 192×128; slice thickness, 8 mm) after the most appropriate inversion time had been selected to correctly suppress the signal of healthy myocardium and with the same slice positions as those obtained in the cine-MRI images.

The necrotic tissue mass on MRI was calculated by first manually delineating the margins of the hyperenhanced areas in the LGE sequence, then multiplying the specific myocardial mass by the volume estimated from the sum of the hyperenhanced areas by the slice thickness. The transmural extent of each myocardial segment was visually evaluated by quantifying the percentage LGE thickness with respect to the total wall thickness, provided that the enhancement occupied more than half of the total wall thickness. Five groups were established according to the degree of transmural extent: 1, no LGE; 2, <25% LGE; 3, 25% to <50% LGE; 4, 50% to <75% LGE; and 5, ≥75% LGE.

The LV was divided into 17 segments,<sup>12</sup> and 2 regions were defined: the anterior (ANT) region, which encompassed the anterior, septal, and apical segments, and the inferolateral (INF-LAT) region, which included the inferior and lateral segments (Fig. 1).

The variables studied were the end-diastolic and end-systolic volumes and LVEF the necrotic tissue mass in grams and its



**Figure 1.** Seventeen-segment polar map that differentiates between the anterior (red background) and inferolateral (blue background) regions. Segments: 1, basal anterior; 2, basal anteroseptal; 3, basal inferoseptal; 4, basal inferior; 5, basal inferolateral; 6, basal anterolateral; 7, mid anterior; 8, mid anteroseptal; 9, mid inferoseptal; 10, mid inferior; 11, mid inferolateral; 12, mid anterolateral; 13, apical anterior; 14, apical septal; 15, apical inferior; 16, apical lateral, and 17, apex.

percentage with respect to the total mass of the LV, necrotic mass estimated by segment, the number of LGE segments weighted by the degree of transmural, and the degree of segmental LGE transmural classified as one of the 5 categories described above.

### Gated-Single-photon Emission Computed Tomography

Symptom-limited exercise testing was performed in 101 of the 104 patients. In 16 of these patients who were unable to reach 80% of their peak heart rate or 5 metabolic equivalents of task, dipyridamole was administered at the time of the test.<sup>13</sup> For SPECT, a short 1-day protocol was used involving 300 MBq of <sup>99m</sup>Tc-tetrofosmin at stress and 900 MBq of <sup>99m</sup>Tc-tetrofosmin at rest; the resting test alone with 900 MBq <sup>99m</sup>Tc-tetrofosmin was performed in 3 patients. Sublingual nitroglycerine was administered to all patients before radionuclide injection for the resting test. Acquisition was begun 30-60 min after the stress test and 60-90 min after the injection at rest. A dual-head Siemens E.cam gamma camera was used, with adjacent detectors in a 90° (L-mode) configuration, a low-energy and high-resolution collimator, a <sup>99m</sup>Tc energy window, an acquisition zoom of 1.45, and a 64×64 matrix. The detection arc extended from the 45° right anterior oblique position to the 45° left posterior oblique position, with images taken every 3° at an acquisition time of 27 s per image. For gated-SPECT, an R-R acceptance window of 70% was used at a rate of 8 frames per cardiac cycle. Images were not corrected for attenuation. The tomographic reconstruction of the reoriented heart slices was carried out with OSEM (ordered-subset expectation maximization) iterative reconstruction and with a 0.35/10 Butterworth filter for the stress test (low dose) and a 0.45/10 filter for the resting test (high dose).

The quantitative evaluation of the degree of thickening and the quantitative grading of the perfusion of the wall segments was

performed on the polar map of the rest test with QPS automatic software for the perfusion and QGS for gated-SPECT.<sup>14,15</sup> In addition to the segment grading, defect extent was calculated by selecting 3 cutoff values for the *blackout* map: 30%, 40%, and 50%, with the Emory Cardiac Toolbox of Emory University.<sup>16</sup>

The following variables were studied:

- End-diastolic and end-systolic volumes and LVEF.
- Percentage extent of the defect in the polar map with an at-rest uptake of <30%, <40%, and <50%.
- Percentage uptake in each of the 17 segments, classified into 1 of 5 categories: normal, <30%, 30%-<40%, 40%- <50% and ≥50%.
- Regional wall motion, scored on a 6-point scale: 0, normal; 1, mild hypokinesia; 2, moderate hypokinesia; 3, severe hypokinesia; 4, akinesia; and 5, dyskinesia.
- Regional wall thickening, scored on a 5-point scale: 0, normal; 1, mildly impaired; 2, moderately impaired; 3, severely impaired; and 4, absent.

A segment was considered to have signs of ischemia on SPECT when the score between the stress and resting tests improved by at least 1 grade. A segment was considered to have normal motion and thickening on gated-SPECT when its score was between 0 and 2.

### Statistical Analysis

Data on quantitative variables are expressed as means (standard deviations) and intervals, and categorical variables are expressed as percentages or proportions. The Kolmogorov-Smirnov test was used to test the normality of the distribution. The Pearson correlation coefficient was determined for ventricular function variables and volumes obtained with gated-SPECT and MRI and for the intraclass correlation for the amount of MRI transmural in relation to segmental uptake on SPECT. To compare the quantitative variables by category, the means were compared through an analysis of variance with Bonferroni comparison.  $P < .05$  was considered statistically significant. A receiver operating characteristic (ROC) curve was plotted for the level of segmental uptake on SPECT and the degree of segmental transmural on MRI, using as a criterion of viability a transmural LGE of <75% on MRI. Kappa index ( $k$ ) was calculated between the optimal SPECT threshold of the ROC curve and <75% LGE on MRI.

Three sets of data were analyzed: first, the variables of the 104 patients; second, the variables for each of the 1,768 segments, and, finally, those segments with LGE and those with borderline viability on the MRI. SPSS statistical software package version 15 was used for all analyses.

### RESULTS

The correlations between MRI and gated-SPECT for the end-diastolic volume (144 [43] mL vs 149 [56] mL), the end-systolic volume (78 [38] mL vs 88 mL), and the LVEF (45% [12%] vs 44% [13%]) were 0.707, 0.762, and 0.707, respectively ( $P < .05$ ).

The necrotic mass on MRI was 21.7 [13.7] g (16.2% [9.9%] that of the LV). The amount of necrotic mass was <15% that of the total LV mass in 55.8% of the patients, 15%-30% in 35.6%, and >30% in 8.7%. The correlations between the necrotic mass determined with MRI and the extent of necrosis in the SPECT polar map for the thresholds of <30%, <40%, and <50% were 0.498, 0.497, and 0.487, respectively ( $P < .01$ ). The correlations between the necrotic mass by segment estimated with MRI and the extent of necrosis in the SPECT polar map for the thresholds of <30%, <40%, and <50% were 0.543, 0.523, and 0.512, respectively ( $P < .01$ ).

## Segmental Analysis

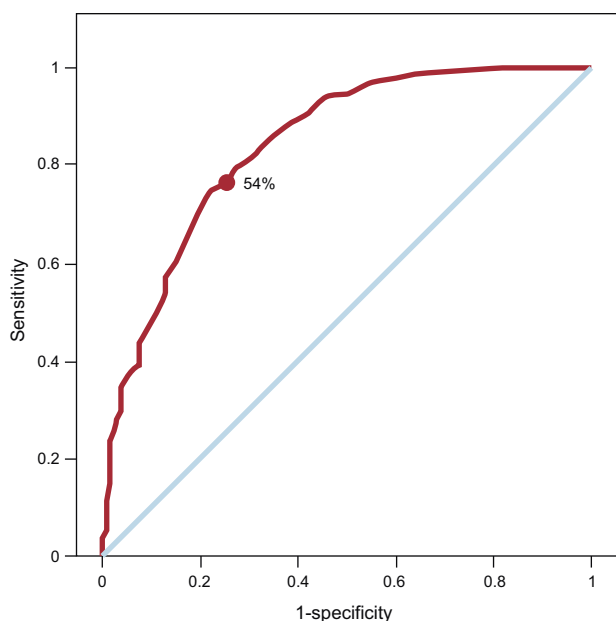
We analyzed 1,768 segments (17 segments from 104 patients).

For the SPECT ROC curve of the myocardial perfusion, taking an LGE transmural of <75% as criteria of viability, the area under the curve was 0.845 (Fig. 2). The optimal SPECT uptake threshold was 54%, which gave the highest sensitivity and specificity (78% and 75.7%, respectively). For this SPECT threshold, the kappa ( $\kappa$ ) was 0.409.

The intraclass correlations between the increase in the amount of LGE transmural and the reduction in the amount of SPECT uptake in the ANT and INF-LAT regions and in the basal, mid, and apical segments are shown in Table 2. The best correlation between the degree of LGE transmural and the reduction in the amount of SPECT uptake was found in the apical segments.

A total of 477 of the 1,768 segments showed LGE, of which 80.1% were located in the ANT region; the remainder (19.9%) were in the INF-LAT region. Of these segments with LGE, 7.5%, 34.8%, and 57.7% had basal, mid-cavity, and apical locations, respectively. The degree of transmural was <25% in 5% of the segments, 25%-50% in 17.4%, 50%-75% in 22.2%, and >75% in 55.3%. Thus, from the point of view of the MRI, more than half of the segments with LGE did not meet the criteria for viability.

Table 3 and Figure 3 show the relationship between the percentage SPECT uptake and the degree of LGE transmural expressed in numbers of segments. Of the 264 segments without classic viability criteria on MRI (ie, an LGE transmural >75%), 82 (31%) had an uptake >50% on SPECT (Fig. 4) and 106 segments (22.2% of the LGE segments) had questionable viability criteria (an LGE of 50%-75%) on MRI. Of these 106 segments, 68 (64%) had an uptake >50% on SPECT, 41 (38.7%) showed normal motion, 46 (43.4%) normal thickening, and 17 (16%) showed criteria of ischemia.



**Figure 2.** Receiver operating characteristic curve plotted for the amount of segmental uptake on single-photon emission computed tomography and magnetic resonance imaging taking as a reference of viability a late gadolinium enhancement transmural of <75%. Area under the curve = 0.845. The uptake point chosen for single-photon emission computed tomography (54%) attempts to maximize both sensitivity (78%) and specificity (74.7%).

**Table 2**

Intraclass Correlations Between the Degree of Transmurality of Late Gadolinium Enhancement and the Level of Uptake on Single-photon Emission Computed Tomography

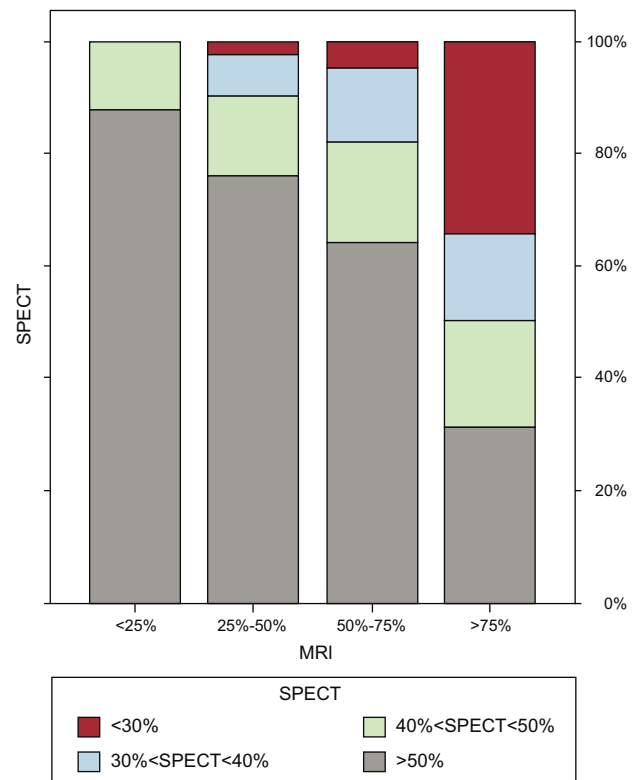
Segments	R
All (n=1768)	-0.420
Anterior region	-0.439
Inferolateral region	-0.380
Basal segments	-0.255
Mid segments	-0.368
Apical segments	-0.450

**Table 3**

Relationship Between the Percentage Uptake on Single-photon Emission Computed Tomography and the Degree of Late Gadolinium Enhancement Transmurality on Magnetic Resonance Imaging Expressed in Number of Segments

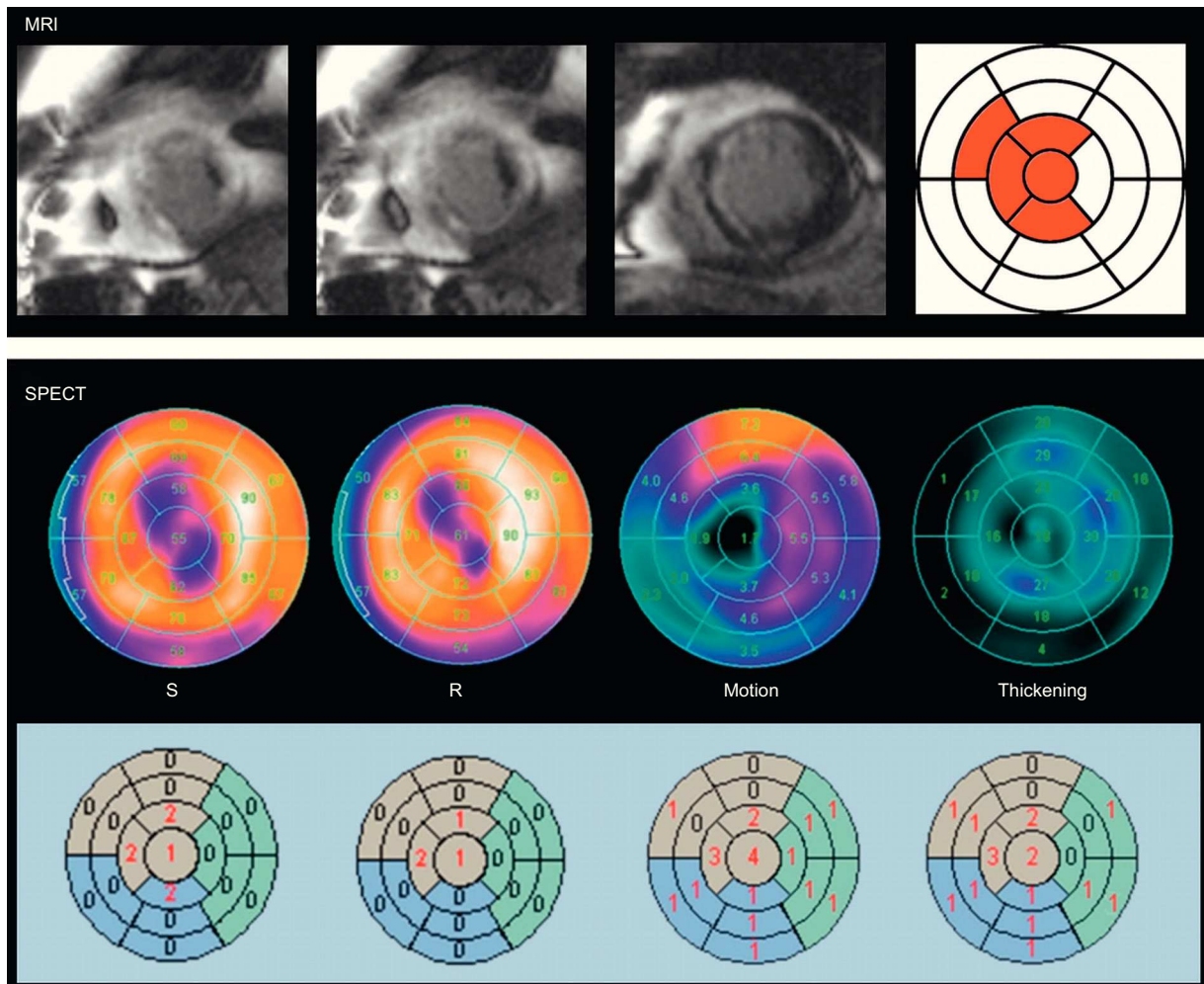
	SPECT				Total
	<30%	30% to <40%	40% to <50%	≥50%	
<i>MRI</i>					
<25%	0	0	3	21	24
25% to 50%	2	6	12	63	83
50% to <75%	5	14	19	68	106
≥75%	90	42	50	82	264
<b>Total</b>	<b>97</b>	<b>62</b>	<b>84</b>	<b>234</b>	<b>477</b>

MRI, magnetic resonance imaging; SPECT, single-photon emission computed tomography.



**Figure 3.** Bar graphs showing the relationship between the percentage uptake on single-photon emission computed tomography and the degree of transmural of the late gadolinium enhancement on magnetic resonance imaging. MRI, magnetic resonance imaging; SPECT, single-photon emission computed tomography.





**Figure 4.** Example of a viability discrepancy between magnetic resonance imaging and single-photon emission computed tomography in a patient with a previous myocardial infarction. The degree of transmural of the late gadolinium enhancement is  $>75\%$  in 4 segments (in red), while in the single-photon emission computed tomography polar maps reversibility was seen between stress and rest, in conjunction with normal motion (score, 1-2), and normal thickening (score, 1-2), in those segments, except in the apical segment (score, 4) and apical septum (score, 3). MRI, magnetic resonance imaging; R, rest; S, stress; SPECT, single-photon emission computed tomography.

## DISCUSSION

The results of the present study show that, although the general correlation between MRI and gated-SPECT for the estimation of LV volumes and LVEF is good, there are discrepancies between the techniques in quantification of the extent of necrosis and evaluation of myocardial viability. MRI with LGE has been shown to be superior to SPECT myocardial perfusion imaging for the determination of transmural myocardial necrosis, particularly in subendocardial infarctions.<sup>17,18</sup> This suboptimal sensitivity of SPECT is explained by its lower spatial resolution. However, the viability threshold of transmural necrosis for a given myocardial segment is not well established. Among other factors, the reason for this lack of a clear cutoff could be that the transmural of necrosis is not necessarily homogenous throughout the entire myocardial segment. For this and other reasons, the superiority of MRI, even when compared with PET, continues to cause controversy.<sup>19,20</sup> Another point that justifies comparison between the 2 techniques is that the use of MRI can present limitations in certain patients, such as those who have pacemakers or automatic implantable defibrillators, lack a regular stable rhythm, are unable to maintain the required breath hold duration, or have renal insufficiency or claustrophobia.

Although we found an acceptable correlation in our series between the overall necrotic mass of the LV estimated by MRI and the extent of necrosis on SPECT, the segment-to-segment comparison between the techniques was less precise. The basal region was the area showing the greatest discrepancy between the degree of LGE transmural necrosis and the percentage uptake on SPECT. This divergence is largely due to problems in the quantification of the amount of isotope uptake in the anteroseptal segments of the basal region in the SPECT polar map. These problems arise because the length of the septum is less than that of the lateral wall of the LV, which means that these segments often show a low percentage uptake that largely corresponds to extracardiac activity.

One of the difficulties of interpreting viability results with both MRI and SPECT is the observation of equivocal or borderline criteria or, in other words, the attainment of “probable results” rather than “definitive results”. Thus, although MRI provides images of a greater spatial resolution, their interpretation can raise doubts about the viability of certain regions. Kim et al.<sup>2</sup> observed equivocal or nondiagnostic results in 293 of 804 segments (36%). For these authors, segments with an LGE occupying  $>75\%$  of the area were considered nonviable and those with an LGE occupying  $<25\%$  were considered viable. Between these values, the

probability of contractile recovery after revascularization is only 50%. Other authors have proposed different cutoff values as viability criteria for MRI, such as a thickness  $<4.5$  mm of LGE<sup>5</sup> or  $>3$  mm of absence of LGE.<sup>8</sup> In a series of 26 patients with ischemic cardiomyopathy (ejection fraction, 31% [11%]), Kühl et al.<sup>8</sup> found a clear inverse correlation between the degree of LGE and the level of <sup>18</sup>F-fluorodeoxyglucose uptake. Through ROC curve analysis, the authors calculated a threshold of 37% PET uptake that best differentiated between viable and nonviable myocardium. By using this value as a reference for PET, the sensitivity and specificity of MRI for the diagnosis of nonviable myocardium were 96% and 84%, respectively. In 2006, Kühl et al.<sup>21</sup> used a segmental area of LGE  $>50\%$  and an uptake of  $<50\%$  for PET/SPECT as criteria of nonviability in a series of 29 patients with ischemic cardiomyopathy (ejection fraction, 32% [10%]), they obtained a positive predictive value for contractile recovery of 73%, identical for both techniques, while the negative predictive value was higher for MRI (93% vs. 77%).

In our series, we confirmed this negative correlation between the degree of LGE transmural and the amount of isotope uptake with SPECT, in particular for the apical segments, but we also observed discrepancies between MRI and SPECT. About one-third (31%) of the segments with classic viability criteria on MRI (an LGE  $>75\%$ ) had a percentage uptake of  $>50\%$  on SPECT. In addition, 22% of the segments with LGE had equivocal viability criteria (an LGE of 50%–75%) on MRI. In these segments, SPECT can aid the viability diagnosis, as 64% had  $>50\%$  uptake, 39% had normal motion, 43% had normal thickening, and 16% showed reversibility (a stress-rest difference  $>1$ ) (ischemia). MRI also allows the evaluation of wall thickening, motion and ischemia when performed after stress, which can clarify ambiguous results obtained with LGE evaluation alone.

Segmental study of necrosis and viability does not allow conclusions to be drawn about the general contractile recovery of the LV once the patient is revascularized, because other clinical and coronary angiographic factors play important roles in the prognoses of these patients.<sup>22–24</sup> In some series, the minimum amount of viable myocardium required for improvement in general contractile function is considered to be 15%<sup>25</sup>; however, in a meta-analysis of 29 studies of 4,167 patients, Inaba et al.<sup>26</sup> estimated that the amount of viable myocardium necessary for an improved survival after surgical revascularization in ischemic cardiomyopathy was 25.8% with PET, 35.9% with stress echocardiography, and 38.7% with SPECT.

### Limitations

Patient inclusion in this study was nonconsecutive and the results obtained only reflect the results and experience of a single center with the scans performed. Moreover, the profile of the patients included was probably less than ideal for the study of myocardial viability because a considerable percentage had an LVEF of  $>40\%$ . Stress-rest SPECT is more complete than at-rest MRI and the methodology used for segmental evaluation of transmural is visual with LGE but is performed with an automatic program<sup>14,15</sup> that semiquantitatively measures the tracer uptake in the LV polar map with SPECT. In our study, wall motion and thickening were not studied with MRI; however, the correlation of the results obtained with this technique and those obtained through gated-SPECT is good. For example, Whaba et al.<sup>27</sup> observed an agreement between the 2 techniques of 80% ( $\kappa=0.66$ ) for motion and of 84% ( $\kappa=0.70$ ) for thickening in patients with previous infarction. A strict segment-to-segment comparison between the 2 techniques is hampered by the use of a polar map with different characteristics from that used for the

MRI. This limitation could be overcome through the use of polar maps that more objectively reflect the extent of LGE. Furthermore, although the distinct segments of each patient are not independent of one another, our statistical analysis focused on segmental comparisons. If we had used attenuation correction in our study, the correlation with the results of MRI would probably have been even closer. Raja et al.<sup>28</sup> have shown excellent agreement between SPECT and PET for the evaluation of viability following the use of nitrates and attenuation correction in the SPECT analysis. Finally, the absence of postrevascularization results hindered the estimation of the diagnostic efficacy of MRI and SPECT in the prediction of contractile recovery.

### CONCLUSIONS

The correlation between MRI and gated-SPECT for volumes and LVEF and the estimated necrotic mass is good, although the correlation between the degree of transmural in MRI and SPECT uptake level is suboptimal, particularly in the basal region of the LV. One-third of the segments considered to be nonviable in MRI (an LGE  $>75\%$ ) showed  $>50\%$  uptake on SPECT. Of the segments considered borderline in the MRI (an LGE of 50%–75%), two-thirds had an uptake of  $>50\%$  in gated-SPECT, 39% had normal motion, 43.4% had normal thickening, and 16% had ischemia. These results could have clinical implications in those centers that use at-rest MRI as the first-line option for the diagnosis of viability and that obtain inconclusive results, because, in this eventuality, they allow determination of the benefit, if any, that could be provided by a stress-rest gated-SPECT.

### CONFLICTS OF INTEREST

None declared.

### REFERENCES

- Ruiz-Nodar JM, Feliu E, Sánchez-Quiñones J, Valencia-Martín J, García M, Pineda J, et al. Miocardio rescatado tras angioplastia coronaria de rescate: cuantificación mediante resonancia magnética cardiaca. *Rev Esp Cardiol*. 2011; 64:965–71.
- Kim RJ, Wu E, Rafael A, Chen EL, Parker MA, Simonetti O, et al. The use of contrast-enhanced magnetic resonance imaging to identify reversible myocardial dysfunction. *N Engl J Med*. 2000;343:1445–53.
- Wu E, Judd RM, Vargas JD, Klocke FJ, Bonow RO, Kim RJ. Visualization of presence, location, and transmural extent of healed Q-wave and non-Q-wave myocardial infarction. *Lancet*. 2001;357:21–8.
- Roes SD, Kaandorp TAM, Marsan NA, Westenberg JJM, Dibbets-Schneider P, Stokkel MP, et al. Agreement and disagreement between contrast-enhanced magnetic resonance imaging and nuclear imaging for assessment of myocardial viability. *Eur J Nucl Med Mol Imaging*. 2009;36:594–601.
- Knuesel PR, Nanz D, Wyss C, Buechi M, Kaufmann PA, Von Schulthess. et al. Characterization of dysfunctional myocardium by positron emission tomography and magnetic resonance. Relation to functional outcome after revascularization. *Circulation*. 2003;108:1095–100.
- Wu YW, Tadamura E, Yamamuro M, Kanao S, Marui A, Tanabara K, et al. Comparison of contrast-enhanced MRI with <sup>18</sup>F-FDG PET/<sup>201</sup>Tl SPECT in dysfunctional outcome after surgical revascularization in chronic ischemic heart disease. *J Nucl Med*. 2007;48:1096–103.
- Castell J, Candell-Riera J, Roselló-Urgell J, Fraile López-Amor M, Hornero-Sos F, Aguadé-Bruix S, et al. Valoración de la viabilidad miocárdica mediante tecnecio-99m isonitrilo y talio-201. Resultados del protocolo multicéntrico español. *Rev Esp Cardiol*. 1997;50:320–30.
- Kühl HP, Beek AM, Van der Weerd AP, Hofman MBM, Visser CA, Lammertsma AA, et al. Myocardial viability in chronic ischemic heart disease. Comparison of contrast-enhanced magnetic resonance imaging with <sup>18</sup>F-Fluorodeoxyglucose positron emission tomography. *J Am Coll Cardiol*. 2003;41:1341–8.
- Candell-Riera J, Castell-Conesa J, González JM, Roselló-Urgell J; en representación del Grupo de Trabajo de Cardiología Nuclear. Eficacia del SPET miocárdico esfuerzo-reposo con <sup>99m</sup>Tc-MIBI en la predicción de la recuperabilidad de la función contráctil postrevascularización. Resultados del protocolo multicéntrico español. *Rev Esp Cardiol*. 2000;53:903–10.

10. Van der Werf F, Bax J, Betriu A, Blomstrom-Lundqvist C, Crea F, Falk V, et al. Management of acute myocardial infarction in patients presenting with persistent ST-segment elevation: the Task Force on the management of ST-segment elevation acute myocardial infarction of the European Society of Cardiology. *Eur Heart J*. 2008;29:2909–45.
11. Kushner FG, Hand M, Smith SC, King SB, Anderson JL, Antman EM, et al. 2009 focused updates: ACC/AHA guidelines for the management of patients with ST-elevation myocardial infarction updating the 2004 guideline and 2007 focused update) and ACC/AHA/SCAI guidelines on percutaneous coronary intervention (updating the 2005 guideline and 2007 focused update) a report of the American College of Cardiology Foundation/American Heart Association Task Force on Practice Guidelines. *J Am Coll Cardiol*. 2009;54:2205–41.
12. Cerqueira MD, Weissman NJ, Dilsizian V, Jacobs AK, Kaul S, Laskey WK, et al. American Heart Association Writing Group on Myocardial Segmentation and Registration for Cardiac Imaging. Standardized myocardial segmentation and nomenclature for tomographic imaging of the heart: a statement for healthcare professionals from the Cardiac Imaging Committee of the Council on Clinical Cardiology of the American Heart Association. *Circulation*. 2002;105:539–42.
13. Candell-Riera J, Santana-Boado C, Castell-Conesa J, Agudé-Bruix S, Olona M, Palet J, et al. Simultaneous dipyridamole/maximal subjective exercise with <sup>99m</sup>Tc-MIBI SPECT: improved diagnostic yield in coronary artery disease. *J Am Coll Cardiol*. 1997;29:531–6.
14. Germano G, Erel J, Lewin H, Kavanagh PB, Berman DS. Automatic quantitation of regional myocardial wall motion and thickening from gated technetium-99m sestamibi myocardial perfusion single-photon emission computed tomography. *J Am Coll Cardiol*. 1997;30:1360–7.
15. Slomka PJ, Berman DS, Xu Y, Kavanagh P, Hayes SW, Dorbala S, et al. Fully automated wall motion and thickening scoring system for myocardial perfusion SPECT: method development and validation in large population. *J Nucl Cardiol*. 2012;19:291–302.
16. Garcia E, Cooke CD, Van Train KF, Folks R, Peifer J, DePuey DG, et al. Technical aspects of myocardial SPECT imaging with technetium-99m sestamibi. *Am J Cardiol*. 1990;66:E23–31.
17. Wagner A, Mahrholdt H, Holly TA, Elliot MD, Regenfus M, Parker M, et al. Contrast-enhanced MRI and routine single photon emission computed tomography (SPECT) perfusion imaging for detection of subendocardial myocardial infarcts: an imaging study. *Lancet*. 2003;361:374–9.
18. Ibrahim T, Bülow HP, Hackl T, Hörnke M, Nekolla SG, Breuer M, et al. Diagnostic value of contrast-enhanced magnetic resonance imaging and single-photon emission computed tomography for detection of myocardial necrosis early after acute myocardial infarction. *J Am Coll Cardiol*. 2007;49:208–16.
19. Maddahi J. Viability assessment with MRI is superior to FDG-PET for viability: Pro. *J Nucl Cardiol*. 2010;17:292–7.
20. Patterson RE, Sigman SR, O'Donnell RE, Eisner RL. Viability assessment with MRI is superior to FDG-PET for viability: Con. *J Nucl Cardiol*. 2010;17:298–309.
21. Kühl HP, Lipke CSA, Krombach GA, Katoh M, Battenberg TF, Nowak B, et al. Assessment of reversible myocardial dysfunction in chronic ischemic heart disease: comparison of contrast-enhanced cardiovascular magnetic resonance and combined positron emission tomography-single photon emission computed tomography imaging protocol. *Eur Heart J*. 2006;27:846–53.
22. Candell-Riera J, Romero-Farina G, Agudé-Bruix S, Castell-Conesa J, De León G, García-Dorado D. Prognostic value of myocardial perfusion-gated SPECT in patients with ischemic cardiomyopathy. *J Nucl Cardiol*. 2009;16:212–21.
23. Romero-Farina G, Ferreira I, Agudé-Bruix S, Castell-Conesa J, Igual A, Candell-Riera J. Análisis del número de pacientes que es necesario tratar mediante revascularización coronaria en relación con la presencia de viabilidad miocárdica en las imágenes de la gated-SPECT: estudio de cohorte prospectivo desde una unidad de cardiología nuclear. *Rev Esp Med Nucl*. 2009;28:6–10.
24. Candell-Riera J, Romero-Farina G, Agudé-Bruix S, Castell-Conesa J. La miocardiopatía isquémica desde la perspectiva de la cardiología nuclear clínica. *Rev Esp Cardiol*. 2009;62:903–17.
25. Santana CA, Shaw LJ, Garcia EV, Soler-Peter M, Candell-Riera J, Grossman GB, et al. Incremental prognostic value of left ventricular function by myocardial ECG-gated FDG PET imaging in patients with ischemic cardiomyopathy. *J Nucl Cardiol*. 2004;11:542–50.
26. Inaba Y, Chen JA, Bergmann SR. Quantity of viable myocardium required to improve survival with revascularization in patients with ischemic cardiomyopathy: a meta-analysis. *J Nucl Cardiol*. 2010;17:646–54.
27. Whaba FFM, Lamb HJ, Bax JJ, Dibbets-Schneider P, Bavelaar-Croon CDL, Zwinderman AH, et al. Assessment of regional myocardial wall motion and thickening by gated <sup>99m</sup>Tc-tetrofosmin SPECT: a comparison with magnetic resonance imaging. *Nucl Med Commun*. 2001;22:663–71.
28. Raja S, Singh B, Rohit MK, Manohar K, Kashyap R, Bhattacharya A, et al. Comparison of nitrate augmented Tc-99m tetrofosmin gated SPECT imaging FDG PET imaging for the assessment of myocardial viability in patients with severe left ventricular dysfunction. *J Nucl Cardiol*. 2012;10:1176–81.