

# Immediate and Long-Term Results of Implantation of the New Platinum Coronary Stent (Atlas Stent) in Patients with Coronary Artery Disease

Arturo Abundes, José de J. Rivera, Efraín Arizmendi, Javier Farell, Mariano Ledesma and Silvestre Montoya

Hospital de Cardiología. Centro Médico Nacional Siglo XXI.  
Instituto Mexicano del Seguro Social. México DF. México.

**Background and objectives.** We evaluated the technical and clinical results of implantation of the Atlas stent, the hospital stay, and the short and long-term clinical and angiographic outcome.

**Patients and method.** The study included 169 patients (60.1 ± 10.8 year-old), 60.3% of which had acute coronary syndromes and complex lesions. Immediate success was achieved in 98% of cases. The clinical follow-up in 85.7% of the patients at 14.3 ± 6.8 months, revealed that 89% remained free of adverse events and most (94.4%) were functional class I of the CCS. Angiographic follow-up at 8.4 ± 4.1 months of 40.9% of the cases revealed restenosis in 27.9%. There were 2 cases of subacute thrombosis.

**Conclusions.** The application of the Atlas™ stent in patients with a diverse clinical spectrum demonstrated good immediate and long term results, with a rate of restenosis similar to that of other stents available on the market

**Resultados inmediatos y a largo plazo del implante de un nuevo *stent* coronario de platino (*stent* Atlas) en pacientes con enfermedad arterial coronaria**

**Introducción y objetivos.** Evaluamos el resultado técnico y clínico de la aplicación del *stent* coronario de platino, la evolución hospitalaria, así como la evolución clínica y angiográfica, tanto a corto como a largo plazo.

**Pacientes y método.** Incluimos a 169 pacientes consecutivos de 60,1 ± 10,8 años, en su mayoría (60,3%) con síndromes isquémicos agudos y lesiones complejas. Se obtuvo éxito inmediato en el 98% de los casos. El seguimiento clínico en el 85,7% de los pacientes a los 14,3 ± 6,8 meses reveló que el 89% se mantuvo libre de acontecimientos adversos y la mayoría (94,4%) en clase funcional I. El seguimiento angiográfico a los 8,4 ± 4,1 meses en 40,9% de los casos puso de manifiesto reestenosis en el 27,9%. Hubo 2 casos de trombosis subaguda.

**Conclusiones.** La aplicación del *stent* Atlas™ en pacientes con espectro clínico diverso demostró buenos resultados inmediatos y tras el seguimiento, con tasas de reestenosis similares a las obtenidas con otros *stents* disponibles en el mercado.

**Key words:** Stent. Coronary artery disease. Coronary angioplasty.

**Palabras clave:** Stent. Enfermedad coronaria. Angioplastia coronaria.

Full English text available at: [www.revespcardiol.org](http://www.revespcardiol.org)

## INTRODUCTION

Stents are devices commonly used in the treatment of coronary artery obstruction.<sup>1-4</sup> We have carried out phase I to III experiments with the Atlas stent with good results.<sup>5</sup> This coil stent has design advances such as a flat platinum wire construction (90%

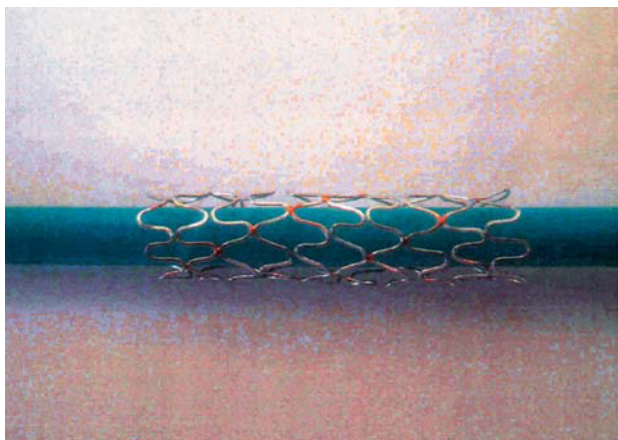
platinum and 10% iridium) and two parallel rows of gold point welds (less than 1% of the surface in contact with the arterial wall is gold, the rest is platinum). The metal coverage of the artery is 14.3% (Figure 1).

Various studies have been made with different platinum stents (angiostent).<sup>6,7</sup> Platinum is a biocompatible metal that, in principle, shows less tendency to platelet adhesion and thrombosis.

Tubular stents of stainless steel have less immediate elastic loss than coil type stents of nitinol and stainless steel,<sup>8,9</sup> a factor that contributes to the greater rate of restenosis with coil stents.

Correspondence: Dr. A. Abundes  
Carracci n.º 15, Colonia San Juan Mixcoac. 03730 México DF. México.

Received 3 January 2002.  
Accepted for publication 11 June 2002.



**Fig. 1.** Detail of the Atlas stent showing its sinusoidal configuration, flat wire, and gold weld points.

Changes in stent configuration are being tested,<sup>10</sup> particularly the material used in stent coatings (pyrolytic carbon, phosphorylcholine, silicon carbide<sup>11</sup>).

## METHODS

We clinically evaluated a platinum coil stent of improved design in our hospital that is more economical (Atlas stent).

It was implanted dismantled (diameters of 2.5, 3.0, 3.5 and 4.0 mm and lengths of 10, 18 and 25 mm) in 169 non-consecutive patients who had an indication for stent implantation.

The aim of the study was to assess the immediate clinical and angiographic result, presence of complications, clinical evolution, and appearance of major cardiac events (MACE) (death, myocardial infarction with or without Q wave, and need for urgent revascularization) during the hospital stay. Another aim of the study was to assess the long-term clinical and angiographic outcome.

We used conventional stent insertion techniques. All patients were premedicated with clopidogrel or ticlopidine and aspirin at optimal doses. During the procedure, intravenous unfractionated heparin was administered in therapeutic doses.

Studies were recorded on 35-mm cinema film and the angiographic measurements were made with calipers. We measured the reference arterial diameter, percentage of initial obstruction, residual diameter after angioplasty, diameter achieved with the stent, and the quality of coronary flow using the TIMI classification.

Angiographic controls were made according to the study protocol (more than 4 months), clinical indications, or the results of ischemia induction tests.

**TABLE 1. General characteristics**

	No.	(%)
Clinical history		
Diabetes mellitus	57	30
Smoking	86	50.6
Arterial hypertension	79	46.5
Hypercholesterolemia	62	36.5
Previous infarction	83	49.1
Previous revascularization	34	20.1
Clinical indication		
Unstable angina	102	60.4
Stable angina	42	24.9
Primary angioplasty	16	9.5
Infarction+successful thrombolysis	9	5.3
Total	169	169
Number of treated vessels		
One vessel	59	35
Two vessels	76	45
Three vessels	34	20
Total	169	
Coronary arteries treated		
Right coronary	70	30
Anterior descending coronary	71	39
Circumflex	33	18
Other	9	5
Total	183	
Type of lesions treated		
Type A	3	1.03
Type B2	91	46.9
Type B1	37	19
Type C	63	32.4
Total	194	
Total occlusions	47	24
Stent diameters, mm		
2.5	2	0.88
3	82	36.3
3.5	105	46.4
4	37	16.3
Total	226	
Stent length, mm		
12	52	23
18	157	69.5
25	17	7.5

## RESULTS

From February 1999 to December 2000, a total of 887 stents were implanted in our service. In 169 patients, 226 Atlas stents were implanted (19%) for the treatment of 194 lesions in 183 coronary arteries. An average of 1.3 stent was implanted per patient. The mean age was 60.10.8 years and 135 patients were men. The clinical history, indications, number of treated vessels, artery treated, type of lesion, and stent diameters and lengths are shown in Table 1. The angiographic characteristics of the lesions before and after the procedure are summarized in Table 2.

**TABLE 2. Angiographic characteristics of treated lesions**

Percentage obstruction	77.04±15.54
Length, mm	16.6±10.9
Minimum luminal diameter, mm	0.76±0.53
Reference diameter, mm	3.2±0.36
Final post-stent diameter, mm	3.4±0.33
Total occlusions, %	24

**TABLE 3. Clinical follow-up (14.1±6.8 months) of 86% of the initial patient group**

ACC functional class	No.	%
I	119	94.4
II	6	4.7
III	1	0.8
MACE		
New revascularization	14	11
Unstable angina	5	4
Acute infarction	0	0
Death	1	1
Total number of MACE	20	16

MACE indicates major adverse cardiac events.

Only 9.5% of the stents were implanted directly. In 95.6% of the cases treated with stents the final coronary flow was TIMI 3.

Immediate success was obtained in 98.8% of cases (Figures 2 and 3); 2 patients had acute intra-stent thrombosis.

In 6 cases the Atlas™ stent became deformed, but this did not affect the angiographic result or procedure. Catheterization was repeated in 2 patients without producing restenosis.

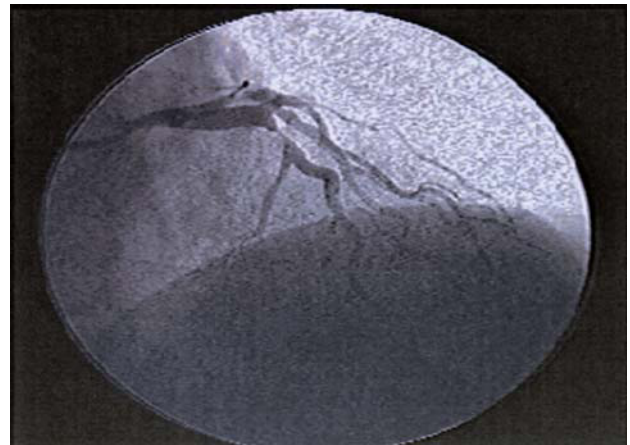
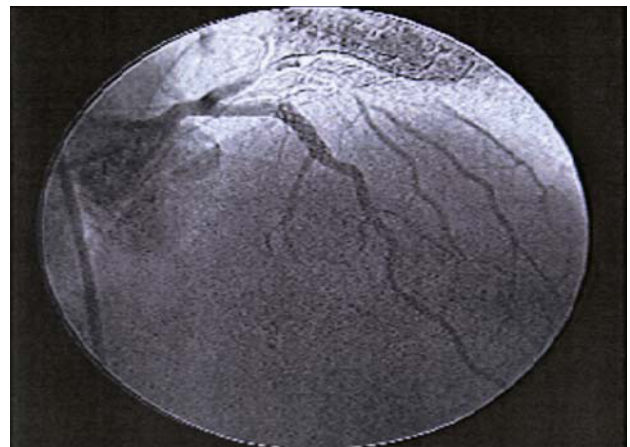
Control coronary arteriography was performed on 40.9% of all patients in 8.44.1 months. In 76.4%, arteriography was performed in compliance with the protocol, in 11.7% for symptoms, and in 11.7% due to the results of ischemia induction tests. In the analysis of this subgroup, angiographic restenosis was documented in 27.9% of cases. In 2.15%, angiographic evaluation was not possible.

The clinical follow-up of 126 patients (85.79%) was carried out at an average of 14.136.89 months (Table 3).

## DISCUSSION

Stents reduce the incidence of restenosis<sup>12,13</sup> and improve results in ostial lesions,<sup>14</sup> total chronic lesions,<sup>15</sup> saphenous bridges,<sup>16</sup> and, as a provisional measure<sup>17</sup> compared with conventional angioplasty.

In order to reduce costs, De Scheerder et al<sup>18</sup> tried a stent made by them with good results.

**Fig. 2.** Anterior descending coronary artery with a proximal type B1 lesion of 90%.**Fig. 3.** Result after implantation of the Atlas stent with respect to the diagonal branch and the radiopacity of the stent.

Our initial experience was with a stainless steel coil type stent, in phase I-IV of investigation.<sup>19,20</sup> The stent was improved by changes in design and material. Platinum is more ductile, non-corrosive, and has less elastic recoil and thrombogenicity.<sup>21</sup> In addition, it does not produce allergic reactions.<sup>22</sup> Its radiopacity facilitates implant assessment, but interferes with the angiographic evaluation of intimal proliferation. Platinum is non-corrosive.<sup>23</sup> In addition, platinum is not ferromagnetic, so it does not interfere with magnetic resonance imaging.

With the Atlas stent we achieved an angiographic and clinical success rate that was similar to reports in the literature.<sup>12,13</sup>

Our work has methodological limitations that preclude reaching definitive conclusions with regard to the percentage of restenoses. Nevertheless, the results were encouraging and at our hospital this stent is an effective alternative that was useful for reducing the cost of stent implantation.

## ACKNOWLEDGMENTS

We would like to thank Mr. German Quintana, Dr. Alonso Autrey, Dr. José Navarro, and the engineer Daniel Capuano.

The authors participated in the development of stent, but claim that they do not have any potential economic conflict of interest in relation to the device evaluated.

## REFERENCES

1. Pepine C, Holmes D, Block P, Mullins CH, Brinker J, Nissen S, et al. ACC Expert Consensus Document. Coronary Artery Stent. J Am Coll Cardiol 1996;28:782-94.
2. Sousa Amanda GMR. Latin American Society of Interventional Cardiology. Am J Cardiol 2000;86:41i.
3. Kimmel SE, Localio AR, Krone RJ, Laskey WK. The effects of contemporary use of coronary stents on in-hospital mortality. Registry Committee of the Society for Cardiac Angiography and Interventions. J Am Coll Cardiol 2001;37:499-504.
4. Keane D, Roubin G, Marco J, Fearon N, Serruys PW. GRACE-Gianturco Roubin stent acute closure evaluation: substrate challenges and desing of a randomized trial of bailout management. J Interv Cardiol 1994;7:333-9.
5. Abundes VA, Quintana G, Navarro RJ. Experimentación con un stent de platino fabricado en México. En: García MC, Reyes MH, Viniegra VL editores. Las múltiples facetas de la investigación en salud: proyectos estratégicos del Instituto Mexicano del Seguro Social. México DF: Editorial Sestante, S.A. de CV, 2001; p. 71-90.
6. Hijazi ZM, Homoud M, Aronvitz MJ, Smith JJ, Faller GT. A new platinum balloon- expandable stent (Angiostent) mounted on high pressure balloon: acute and late result in an atherogenic swine model. J Invasive Cardiol 1995;7:127-34.
7. Tamburino FR, Glassi AR, Russo G, Nicosia A, Grassi R, Monaco A, et al. Safety, feasibility and efficacy of a new single-wire stent in the treatment of complex coronary lesions: the angiostent. Cardiologia 1998;43:725-30.
8. Withe CJ. Stent recoil: comparison on Wiktor-GX coil and Palmaz-Schatz tubular coronary stent. Cathet Cardiovasc Diagn 1997; 41:1-3.
9. Pompa JJ, White CH, Pinkerton CA. Effect of balloon expandable stent design vascular recoil and lesions-site morphology after intracoronary placement [abstract]. Circulation 1992;86(Suppl): I321.
10. Iñíguez A, García E, Seabra R, Bordes P, Bethencourt A, Rigla J. Evolución hospitalaria y a medio plazo en pacientes tratados con implante de stent NIR: experiencia del registro multicéntrico ES-PORT-NIR. Rev Esp Cardiol 2001;54:557-66.
11. Fournier JA, Calabuig J, Merchan A, Auge JM, Melgares R, Colman T, et al. Resultados iniciales y seguimiento clínico a 6 meses tras el implante de un stent coronario recubierto de carburo de silicio. Rev Esp Cardiol 2001;54:567-72.
12. Serruys PW, de Jaegere P, Kiemeneij F, Macaya C, Rutsch W, Heyndrickx G, et al. A comparison of balloon-expandable-stent implantation with balloon angioplasty in patients with coronary artery disease. N Engl J Med 1994;331:489-95.
13. Fischman D, Martin L, Baim D, Schatz R, Savage M, Penn I, et al. A randomized comparison of coronary-Stent placement and balloon angioplasty in the treatment of coronary artery disease. N Engl J Med 1994;331:496-501.
14. Rocha-Shing K, Morris N, Wong SC, Schatz R, Teirstein P. Coronary stenting for treatment of ostial stenoses of native coronary arteries or aortocoronary saphenous venous grafts. Am J Cardiol 1995;75:26-9.
15. Sirnes PA, Golf S, Myreng Y, Molstad P, Emanuelsson H, Albertsson P, et al. Stenting in chronic coronary occlusion (SICCO): a randomized, controlled trial of adding stent implantation after successful angioplasty. J Am Coll Cardiol 1996;28:1444-51.
16. Savage MP, Douglas JS, Fischman DL, Pepine CJ, King SB III, Werner JA, et al. Stent placement compared with balloon angioplasty for obstructed coronary bypass grafts. Saphenous vein *de novo* trial investigators. N Engl J Med 1997;337:740-7.
17. Anderson HV, Carabello BA. Provisional *versus* routine stenting: routine stenting is here to stay. Circulation 2000;102:2910-4.
18. De Scheerder IK, Wang K, Kerdinchai P, Desmet W, Dens J, Supanantaroek C, et al. Clinical and angiographic outcome after implantation of a home-made stent for complicated coronary angioplasty. Cathet Cardiovasc Diagn 1997;42:339-47.
19. Abundes Velasco A, Quintana Pena G, Navarro Robles J, Autrey Caballero A, Velez y Tello de Meneses M, Ledesma Velasco M, et al. Desarrollo y diseño de un stent (SAQ) para el tratamiento de obstrucciones arteriales aterosclerosas coronarias. Arch Inst Cardiol Mex 1998;68:370-6.
20. Abundes Velasco A, Quintana Pena G, Navarro Robles J, Ledesma Velasco M, Autrey Caballero AL, Solorio Maza S, et al. Estudio piloto preliminar en humanos con la prótesis endovascular (Stent SAQ). Resultados inmediatos y a mediano plazo. Arch Inst Cardiol Mex 2000;70:377-83.
21. Kim S, Park H, Lee Y, Chung W, Han C. An experimental study on thrombogenicity of various metallic microcoils with or without thrombogenic coatings. Invest Radiol 1998;33:407-10.
22. Kansu, G, Aydin AK. Evaluation of the various dental alloys: Part 2-Allergenic Potentials. Eur J Prosthodont Restor Dent 1996;4:155-66.
23. Venugopalan R. Corrosion testing of stents: a novel fixture to hold entire device in deployed from and finish. J Biomed Mater Res 1999;48:829-32.