

In conclusion, our study suggests that LAAO with other combined transseptal procedures was feasible and safe but was associated with suboptimal device deployment. Therefore, in the absence of the coaxial LAA approach, a second TSP should be performed to achieve an optimal LAAO. Further studies will be necessary to confirm the observed results.

FUNDING

The present study did not receive any funding.

AUTHORS' CONTRIBUTIONS

X. Freixa and L. Sanchis conceived the study. L. Sanchis reviewed the patients' medical records and echocardiographic images. P. Cepas-Guillén contributed to completing the database and patient review. X. Freixa, A. Regueiro, M. Sabaté and M. Sitges critically supervised the initial findings and critically reviewed the initial draft of the manuscript written by L. Sanchis. All authors discussed the results and contributed to the final manuscript.

CONFLICTS OF INTEREST

L. Sanchis, M. Sitges and X. Freixa are proctors of Abbott.

Laura Sanchis,^{a,b,c,*} Ander Regueiro,^{a,b,c} Pedro Cepas-Guillén,^{a,b,c} Manel Sabaté,^{a,b,c,d} Marta Sitges,^{a,b,c,d} and Xavier Freixa^{a,b,c}

^aDepartamento de Cardiología, Instituto Cardiovascular, Hospital Clínic de Barcelona, Barcelona, Spain

^bFacultat de Medicina, Universitat de Barcelona, Barcelona, Spain

^cInstitut d'Investigacions Biomèdiques August Pi i Sunyer (IDIBAPS), Barcelona, Spain

^dCentro de Investigación Biomédica en Red de Enfermedades Cardiovasculares (CIBERCV), Spain

* Corresponding author:

E-mail address: lsanchis@clinic.cat (L. Sanchis).

Available online 9 October 2021

REFERENCES

1. Glikson M, Wolff R, Hindricks G, et al. EHRA/EAPCI expert consensus statement on catheter-based left atrial appendage occlusion - An update. *EuroIntervention*. 2020;15:1133–1180.
2. D'Amico G, Estèvez-Loureiro R, Rofastes XF, et al. Combined Procedure of Percutaneous Mitral Valve Repair and Left Atrial Appendage Occlusion: A Multicenter Study. *JACC Cardiovasc Interv*. 2021;14:590–592.
3. Mohanty S, Gianni C, Trivedi C, et al. Risk of thromboembolic events after percutaneous left atrial appendage ligation in patients with atrial fibrillation: Long-term results of a multicenter study. *Heart Rhythm*. 2020;17:175–181.
4. Freixa X, Cepas-Guillén P, Flores-Umanzor E, et al. Impact of Pulmonary Ridge Coverage after Left Atrial Appendage Occlusion. *EuroIntervention*. 2021;16:e1288–e1294.

<https://doi.org/10.1016/j.rec.2021.08.005>

1885-5857/ © 2021 Sociedad Española de Cardiología. Published by Elsevier España, S.L.U. All rights reserved.

Initial experience with left bundle branch area pacing in patients with transthyretin cardiac amyloidosis



Experiencia inicial en estimulación en el área de la rama izquierda en pacientes con amiloidosis cardíaca por transtirretina

To the Editor,

We are witnessing an increase in the understanding of cardiac amyloidosis due to abnormal deposits of the protein transthyretin (ATTR), both its hereditary form and acquired (or senile) form. Current data from Spain indicate that ATTR is the most common type of cardiac amyloidosis. Heart failure (HF) is the most frequent presentation and close to 35% of patients will have deterioration in left ventricular ejection fraction (LVEF) and short survival.¹ Furthermore, a substantial number of patients with ATTR have conduction system abnormalities (7% have advanced atrioventricular block) or left ventricular systolic dysfunction.² Previous studies have shown a deleterious effect from frequent ventricular pacing and a clinical benefit from cardiac resynchronization therapy (CRT) in selected patients with ATTR.³ Recently, physiological pacing of the left bundle branch (LBBP) has become a safe, feasible alternative for those who require antibradycardia treatment or CRT.⁴ Our objective was to study the technical viability of LBBP in ATTR and analyze its clinical effects in a pilot experience. The study was approved by the Granada province Research Ethics Committee. Patients gave written consent for study participation and publication.

We present 3 patients with ATTR, HF, and left ventricular systolic dysfunction requiring permanent ventricular pacing; because they remained symptomatic, LBBP was performed with

the aim of optimizing CRT and preventing LVEF deterioration as a consequence of the permanent pacing (table 1).

The first patient was an 83-year-old man with acquired ATTR who had a syncopal episode caused by sinus node dysfunction (SND) and nodal escape, with slight wall hypertrophy and mildly reduced LVEF. The patient had a dual chamber pacemaker, and 2 years later, in light of the etiological diagnosis, development of atrioventricular disease, and LVEF deterioration requiring permanent pacing, he was changed to conventional CRT. His progress was unfavorable, and he developed atrial fibrillation, had a deterioration in functional class and was hospitalized for HF, triggering the decision to use LBBP.

The second patient was a 72-year-old man with hereditary ATTR (p.Val142Ile variant) and paroxysmal atrial fibrillation with a severe deterioration in HF functional class since the diagnosis of the disease (1 admission and 2 visits to the emergency department for HF). He subsequently developed atrioventricular block, and was treated with LBBP with the aim of avoiding LVEF deterioration.

The third patient was an 84-year-old man who was under follow-up for ventricular hypertrophy of unknown etiology since diagnosis 4 years prior. During the follow-up, he developed difficult-to-control persistent atrial fibrillation, left bundle branch block, and progressive left ventricular systolic dysfunction. After the onset of the syncopal sinus node dysfunction, a CRT device was implanted (QRSd, 160 ms). Eventually, 1 year later, once considered a nonresponder and with deterioration in functional class, it was decided to use LBBP, and a QRSd of 140ms was obtained (figure 1).

In the 3 patients, a guide catheter was used for septal pacing (C315 HIS, Medtronic Inc, USA). Over that, a lead was introduced (Select-Secure model 3830 69 cm, Medtronic Inc., USA), connected to the polygraph to record intracavity signal. The guide catheter was positioned 2 cm apically to the His bundle electrogram and,

Table 1

Baseline characteristics and outcomes at 3 months after the start of LBBP treatment

	Patient 1	Patient 2		Patient 3		
Sex	Male	Male		Male		
Age, y	83	72		84		
Type of ATTR	Acquired	Hereditary (p.Val142Ile)		Acquired		
Carpal tunnel syndrome	+	+		-		
Polyneuropathy	+	+		-		
Hypertension	+	+		-		
Pulmonary hypertension	-	+		-		
Glomerular filtration rate < 45 mL/min/1.73 m ²	+	+		+		
CVE	-	-		-		
AF	Permanent	Paroxysmal		Paroxysmal		
Indication	SND	cAVB		SND		
Treatment						
RAASI	No	Enalapril		Candesartan		
Beta-blockers	No	No		Bisoprolol		
MRA	Spironolactone	No		Spironolactone		
Tafamidis	No	Yes		No		
Diuretics	Furosemide 120 mg	Furosemide 120 mg		Furosemide 80 mg		
SGLT2i	No	No		No		
Rhythm	Permanent AF	Permanent AF		Paroxysmal AF		
Previous device	CRT-P (basal inferolateral coronary sinus)	No		CRT-P (mid inferolateral coronary sinus)		
	Baseline	3 mo	Baseline	3 mo	Baseline	3 mo
NYHA	III	II	IV	III	III	II
LVEF, %	37	37	43	57	30	49
QRS, ms	156	128	186	138	248	148
BNP, pg/mL	1513	1411	1469	1150	959	564
Emergency department visits due to cardiac cause (6 mo)	2	1	2	0	1	0
Hospitalization for HF (1 y)	1	0	1	0	0	0
[0,1-7]Electric parameters relating to left bundle branch pacing						
QRSd, ms	128	138		148		
LVAT, ms	88	92		96		
Left bundle capture threshold, V × 0.4 ms	0.75	0.75		1		
Mode	VVIR	DDD		DDDR		
Percentage ventricular pacing	97	99.6		99.9		

AF, atrial fibrillation; ATTR, transthyretin amyloidosis; BNP, brain natriuretic peptide; cAVB, complete atrioventricular block; CRT-P, cardiac resynchronization therapy; CVE, cerebrovascular event; HF, heart failure; LVAT, left ventricular activation time; LVEF, left ventricular ejection fraction; MRA, mineralocorticoid receptor antagonists; NYHA, New York Heart Association functional class; RAASI, renin-angiotensin-aldosterone system inhibitors; SGLT2i, sodium-glucose cotransporter type 2 inhibitor; SND, sinus node dysfunction.

using 6 to 8 clockwise turns, the lead penetrated the interventricular septum until capture of the left bundle branch was achieved. In the 3 patients, the following 4 criteria were used for LBBP (figure 1):⁵

- Shortening of the spike-R wave interval in V6
- rsr'/rsR' morphology in V1
- Narrowing of the QRS complex after septal penetration
- Change in selective-nonselective capture

In our experience, the success rate of the implant was 100%, with no incidents of note. In all cases, a paced QRS that was narrower than before was achieved.

Although the 3 patients were of advanced age, had atrial fibrillation (paroxysmal in 2 and permanent in 1), chronic kidney disease (stage G3a), and advanced HF (New York Heart Association [NYHA] functional class III-IV/IV), at 3 months after starting LBBP, all had improved functional class, with a slight reduction in natriuretic peptide levels (table 1). Regarding LVEF, 2 patients had an increase,

but the first did not. Lastly, although statistical inferences are not possible due to the small sample size, there was a reduction in the number of hospitalizations after 1 year and emergency department visits for HF at 6 months after LBBP (table 1).

In conclusion, this study is limited by its small sample size, its retrospective design, the variability in echocardiographic measurements, and the short follow-up. However, in our initial small cohort of patients with ATTR, LBBP proved to be a viable and effective therapeutic option in the short-term (3 months) for the optimization of CRT and which allowed improvement in HF symptoms. This hypothesis should be confirmed in larger, prospective studies.

FUNDING

This study did not receive any specific funding from public sector, commercial, or not-for-profit funding bodies.

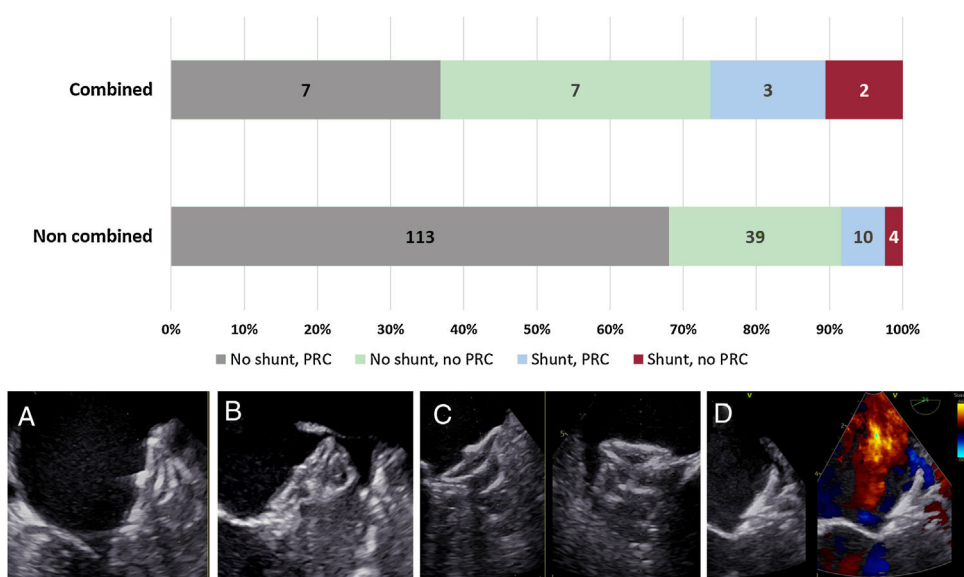


Figure 1. A: baseline electrocardiogram with first-degree AVB and right bundle branch block and left axis deviation. B: LBBP; typical rsr' morphology with normal axis. C: typical "W" morphology in V1 before lead penetration of IVS. D: initial penetration of the IVS with shortening of the paced QRS interval (212 ms) and of the LVAT interval (162 ms). E: capture of the left bundle with rsr' morphology in V1, narrower QRS interval (148 ms) and shorter LVAT (108 ms). AVB, atrioventricular block; IVS, interventricular septum; LBBP, left bundle branch pacing; LVAT, left ventricular activation time. gr1.

AUTHORS' CONTRIBUTIONS

F.J. Bermúdez-Jiménez collected and analyzed the data; he wrote the manuscript with the help of the other authors. M. Molina-Lerma and P. Sánchez-Millán performed and supervised the technical procedures. J. Jiménez-Jáimez and R. Macías-Ruiz conceived the idea presented. M. Álvarez supervised the overall process. All authors discussed the results and contributed to the final manuscript.

CONFLICTS OF INTEREST

The authors have nothing to declare.

Francisco José Bermúdez-Jiménez,^{a,b,c,*} Manuel Molina-Lerma,^{a,b} Rosa Macías-Ruiz,^{a,b} Pablo Sánchez-Millán,^{a,b} Juan Jiménez-Jáimez,^{a,b} and Miguel Álvarez^{a,b}

^aServicio de Cardiología, Hospital Universitario Virgen de las Nieves, Granada, Spain

^bInstituto de Investigación Biosanitaria ibs.GRANADA, Granada, Spain

^cCentro Nacional de Investigaciones Cardiovasculares (CNIC), Madrid, Spain

* Corresponding author:

E-mail address: bermudezfrancisco23y@gmail.com

(F.J. Bermúdez-Jiménez).

Available online 9 October 2021

REFERENCES

1. López-Sainz Áaue, Hernandez-Hernandez A, Gonzalez-Lopez E, et al. Clinical profile and outcome of cardiac amyloidosis in a Spanish referral center. *Rev Esp Cardiol.* 2021;74:149–158.
2. González-López E, Gagliardi C, Dominguez F, et al. Clinical characteristics of wild-type transthyretin cardiac amyloidosis: disproving myths. *Eur Heart J.* 2017;38:1895–1904.
3. Donnellan E, Wazni OM, Hanna M, Kanj M, Saliba WI, Jaber WA. Cardiac Resynchronization Therapy for Transthyretin Cardiac Amyloidosis. *J Am Heart Assoc.* 2020;9:e017335.
4. Zanon F, Pastore G, Marcantoni L. Estimulación por marcapasos del haz de His: el mito se hace realidad. *Rev Esp Cardiol.* 2020;73:611–614.
5. Wu S, Chen X, Wang S, et al. Evaluation of the criteria to distinguish left bundle branch pacing from left ventricular septal pacing. *JACC Clin Electrophysiol.* 2021. <http://doi.org/10.1016/j.jacep.2021.02.018>.

<https://doi.org/10.1016/j.rec.2021.08.016>

1885-5857/ © 2021 Sociedad Española de Cardiología. Published by Elsevier España, S.L.U. All rights reserved.

Fluoroscopic-based algorithm for commissural alignment assessment after transcatheter aortic valve implantation

Método para la evaluación angiográfica del alineamiento comisural tras el implante percutáneo de válvula aórtica

To the Editor,

Recently, different strategies have been described for achieving commissural alignment during transcatheter aortic valve implan-

tation (TAVI).^{1–3} Computed tomography (CT) is the most accurate imaging technique to measure final orientation after TAVI implant. However, post-TAVI CT is not performed routinely and not clinically justified. Other strategies like co-registry of pre-TAVI CT and fluoroscopy could be useful but are not the standard of care.¹ We propose an algorithm to identify the final position of TAVI devices with recognizable commissural markers relying only in fluoroscopy with a resolution of 15° degrees.

Using a CT derived aortic root simulation, different rotational orientations of a virtual TAVI device were tested, ranging from

