

3. Zange L, Muehlberg F, Blaszczyk E, et al. Quantification in cardiovascular magnetic resonance: agreement of software from three different vendors on assessment of left ventricular function, 2D flow and parametric mapping. *J Cardiovasc Magnet Reson.* 2019;21:12.
4. Clay S, Alfakih K, Messroghli DR, Jones T, Ridgway JP, Sivananthan MU. The reproducibility of left ventricular volume and mass measurements: a comparison between dual-inversion-recovery black-blood sequence and SSFP. *Eur Radiol.* 2006;16:32–37.
5. Suinesiaputra A, Bluemke DA, Cowan BR, et al. Quantification of LV function and mass by cardiovascular magnetic resonance: multi-center variability and consensus contours. *J Cardiovasc Magnet Reson.* 2015;17:63.
6. Kim RJ, Fieno DS, Parrish TB, et al. Relationship of MRI Delayed Contrast Enhancement to Irreversible Injury, Infarct Age, and Contractile Function. *Circulation.* 1999;100:1992–2002.

<https://doi.org/10.1016/j.rec.2022.06.009>
1885-5857/

© 2022 Published by Elsevier España, S.L.U. on behalf of Sociedad Española de Cardiología.

Insertion of implantable miniaturized cardiac monitors by qualified nurses in an ambulatory setting



Inserción de monitores cardíacos implantables de forma ambulatoria por personal de enfermería cualificado

To the Editor,

Major research on insertable cardiac monitors (ICMs) has focused on simplifying the insertion procedure while increasing ICM performance with more accurate detection algorithms. The

marked size reduction of ICMs has allowed minimally invasive insertion in the subcutaneous tissue.¹ These improvements have opened the door for this procedure to be performed by qualified professionals such as certified nurses, which could result in more efficient time and resource management, potentially reducing waiting lists.¹

“ICM nurse” is an ongoing multicenter, prospective, single-arm, open-label study to assess the safety and efficacy of the ICM BIOMONITOR III and IIIm (Biotronik, Germany) at 2 centers in Spain. This interim analysis presents short-term data on the feasibility of ambulatory nurse-led ICM insertions by

Table 1
Clinical and demographic characteristics and insertion data of the study participants

Variables	Nurse n = 20	Physician n = 27	P
Age, y	63.4 ± 10.8	74.2 ± 11.8	.002
Weight, kg	79.4 ± 20.6	72.5 ± 11.2	.187
NYHA class ^a (n = 46)			.0001
I	17 (89.5)	7 (25.9)	
II	1 (5.3)	15 (55.6)	
II-III	1 (5.3)	3 (11.1)	
III	0	2 (7.4)	
ICM indication ^b			.0001
Suspected AF	1 (5.0)	2 (7.4)	
Syncope of unknown cause	7 (35.0)	6 (22.2)	
Recurrent palpitations	1 (5.0)	3 (11.1)	
Cryptogenic stroke	11 (55.0)	0	
Post-AF ablation monitoring	1 (5.0)	1 (5.0)	
Suspicion of cardiac conduction disorder	0	5 (18.5)	
Other	0	11 (40.7)	
Symptoms	7 (35.0)	20 (74.1)	.007
Syncope	5 (71.4)	6 (30.0)	
Dizziness	1 (14.3)	9 (45.0)	
Palpitations	1 (14.3)	3 (15.0)	
Dyspnea	0	2 (10.0)	
History of AF			
None	17 (85.0)	18 (66.7)	.121
Paroxysmal	3 (15.0)	4 (14.8)	
Persistent	0	5 (18.5)	
Previous AF ablation	1 (5.0)	0	.240
History of thromboembolic events or stroke			.0001
None	10 (50.0)	25 (92.6)	
Stroke	9 (45.0)	2 (7.4)	
Transient ischemic attack	1 (5.0)	0	
Comorbidities ^b			
COPD	4 (20.0)	1 (3.7)	.073

Table 1 (Continued)

Clinical and demographic characteristics and insertion data of the study participants

Variables	Nurse n = 20	Physician n = 27	P
Diabetes mellitus	3 (15.0)	6 (22.2)	.638
Stroke	11 (55.0)	2 (7.4)	.0001
Hypertension	8 (40.0)	20 (74.1)	.019
Hypercholesterolemia	9 (45.0)	13 (48.1)	.831
Obesity	6 (30.0)	4 (14.8)	.209
Renal insufficiency	2 (10.0)	6 (22.2)	.270
Liver insufficiency	2 (10.0)	1 (3.7)	.383
Family history of cardiovascular disease	6 (30.0)	7 (41.2)	.478
<i>Insertion position</i>			
Position A	7 (35.0)	19 (70.4)	.016
Position B	13 (65.0)	8 (29.6)	
Caudal–cranial	7 (35.0)	20 (74.1)	.007
Cranial–caudal	13 (65.0)	7 (25.9)	
<i>Insertion time (skin cut to wound closure)</i>			
< 1 min	1 (5.0)	0	.010
1–5 min	12 (60.0)	6 (22.2)	
> 5 min	7 (35.0)	21 (77.8)	
<i>Insertion time (anesthesia to insertion tool removal)</i>			
< 5 min	8 (40.0)	8 (29.6)	.339
5–10 min	9 (45.0)	18 (66.7)	
10–15 min	2 (10.0)	1 (3.7)	
15–20 min	1 (5.0)	0	
<i>Ease of insertion</i>			
Very easy	5 (25.0)	17 (63.0)	.008
Easy	9 (45.0)	10 (37.0)	
Normal	5 (25.0)		
Difficult	1 (5.0)		
<i>Wound closure methods</i>			
Adhesive strips	11 (55.0)	24 (88.9)	.027
Staples	8 (40.0)	3 (11.1)	
Intradermal stitches	1 (5.0)	0	
<i>Complications</i>			
None	17 (85.0)	27 (100.0)	
Insertion site pain	3 (15.0)		

AF, atrial fibrillation; COPD, chronic obstructive pulmonary disease; ICM; insertable cardiac monitor; NYHA, New York Heart Association.

The data are expressed as No. (%) or mean ± standard deviation.

^a Number of patients with available data.^b Patients could present more than one cause/comorbidity.

showing acute procedural success, wound healing, and ICM performance. Data were collected at baseline, at patient discharge, and after 1 week (on-site or remotely as per routine clinical practice). Insertion results were compared with retrospective data on insertions performed by physicians. Patients rated their satisfaction with the procedure performed by nurses via a 12-item purpose-made questionnaire. The study was approved by the ethics committee of Hospital Puerta de Hierro (Madrid, Spain). All participants provided informed consent.

Inclusion criteria consisted of age > 18 years and an indication for ICM insertion. Exclusion criteria were an existing axillary or inframammary implant, indication for pacemaker or implantable cardioverter-defibrillator, compromised immunological system or risk of developing an infection, participation in another interventional study, pregnancy or breastfeeding, life expectancy

< 12 months, or thoracic anatomy that could compromise the procedure.

BIOMONITOR III and III_m have a longer sensing vector and a miniaturized profile (77.5 mm x 8.6 mm x 4.6 mm; 4 g) that enables 1-step insertion. Insertions were performed using local anesthesia, following the routine procedures of participating centers.

Forty-seven participants were included in the study (ICM implantations were performed by nurses in 20 patients and by physicians in 27), and insertion was successful in all (table 1). Insertions in the nurse group were performed by 3 nurses (2 at *Hospital General Universitario Dr Balmis de Alicante* and 1 at *Hospital Universitario Puerta de Hierro de Madrid*) with a mean experience of 9.7 years in the electrophysiology laboratory.

The time from skin cut to wound closure was > 5 minutes in 35.0% of the insertions performed by nurses and in 77.8% of those

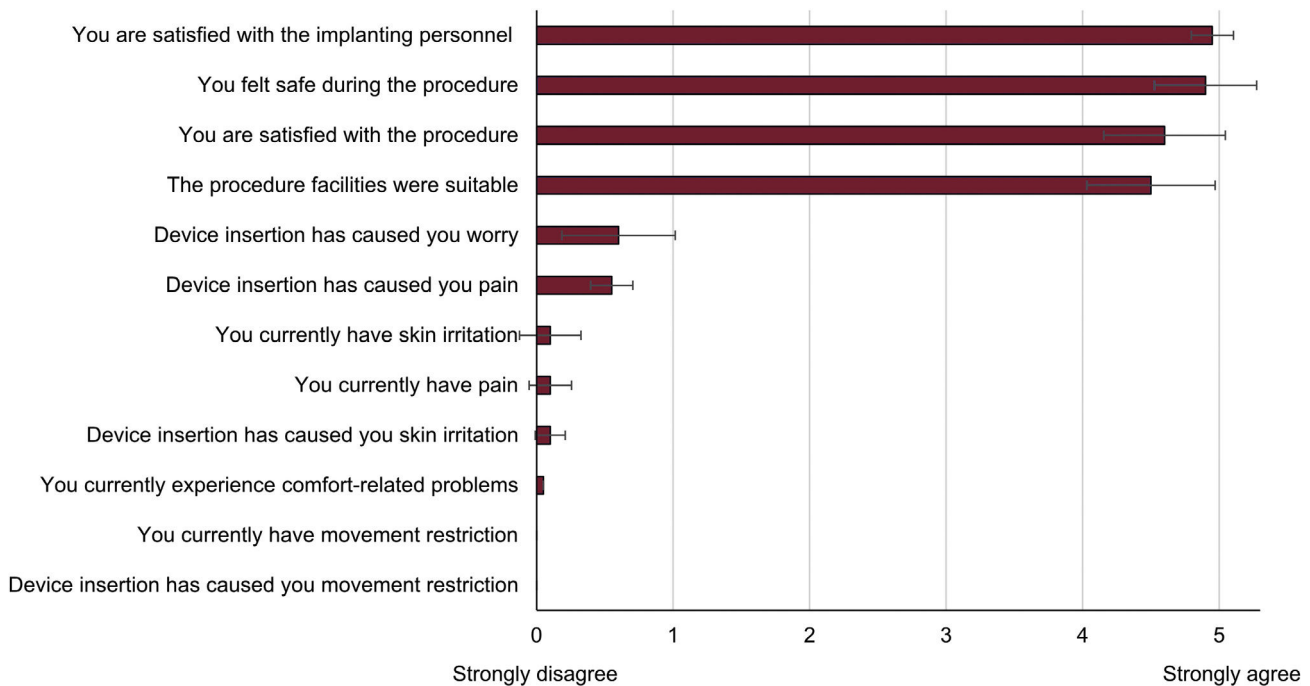


Figure 1. Patient satisfaction with the procedure.

performed by physicians ($P = .010$). The wound was closed by adhesive strips in 55.0% of the insertions performed by nurses vs 88.9% of those carried out by physicians, by staples in 40.0% vs 11.1% of insertions, and by intradermal stitches in 5.0% vs 0% of insertions ($P = .027$). The insertion procedure was rated as 'very easy/easy' by nurses in 70.0% of cases and in 100% of cases by physicians (table 1).

The only complication reported during the procedure was insertion site pain (3 patients in the nurse group, 15.0%) (table 1). Only 1 wound-related adverse event was reported (device migration) in the nurse group after 1 week of device insertion, followed by an external device repositioning. The ICM was explanted in 1 patient due to detection of atrial fibrillation.

The mean R-wave amplitude was 0.60 ± 0.24 mV in the nurse group and 0.56 ± 0.31 in the physician group at device insertion ($P = .274$). P-waves were visible in 19 (95.0%) patients in insertions performed by nurses and in 20 (74.1%) patients in insertions performed by physicians at device insertion ($P = .059$).

Overall patient satisfaction with insertions performed by nurses was high: implanting personnel (4.95 ± 0.22), facilities (4.50 ± 0.89) and safety (4.90 ± 0.31) (figure 1).

The device detected 3 arrhythmias in the nurse group: 2 episodes of atrial fibrillation and 1 high ventricular rate. One patient showed paroxysmal atrial fibrillation with recurrent episodes that resulted in a supraventricular episode with rapid ventricular response, and another patient showed atrial fibrillation detected 1 week after device insertion.

This is the first clinical study suggesting that certified nurses can safely insert the BIOMONITOR III and IIIm in an ambulatory setting by using a short and simple procedure, with high patient and implanter satisfaction, no severe acute complications, and large signal amplitudes. The main limitations of the study are the small patient cohort analyzed and the comparison of data with a retrospective cohort.

The time from skin cut to wound closure (1-5 min in 60% of insertions performed by nurses vs 22.2% performed by physicians)

is within the range of 3.6 minutes previously reported with the BIOMONITOR III implanted by physicians in cardiac catheterization laboratories² and is substantially lower than the 7 to 9 minutes registered with the BioMonitor 2 inserted in cardiac catheterization laboratories.³ Differences in procedure length between nurses and physicians could be explained considering that physicians mostly performed the procedure in the operating room and nurses in an ambulatory setting.

Patients showed a high level of satisfaction with the procedure, with satisfaction being highest with the implanting personnel, followed by the safety felt during the procedure. The finding that the most valued aspect of the procedure was the implanting personnel could be due to the critical role played by nurses in establishing closer contact with patients. Moreover, the ambulatory setting could also be a more relaxed and less intimidating environment for the patient.

Safety data suggest no added risk for insertions performed by certified nurses, as only 3 patients experienced insertion site pain and there was only 1 wound-related adverse event, supporting the low complication rates previously reported in insertions performed by nurses and advanced practice providers.⁴

The mean R-wave amplitude of 0.60 mV supports the acute procedural success of insertions performed by nurses. P-waves were visible in 95.0% patients at device insertion, contrasting with the 58% reported with the Reveal LINQ (Medtronic Inc, United States)⁵ and 67% to 72% with the BioMonitor 2.⁶

In conclusion, the miniaturized implantable cardiac monitor BIOMONITOR III can be efficiently and safely inserted by certified nurses.

FUNDING

This work was supported by the Research Agency of the Spanish Society of Cardiology. The Research Agency of the Spanish Society of Cardiology received an unrestricted research grant from BIOTRONIK SE & Co. KG (Berlin, Germany). Medical Writing

services were supported by BIOTRONIK SE & Co. KG (Berlin, Germany).

AUTHORS' CONTRIBUTIONS

Concept and design: J.G. Martínez, I. Fernández Lozano. Acquisition, analysis, or interpretation of data: J.G. Martínez, J. de Andrés, I. Lillo, D. Veloza, H. Reig, I. Fernández Lozano. Drafting of the manuscript: J.G. Martínez, I. Fernández Lozano. Revision of the manuscript: J.G. Martínez, J. de Andrés, I. Lillo, D. Veloza, H. Reig, I. Fernández Lozano.

CONFLICTS OF INTEREST

J.G. Martínez has received honoraria for participating in advisory boards and presentations from Abbott. I. Fernández Lozano has received fees for fellowships from *Fundación de Investigación Hospitalaria and Sociedad Española de Cardiología* (SEC), and for clinical studies from Biotronik and Abbott. The remaining authors have no conflicts of interest to disclose.

Acknowledgements

The authors thank Alicia Moreno and Berta Mateos for the technical and statistical support provided. Carla Granados from Trialance SCCL provided medical writing assistance.

Juan Gabriel Martínez,^{a,*} Jesús de Andrés,^b Isabel Lillo,^a Darwin Veloza,^b Helena Reig,^a and Ignacio Fernández Lozano^b

^aUnidad de Arritmias, Servicio de Cardiología, Hospital General Universitario Dr. Balmis, Instituto de Investigación Sanitaria y Biomédica de Alicante (ISABIAL), Alicante, Spain
^bUnidad de Arritmias, Servicio de Cardiología, Hospital Universitario Puerta de Hierro, Majadahonda, Madrid, Spain

* Corresponding author.

E-mail address: martinez.juangabriel@gmail.com (J.G. Martínez).

Available online 8 July 2022

REFERENCES

- Giancaterino S, Lupercio F, Nishimura M, Hsu JC. Current and Future Use of Insertable Cardiac Monitors. *JACC Clin Electrophysiol*. 2018;4:1383–1396.
- Mariani JA, Weerasooriya R, van den Brink O, et al. Miniaturized implantable cardiac monitor with a long sensing vector (BIOMONITOR III): Insertion procedure assessment, sensing performance, and home monitoring transmission success. *J Electrocardiol*. 2020;60:118–125.
- Piorkowski C, Busch M, Nölker G, et al. Clinical evaluation of a small implantable cardiac monitor with a long sensing vector. *Pacing Clin Electrophysiol*. 2019;42:1038–1046.
- Lim WY, Papageorgiou N, Sukumar SM, et al. A nurse-led implantable loop recorder service is safe and cost effective. *J Cardiovasc Electrophysiol*. 2019;30:2900–2906.
- Maines M, Zorzi A, Tomasi G, et al. Clinical impact, safety, and accuracy of the remotely monitored implantable loop recorder Medtronic Reveal LINQ TM. *Europace*. 2018;20:1050–1057.
- Lacour P, Dang PL, Huemer M, et al. Performance of the New BioMonitor 2-AF Insertable Cardiac Monitoring System: Can Better be Worse? *PACE - Pacing Clin Electrophysiol*. 2017;40:516–526.

<https://doi.org/10.1016/j.rec.2022.07.003>
1885-5857/

© 2022 Sociedad Española de Cardiología. Published by Elsevier España, S.L.U. All rights reserved.

Propionic acidemia: a rare cause of dilated cardiomyopathy and long QT syndrome



Acidemia propiónica: una causa poco habitual de miocardiopatía dilatada y síndrome de QT largo

To the Editor,

Organic acidemias are among the rarer causes of dilated cardiomyopathy (DCM). They form a group of inherited metabolic diseases characterized by excessive accumulation of organic acids leading to systemic disease. Among this group, propionic acidemia is the type that frequently involves the heart. We present a case of DCM with a diagnosis of propionic acidemia. The patient gave informed consent to undergo tests and to the publication of the case, which was approved by the ethics committee of our hospital.

A 38-year-old woman was referred to the cardiology department because of a finding of DCM on echocardiography. The family history included a brother diagnosed with DCM of unidentified etiology, who died at 21 years of age while undergoing cardiac transplant (figure 1). The personal history referred to episodes of hypoglycemic ketotic crises in childhood and highlighted a diagnosis of chronic kidney disease of unclear etiology in 2015. In 2019, due to the progression of renal disease, renal transplant was performed without subsequent complications.

At the time of the diagnosis of DCM, the patient was in New York Heart Association (NYHA) functional class II, with a spherical dilated (end-diastolic diameter, 65 mm) left ventricle (LV) with severe LV systolic dysfunction (LV ejection fraction [LVEF], 33%)

and severe relaxation deficit with elevated filling pressures (E/E', 14) (figure 2). The electrocardiogram (ECG) showed a long QTc interval (figure 2). Coronary angiography showed no lesions.

A genetic study was performed using a general DCM panel (figure 1), which was negative. Decompensated heart failure was not observed on optimized drug therapy; in March 2021, the patient was in NYHA functional class I, had achieved partial echocardiographic remission with a slightly dilated LV (end-diastolic diameter, 59 mm) with a recovered LVEF (55%), and diastolic normalization (E/E', 7), but with decreased global longitudinal strain (figure 2). Improvement was seen on electrocardiography with QT shortening (figure 2).

In July 2021, the patient was admitted to the psychiatry department for behavioral disturbances. Brain magnetic resonance imaging (MRI) showed a hypersignal in the basal ganglia, so the patient was referred to neurology. The etiological study included a urine organic acid study; we highlight increases in 3-hydroxypropionic acid (146 mmol/mol creatinine; normal, < 5) and methylcitric acid (99 mmol/mol creatinine; normal, < 5), with normal levels of methylmalonic acid. Whole exome sequencing targeting genes related to propionate and biotin metabolism disorders showed 2 heterozygous mutations in the *PCCB* gene (figure 1). Both are described in the Human Gene Mutation Database. As predictors of pathogenicity, and according to the criteria of the American College of Medical Genetics, they are classified as pathogenic variants, thus confirming the diagnosis of propionic acidemia.

Propionic acidemia is an inherited autosomal recessive disease characterized by the accumulation of propionate and its metabolites due to mutations in propionyl-CoA carboxylase (PCC), which