

Image in cardiology

Intermittent Brugada Pattern in Relation to Changes in Body Temperature



Patrón de Brugada intermitente en relación con cambios en la temperatura corporal

Andre Dias,* Emiliana Franco, and Vincent M. Figueredo

Department of Cardiology, Einstein Medical Center, Philadelphia, Pennsylvania, United States

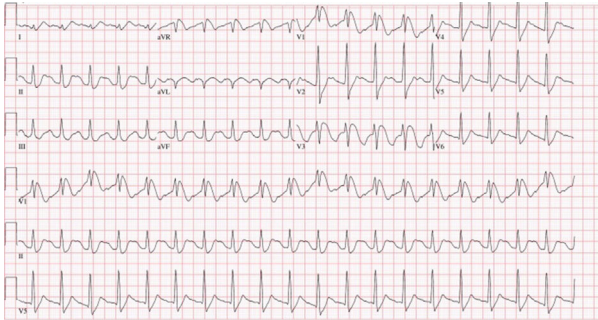


Figure 1.

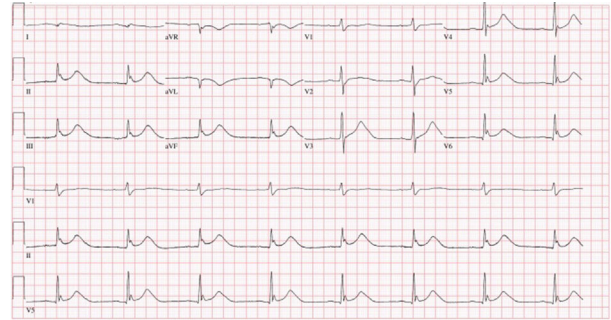


Figure 2.

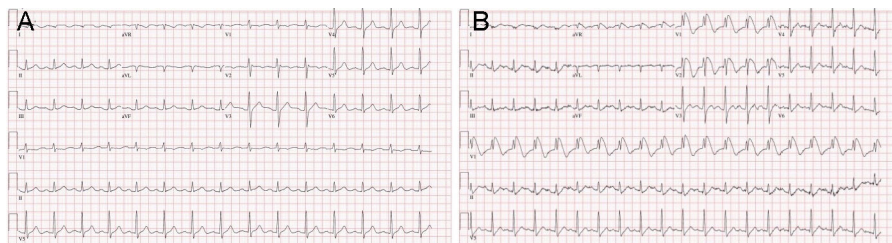


Figure 3.

A 31-year-old male patient with no significant past medical or family history presented to the emergency department after cardiorespiratory arrest witnessed at a restaurant by his family. As per emergency medical system records, initial rhythm was ventricular fibrillation. The patient was intubated and shocked 4 times in the field, which achieved a return of spontaneous circulation. Cardiopulmonary resuscitation was performed for 25 minutes. Electrocardiogram performed on arrival (Figure 1) suggested possible Brugada syndrome. The hypothermia protocol was started. Coronary angiography was still performed but no epicardial coronary artery disease was present. An electrocardiogram obtained during the cooling process showed sinus bradycardia with first degree atrioventricular block (Figure 2). After completion of the rewarming process, the patient returned to normal sinus rhythm (Figure 3A). Forty-eight hours later he complained of productive cough with yellowish sputum and shortness of breath and spiked a fever of 38.3 °C. A repeat electrocardiogram was once again compatible with Brugada syndrome (Figure 3B).

Of note, the patient's wife mentioned he had been experiencing flu-like symptoms the week prior to presentation.

* Corresponding author:
E-mail address: andremacdias@gmail.com (A. Dias).
Available online 2 February 2016