

Late Failure of Left Ventricular Leads Stabilized Using the Retained Guidewire Technique in Patients Undergoing Cardiac Resynchronization Therapy

Elena Arbelo, Antonio García-Quintana, Eduardo Caballero, Antonio Delgado, Celestina Amador, Javier Suárez de Lezo, Marta Díaz-Escofet, and Alfonso Medina

Servicio de Cardiología, Hospital Universitario de Gran Canaria Dr. Negrín, Las Palmas de Gran Canaria, Spain

The retained guidewire technique has been proposed as an alternative method for stabilizing the left ventricular lead in patients who experience repetitive intraoperative dislocation. This article concerns 3 patients, out of a total of 185 (1.6%) undergoing cardiac resynchronization therapy, who had to be treated using the retained guidewire technique because of demonstrable recurrent lead dislocation. Electrode parameters were all within normal limits. Although lead dislocation could not be demonstrated macroscopically, sensing and pacing parameters were found to have changed 6 months to 1 year after implantation, with a marked elevation in impedance. Laboratory analysis showed deformation and fracture of the coil electrodes as well as deterioration of the insulation coating. In conclusion, our experience shows that the retained guidewire technique should not be used because delayed electrode damage can occur.

Key words: Heart failure. Electrical stimulation. Cardiac resynchronization therapy. Pacing lead fracture.

Deterioro tardío del electrodo venoso ventricular izquierdo estabilizado con la técnica de la guía retenida para la terapia de resincronización cardíaca

La técnica de la guía retenida se ha descrito como una alternativa para la estabilización del electrodo ventricular izquierdo en caso de migración intraoperatoria repetida. En el presente artículo analizamos a 3 (1,6%) de 185 pacientes tratados con resincronización cardíaca, que precisaron el uso de esta técnica tras objetivarse dislocación recurrente. Los parámetros del electrodo en el implante se encontraron dentro de límites normales. A pesar de no objetivarse migración macroscópica del electrodo, en todos los pacientes se observaron alteraciones en los parámetros de sensado y estimulación a los 6 meses-1 año del implante, con una marcada elevación de la impedancia. El análisis de laboratorio mostró deformación y fractura de las espirales conductoras, así como deterioro de las capas aislantes. En conclusión, nuestra experiencia muestra que la técnica de la guía retenida no debe utilizarse debido al deterioro diferido del electrodo.

Palabras clave: Insuficiencia cardíaca. Estimulación eléctrica. Terapia de resincronización cardíaca. Fractura de electrodo de estimulación.

INTRODUCTION

Cardiac resynchronisation therapy (CRT) is a proven therapeutic option for patients with heart failure.¹⁻⁴ The benefits of this therapy depend not only on careful patient selection, but also on the positioning of the electrodes, particularly that which stimulates the left ventricle (LV).⁵⁻⁷

Different manoeuvres have been described to overcome the anatomical obstacles limiting the access of the electrode to the vein.^{8,9} However, once the desired position has been reached, there is a risk that the electrode cannot be stabilised (which occurs in 1.6%-12.5% of cases¹⁻⁴) or that it will produce phrenic stimulation that cannot be corrected by repositioning or reprogramming the electrode.

In this context, the “retained guidewire technique” has been described as a simple solution in patients with repeated intra-operative migration of the left ventricular electrode.¹⁰

The objective of this paper is to describe our experience with 3 patients with whom the retained guidewire technique was used because of instability of the electrode while implanting a CRT device.

Correspondence: Dr. E. Arbelo Lainez.
Ctra. General del Centro, 239. 35017 Las Palmas de Gran Canaria.
España.
E-mail: elenaarbelo@secardiologia.es

Received April 2, 2007.
Accepted for publication June 29, 2007.

METHODS

During the period between May 2002 and December 2006, 185 patients have been treated with CRT devices at our centre. In 3 (1.6%) of them, who because of their clinical condition were considered unsuitable for an epicardial implant by thoracotomy, the retained guidewire technique was used because it was impossible to stabilise a bipolar electrode in the target vein with recurrent intra-operative migration (EasyTrak 2®, Guidant Corp., MN United States): in 2 patients, the phrenic stimulation meant it was essential to position the electrode in a more basal location in the vein, and in the third, the unfavourable anatomy of the vein emptying very close to the ostium of the coronary sinus and ascending stretch. All were males and aged 72, 65, and 64 years. They belonged to functional class III, with an ejection fraction of <35% (25.9, 22.2, and 31.7%, respectively) and a QRS >130 ms (135, 198, and 194 ms, respectively).

The manoeuvre consists of exteriorising of a hydrophilic guidewire (Whisper®, Guidant Corp., MN, United States) 10-15 mm beyond the electrode tip, its proximal portion is cut and it is left inside the electrode. The polymer cover, acting as insulation, did not change the performance of the electrode in the operation period (Figure 1).

RESULTS

In the implant, the threshold of the LV electrode at 0.5 ms was 2.3, 3.5, and 1.4 V and the stimulation impedance, 899, 1001, and 988 Ω , respectively. The amplitude of the electrogram was 5.5-14.3 mV, without observing artefacts in the left ventricular signal.

After an initial improvement, the 3 patients presented deterioration in functional grade; 1 at 6 months and the other 2 a year after the implant. Although no migration was detected using the fluoroscope, in all 3 cases changes

were observed in the parameters of the sensing and stimulation with the appearance of noise in the LV channel and capture failure (Figure 2A). Coincidentally, a marked increase in impedance was recorded (>2000 Ω).

The reprogramming of a pseudobipolar configuration (point LV at ring RV) permitted biventricular stimulation of one patient, while in the other 2 it was necessary to explant the damaged electrode with the guidewire inside, which showed macroscopic evidence of breakage at different levels (Figure 2B). In one of the cases, those which were sent to the laboratory for analysis were deformed and the conductor spirals were broken. It was shown that the internal and external insulating layers were damaged, as was the segment of the guidewire inside the electrode (Figure 2C), and found the guidewire broken at this level.

DISCUSSION

There are a variety of unresolved problems relating to left-ventricular stimulation for the CRT. One of these is the impossibility of placing the electrode in the target vein in a position that does not lead to frenetic stimulation. On the other hand, the stability of the electrode can be challenging by diverse anatomical reasons. Various techniques to stabilise the electrode have been described in cases of repeated intra-operative migration.

Different groups have proposed stabilising the electrode using a coronary stent.¹¹ Although, to date, no deterioration of the electrode has been described, caution must be exercised, as there is no data regarding the long-term behaviour of this technique, and it may be that friction between the external coating of the electrode and the stent will lead to its malfunctioning. On the other hand, implanting a stent could make it difficult to remove or relocate in the case of infection of diaphragmatic stimulation not correctable with reprogramming.

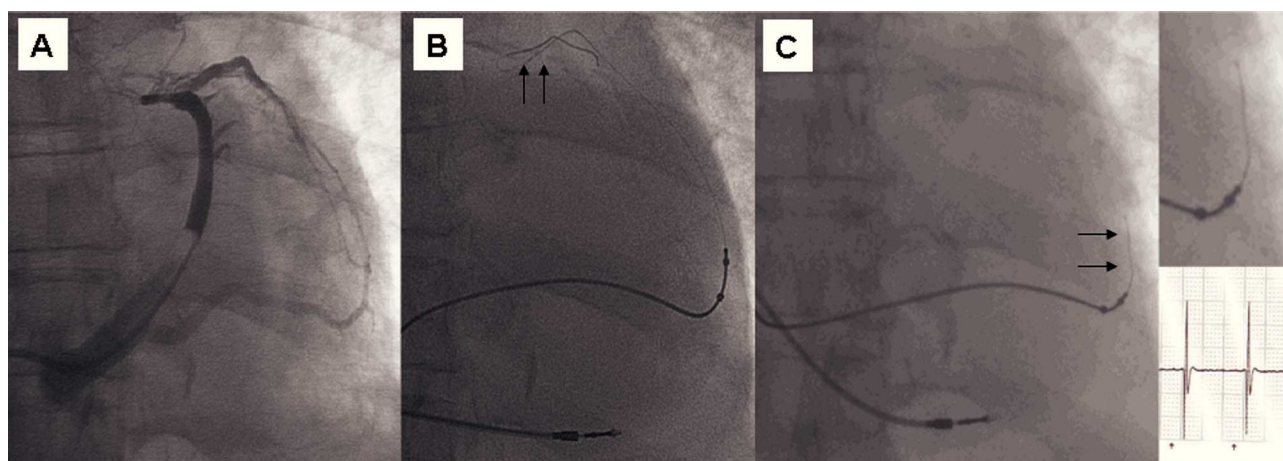


Figure 1. Retained guidewire technique. A: occlusive sinus venography that shows a vein with an output close to the ostium of the coronary sinus and the stretch in the lateral left ventricular region. B: final end of the guidewire and the route of the electrode. C: to avoid phrenic stimulation and stabilise the electrode the retained guidewire technique was used.

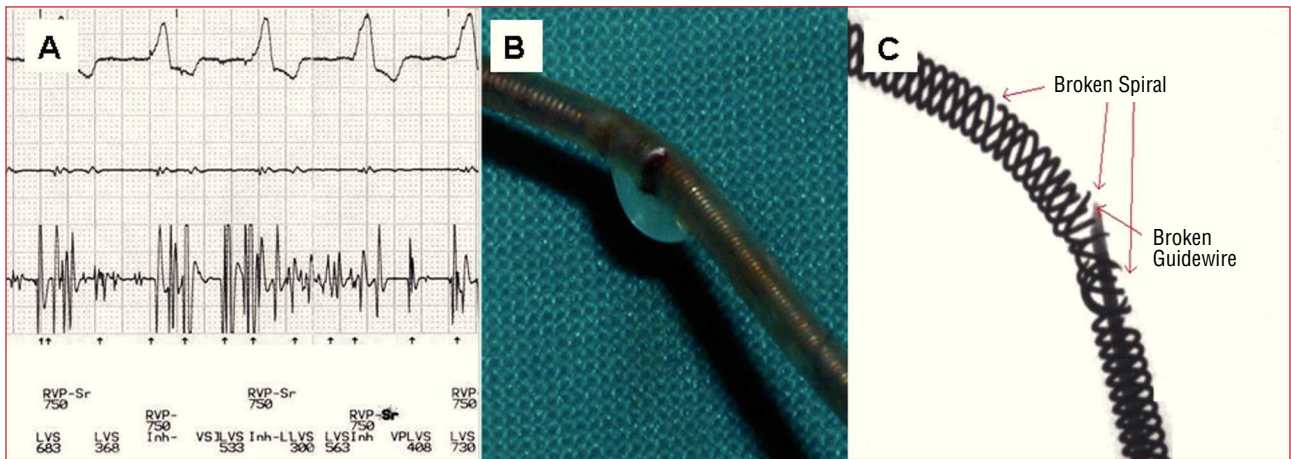


Figure 2. Failure of the retained guidewire technique. A: follow up after 1 year, a noise was recorded. B: the electrode and the guidewire within were explanted and the breakage was observed. C: laboratory analysis showing the broken spirals and the guidewire inside.

The retained guidewire technique has been described for stabilising the electrode in the selected position by incorporating a hydrophilic guidewire through the light of the electrode.¹⁰ de Cock et al¹⁰ refer to an average follow up of 6 months in 6 patients without having seen any deterioration in the electrode. However, in the light of the results of this technique in 3 patients in this series, with late deterioration of the LV electrode, in accordance with the findings reported by Nägele et al,¹² the use of this technique is not recommended for stabilising purposes. It is possible that the guidewire inside the electrode is the cause of the friction sustained in the internal spiral, leading to the fracture of the electrode.

The function of the guidewires is to give support during the placement of the electrode; they are not designed to be implanted. Taking into consideration that the guidewire is less flexible than the electrode, it is possible that this may break due to the repeated movements of the patients, which may damage the insulating layers and the spirals of the electrode. The findings of the laboratory examining the explanted electrode, showed the damage at the same level as the break in the guidewire, making it is more likely that the damage to the spirals and insulating layers is caused by the ends of the fractured guide. This deterioration also led to the clinically observed noise caused by friction of the conductor spirals. It is not expected that the results of this manoeuvre will have a different result if other types of electrodes are used.

Migration of the LV electrode continues to be a problem in CRT, which can appear in up to 10%-12% of implants.¹⁻⁴ However, based on the findings of this series, we do not advise the use of this technique, not only because of the failure of LV uptake with loss of biventricular stimulation, but also safety as it can cause vascular perforation by the ends of the damaged guide. It is necessary to develop new types of electrode with alternative adherence systems

that will reduce the number of patients in whom the stabilising the electrode is a challenge.

Even though it has been described as a useful technique for stabilising the electrode, the cases presented indicate that the retained guidewire should not be used as it leads to a deterioration in the electrode during monitoring.

REFERENCES

1. Abraham WT, Fisher WG, Smith AL, Delurgio DB, Leon AR, Loh E, et al. Cardiac resynchronization in chronic heart failure. *N Engl J Med.* 2002;346:1845-53.
2. Young JB, Abraham WT, Smith AL, Leon AR, Lieberman R, Wilkoff B, et al. Safety and efficacy of combined cardiac resynchronization and implantable cardioversion defibrillation in advanced chronic heart failure: the MIRACLE ICD Trial. *JAMA.* 2003;289:2685-94.
3. Bristow MR, Saxon LA, Boehmer J, Krueger S, Kass DA, de Marco T, et al. Cardiac-resynchronization therapy with or without an implantable defibrillator in advanced chronic heart failure. *N Engl J Med.* 2004;350:2140-50.
4. Cleland JGF, Daubert J-C, Erdmann E, Freemantle N, Gras D, Kappenberger L, et al. The effect of cardiac resynchronization on morbidity and mortality in heart failure. *N Engl J Med.* 2005;352:1539-49.
5. Auricchio A, Klein H, Tockman B, Sack S, Stellbrink C, Neuzner J, et al. Transvenous biventricular pacing for heart failure: can the obstacles be overcome? *Am J Cardiol.* 1999;83:D136-42.
6. Rossillo A, Verma A, Saad EB, Corrado A, Gasparini G, Marrouche NF, et al. Impact of coronary sinus lead position on biventricular pacing. Mortality and echocardiographic evaluation during long-term follow-up. *J Cardiovasc Electrophysiol.* 2004;15:1120-5.
7. Macías A, Gavira JJ, Alegría E, Azcárate PM, Barba J, García-Bolao I. Efecto de la localización del electrodo ventricular izquierdo sobre los parámetros ecocardiográficos de asincronía en pacientes sometidos a terapia de resincronización cardíaca. *Rev Esp Cardiol.* 2004;57:138-45.
8. Arbelo E, Medina A, Bolaños J, García-Quintana A, Caballero E, Delgado A, et al. Técnica de la doble guía para el implante del electrodo venoso ventricular izquierdo en pacientes con anatomía venosa coronaria desfavorable. *Rev Esp Cardiol.* 2007;60:110-6.
9. Arbelo Lainez E, Caballero Dorta E, García Quintana A, Delgado A, Ortega Trujillo JR, Amador Gil C, et al. Resincronización

- cardiaca: necesidad de estrategias individualizadas para lograr una tasa de éxito elevada en el implante del electrodo en una vena coronaria. *Rev Esp Cardiol*. 2006;59 Suppl 2:50.
10. de Cock CC, Jessurun ER, Allaart CA, Visser CA. Repetitive intraoperative dislocation during transvenous left ventricular lead implantation. Usefulness of the retained guidewire technique. *Pacing Clin Electrophysiol*. 2004;27:1589-93.
 11. Kowalski O, Prokopczuk J, Lenarczyk R, Pruszkowska-Skrzep P, Polonski L, Kalarus Z. Coronary sinus stenting for the stabilization of left ventricular lead during resynchronization therapy. *Europace*. 2006;8:367-70.
 12. Nägele H, Hashagen S, Ergin M, Azizi M, Behrens S. Coronary sinus lead fragmentation 2 years after implantation with a retained guidewire. *Pacing Clin Electrophysiol*. 2007;30:438-9.