

Late Recovery of Coronary Flow Reserve in Patients Successfully Treated with a Percutaneous Procedure

Manuel Pan^a, José Suárez de Lezo^a, Alfonso Medina^b, Miguel Romero^a, José Segura^a, Djordje Pavlovic^a, Enrique Hernández^b, Juan Muñoz^a, Marcos Rodríguez^a, Carmen Rus^a, Mónica Delgado^a and Soledad Ojeda^a

^aServicio de Cardiología, Hospital Universitario Reina Sofía, Córdoba, Spain

^bServicio de Cardiología, Hospital Universitario Dr. Negrín, Las Palmas de Gran Canaria, Spain

Introduction and objectives. Coronary angiograms are of limited value for the assessment of the results of percutaneous interventions. Intracoronary Doppler studies have been used to overcome these difficulties. The achievement of a coronary flow reserve (CFR) > 2-2.5 after the procedure is considered a good result and further optimization is generally not required. However, coronary flow reserve may not recover immediately, despite optimal procedural results. The aim of this study is to assess the temporal course of the recovery of coronary flow reserve after successful revascularization.

Patients and method. We studied 34 patients with coronary heart disease who were successfully treated by balloon angioplasty (n = 8) or stent implantation (n = 26). In all patients, serial observations were made by quantitative angiography and intracoronary Doppler (0.014 = flow-wire). Patients were studied: a) before treatment; b) immediately after, and c) 8 ± 3 months later.

Results. The baseline coronary flow reserve was 1.3 ± 0.4 and increased to 2.4 ± 0.8 after the procedure ($p < 0.01$). At 8 months follow-up there was a significant increase (3 ± 0.8 ; $p < 0.01$). This late improvement in coronary flow reserve was associated with a decline in average peak velocity at follow-up. Patients with impaired CFR immediately after treatment had a greater increase in CFR during followup than those with CFR > 2 after treatment (1.4 ± 0.9 vs 0.4 ± 0.6 ; $p < 0.01$).

Conclusions. After a successful coronary intervention, CFR increases immediately, but some patients may experience additional improvement during follow-up. This increase was greater in patients who showed less improvement in coronary flow reserve immediately after treatment. Our findings suggest that the use of Doppler parameters in the immediate assessment of percutaneous coronary intervention results have limitations.

Key words: *Coronary flow reserve. Percutaneous procedure. Coronary heart disease.*

Full English text available at: www.revespcardiol.org

Correspondence: Dr. M. Pan Álvarez-Ossorio
Servicio de Cardiología, Hospital Reina Sofía
Avda. Menéndez Pidal, s/n, 14004 Córdoba, Spain
E-mail: grupo_corpal@arrakis.es

Received on 17 April 2002.

Accepted for publication on 26 December 2002.

Recuperación tardía de la reserva coronaria en pacientes tratados con éxito mediante revascularización percutánea

Introducción y objetivos. El estudio Doppler intracoronario es una de las técnicas propuestas para resolver algunas de las limitaciones de la angiografía. Una reserva coronaria > 2-2,5 después de un procedimiento de revascularización se considera un buen resultado fisiológico y, en general, no se recomienda una optimización adicional en el procedimiento. Sin embargo, la recuperación de la reserva coronaria podría no ser siempre inmediata y completa. El objetivo de nuestro estudio es evaluar la evolución de la recuperación de la reserva coronaria después de una revascularización realizada con éxito.

Pacientes y método. Hemos incluido a 34 pacientes con enfermedad coronaria tratados con éxito mediante implantación de *stent* (n = 26) o angioplastia con balón (n = 8). En todos los pacientes obtuvimos un estudio angiográfico y otro de velocidades de flujo coronario en 3 condiciones: a) antes del tratamiento; b) inmediatamente después, y c) a los 8 ± 3 meses del seguimiento.

Resultados. La reserva coronaria basal fue de $1,3 \pm 0,4$ y aumentó a $2,4 \pm 0,8$ tras el procedimiento ($p < 0,01$). A los 8 meses de seguimiento se produjo un aumento adicional significativo ($3 \pm 0,8$; $p < 0,01$). Esta mejoría tardía de la reserva coronaria se asoció a una disminución en la velocidad basal obtenida en el estudio de seguimiento. Los pacientes con reserva coronaria disminuida tras el tratamiento (< 2) fueron los que tuvieron un mayor incremento de la misma en el seguimiento ($1,4 \pm 0,9$ frente a $0,4 \pm 0,6$; $p < 0,01$).

Conclusiones. Después de una intervención coronaria percutánea realizada con éxito, la reserva coronaria aumenta de forma inmediata. Sin embargo, algunos pacientes presentan mejoras adicionales en el seguimiento. Esta mejoría resultó mayor en los pacientes en los que la reserva no se recuperó inmediatamente tras el tratamiento. Nuestros datos sugieren que el uso de estos parámetros en la valoración inmediata de un procedimiento percutáneo tiene un valor limitado.

Palabras clave: *Reserva coronaria. Revascularización percutánea. Enfermedad coronaria.*

ABBREVIATIONS

MLD: minimal luminal diameter
CR: coronary reserve

INTRODUCTION

Coronary angiography poses certain limitations when used for assessing moderate coronary lesions or the results of percutaneous procedures. In an attempt to supplement the information provided by angiography, several alternative transluminal techniques have been proposed, such as intracoronary ultrasound,¹⁻⁴ pressure guidewires,⁵⁻⁶ or intracoronary Doppler.⁷⁻¹⁰ A coronary reserve greater than 2-2.5 after the latter procedure is considered a good physiological result, and no further optimization is generally required.^{9,10} However, coronary reserve might not be restored immediately after epicardial stenosis disappears. In order to assess how coronary reserve is restored over time after successful revascularization, we serially studied 34 patients angiographically and hemodynamically at baseline, immediately after the procedure, and during follow-up.

PATIENTS AND METHOD**Patients**

Our series consisted of 34 patients who fulfilled the following inclusion criteria: *a)* angina pectoris or inducible ischemia with single-vessel coronary heart disease as the sole cause for symptoms; *b)* length of the culprit lesion less than 20 mm; *c)* percutaneous treatment (stenting in 26 patients and balloon angioplasty in eight) that was successful at the first attempt with no major complications; *d)* postprocedural residual lesion <35%; *e)* absence of symptoms during follow-up (8±3 months), and *f)* repeat angiography showing delayed improvement (n=32) or mild restenosis (2 patients showing residual stenosis of 58% and 60%, respectively, at follow-up). Excluded from the study were patients who were treated in the initial 48 h after an acute myocardial infarction (AMI), as well as 6 patients who underwent basal and postoperative Doppler studies and showed clinical recurrence during follow-up. Informed consent was obtained in all cases before diagnostic and therapeutic catheterization.

Coronary angiography and percutaneous revascularization technique

All patients underwent coronary angiography via the femoral artery using conventional catheters (6-7 Fr) and projections. After the diagnostic phase, dilatation of the lesion with balloon angioplasty or stenting (Johnson-Cordis or Multilink Guidant) was performed.

During the therapeutic phase, all patients received intravenous heparin (2 mg/kg body weight). In patients who had undergone stent implantation, the device was expanded by a balloon with a diameter slightly larger than the reference vessel, at a mean pressure of 12-14 atmospheres. For a period of 1 month patients were kept on antithrombotic therapy, namely low-molecular-weight heparin (Fragmin 5000/12 h, ticlopidine 500 mg/day, and aspirin 150 mg/24 h). Glycoprotein IIb/IIIa inhibitors were not used in this study. In patients who had undergone only angioplasty, the balloon was chosen according to the same criteria that were used for the stent-treated group. Before and after the procedure quantitative angiography was performed using electronic calibrators, and the points corresponding to the minimal diameter of the lumen (MLD) and reference segment were selected manually.

Coronary flow velocity measurements

We used the Flomap system,¹¹⁻¹² which consists of two different parts: the flow guide wire and the console. The flow-wire is a conventional angioplasty guide measuring 0.014 inches with a flexible tip bearing a pulsed Doppler transducer that emits 15-MHz signals. The transducer is connected to the console preamplifier cable via a rotor-connector. The console has a Doppler signal-emission/reception system for digital processing, as well as a monitor and a video system for recording the results. The same measuring procedure was followed systematically in all cases; the Doppler guide was placed distal to the lesion, and flow velocities were recorded to obtain the mean peak velocity at baseline. Subsequently, an intracoronary bolus of 24 mg adenosine was injected into the left coronary artery, and a 12 mg bolus was injected into the right coronary artery.¹³⁻¹⁵ The mean peak velocity was measured again during maximal hyperemia, and coronary flow reserve was assessed by calculating the coefficient given by peak flow velocity divided by basal flow velocity. After the procedure, the study was repeated following the same systematic procedure used at baseline.

Follow-up study

At 8±3 months' follow-up, a repeat hemodynamic study was performed that included left ventriculogram, coronary angiograms, and measurements of coronary flow velocities and coronary reserve in the treated artery, using the same methods as in the earlier phases of the study.

Statistical analysis

Quantitative data are expressed as the mean±one standard deviation. Student's *t* test, along with Fisher's

TABLE 1. Baseline values (n=34)

Age, years	55±12
Sex	
Male	30 (88%)
Female	4 (12%)
Clinical status	
Unstable angina	31 (91%)
Stable angina	3 (9%)
Treated artery	
Anterior descending	20 (58%)
Circumflex	5 (15%)
Right coronary	9 (27%)
History of myocardial infarction	18 (53%)

correction for paired or unpaired data, were used, as appropriate, for comparing two means. Analysis of variance was used to compare mean results from the studies performed at baseline, after treatment, and at follow-up, and the Neumann-Keuls test was used for further individual comparisons. $P<.05$ were considered statistically significant.

Baseline data and immediate angiography results

Baseline data for all 34 patients are summarized in Table 1. The percent stenosis changed from 82 ± 9 to $10\pm 7\%$ ($P<.01$), and MLD changed from 0.6 ± 0.3 to 3.2 ± 0.5 mm ($P<.01$).

Serial studies of coronary flow velocities

Figure 1 shows the changes in baseline and post-hyperemia distal flow velocities, before and after the procedure and at follow-up. After revascularization there was a significant increase in baseline flow velocity as well as in peak flow velocity during hyperemia. At follow-up, peak velocity during hyperemia did not fluctuate, and basal velocity showed a modest but significant decrease. Hemodynamic criteria that might affect the assessment of coronary reserve (CR) varied very little from those applied in the study performed immediately after follow-up. Thus, heart rate changed from 67 ± 15 to $66\pm$ beats/min, while mean arterial pressure (MAP) increased from 97 ± 16 to 99 ± 14 mm Hg. Figure 2 shows the course of heart rate (at baseline, 1.3 ± 0.4 ; after the procedure, 2.4 ± 0.7 , and at follow-up, 3 ± 0.8), along with the changes in MLD seen with quantitative angiography. Coronary reserve and MLD increased considerably after revascularization. During follow-up, an additional increase in coronary reserve and a slight but significant loss of MLD were noted. In 8 of our patients (23%), CR did not normalize immediately (immediate CR <2). Nevertheless, all such patients attained levels >2 at follow-up. On the other hand, 4 patients with an immediately normal CR (>2)

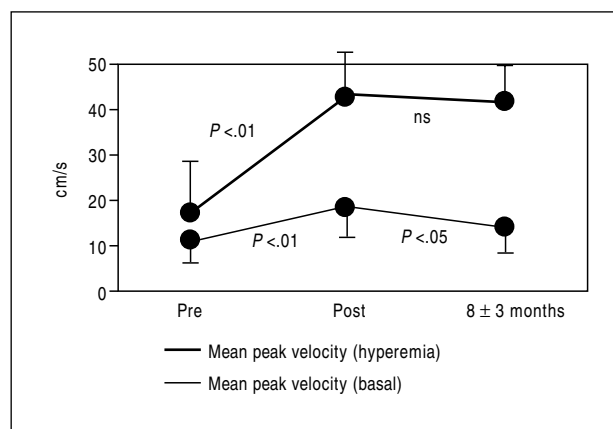


Fig. 1. Changes in distal flow velocities (cm/s) obtained under 3 study conditions: before the procedure, after the procedure, and at follow-up.

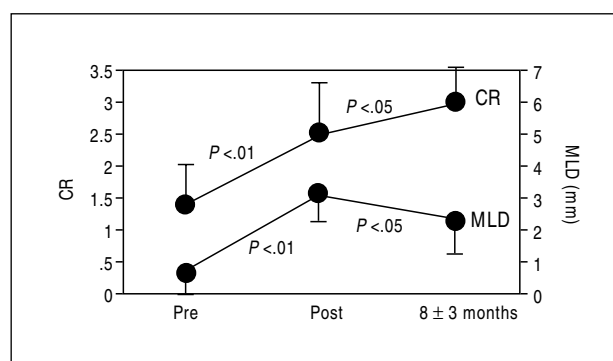


Fig. 2. Coronary reserve over time along with changes in minimal luminal diameter (mm) under the 3 study conditions.

showed a decrease in this parameter at follow-up, although the value was never <2 .

We carried out a study to identify determinants of increased coronary reserve at follow-up (follow-up CR and post-procedure CR), and all clinical parameters examined (age, sex, and clinical situation) were negative, as were angiographies performed to determine the location of the lesion, its severity, and the involved artery. The type of revascularization (dilatation with balloon angioplasty or stenting) did not appear to be a determinant for increased CR. The only factor that was significantly associated with the latter was the inability to attain a coronary reserve above 2 during the procedure. Patients with a history of myocardial infarction in the treated area showed a tendency toward increased reserve at follow-up, but this tendency was not statistically significant (Figure 3).

DISCUSSION

Doppler techniques have been used to measure coronary flow velocity in patients in whom it may be

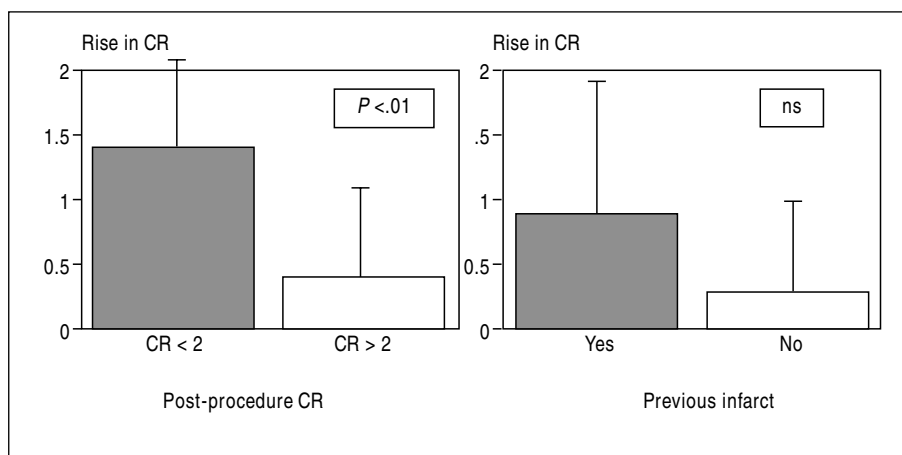


Fig. 3. Factors determining increases in coronary reserve at follow-up (follow-up CR – CR immediately after procedure). A: optimal or suboptimal immediate coronary reserve. B: presence or absence of a history of myocardial infarction.

difficult to decide on a clinical course of action: to treat or not treat moderately severe lesions,^{7,8} to assess the results of coronary revascularization procedures,^{9,10} or as a predictive factor after stenting.¹⁶ Of all proposed Doppler-based parameters, assessing coronary reserve is the most relevant. Normal coronary reserve reflects the ability of coronary vessels to increase their blood flow up to 4- to 6-fold above baseline after maximal vasodilator stimulation.¹⁷ This compensatory mechanism, which maintains good blood flow, is abolished when a significant lesion (either native or post-intervention) is present in epicardial vessels. In such cases, vasodilator stimuli do not produce additional vasodilatation, nor do they significantly increase coronary blood flow. Upon suppression of epicardial stenosis, compensatory vasodilatation is no longer necessary, and the ability to respond to stimuli that trigger vasodilatation is restored.^{18,19} Nevertheless, few studies have sought to determine when coronary reserve is res-

tored after having been undermined by a severe lesion that has been successfully resolved. Our findings suggest that a certain proportion of patients (23%) do not attain normal coronary reserve immediately after effective revascularization, and that there is a transient dissociation between coronary reserve and quantitative angiography. Therefore, coronary reserve measurements obtained immediately after revascularization may underestimate how successful the procedure has actually been.

Decreased coronary reserve after a successful procedure

Aside from the persistence of significant residual stenosis,^{18,19} the reasons CR is not immediately restored are not fully known. Because CR is a quotient, the reasons may involve a decrease in the numerator (flow velocity after hyperemia) or an increase in the denominator (basal flow velocity):

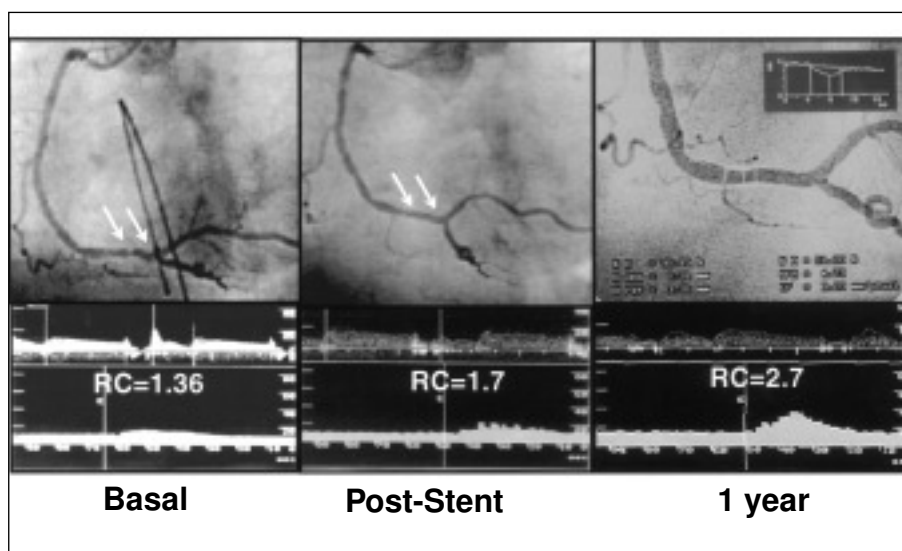


Fig. 4. Example of a patient with a lesion in the distal segment of the right coronary artery who underwent stenting. Coronary reserve (RC) at follow-up improves significantly at the expense of an increase in flow velocity during adenosine-induced hyperemia.

1. Increased baseline flow velocity: the heart self-regulates arteriolar resistance in response to changes in perfusion pressure. The effect of prolonged distal hypotension caused by acute epicardial stenosis in coronary self-regulation causes prolonged arteriolar vasodilatation and "vasoplexy," or a transient loss of the vascular bed's self-regulatory capacity (failure to achieve adequate vasoconstriction) in response to the sudden recovery of perfusion pressure. This results in an increase in baseline coronary blood flow and a decrease in the quotient given by peak flow velocities divided by baseline flow velocities. Earlier studies²⁰⁻²² support the theory that an increase in basal blood flow is responsible for the decrease in CR after revascularization, as well as the notion that self-regulation is slowly restored.

2. A decrease in flow velocity during hyperemia (Figure 4): microvascular embolization by platelet aggregates or thrombus fragments during dilatation may diminish the microvascular response to adenosine, as well as reducing basal blood flow. Prolonged ischemia and small vessel necrosis also affect the ability to respond to vasodilators, and the concept of "stunned microcirculation,"²¹⁻²⁴ similar to the concept of the "stunned myocardium" has been suggested. In the acute phase of a myocardial infarction, coronary reserve after revascularization may even improve faster (in 24 h to 2 weeks), at the expense of an increase in flow velocity during hyperemia.^{23,25,26}

A substudy of the DEBATE²⁷ study has recently been published in which, in addition to the reasons mentioned above, being older and female turned out to be predictive factors for having a suboptimal reserve after successful revascularization.

Limitations and clinical implications

Despite the fact that the doses of adenosine used in our study are the ones that have been recommended in many of the multicenter studies on this subject,^{9,16} maximum arteriolar vasodilatation may not have been achieved. However, because the same doses were used under all study conditions, a change in small vessel response has been shown to take place over time. On the other hand, the sample size is small, and perhaps some of the factors having no predictive value may turn out to be predictive in larger series.

Despite these limitations, we believe that CR improves immediately after a successful coronary intervention, but some patients may experience additional improvement in subsequent months. In our group of patients, this delayed improvement in coronary reserve occurred at the expense of a decrease in the basal velocity obtained in the follow-up study and was greater in patients having a low coronary reserve immediately after treatment. Our findings suggest that the use of

these Doppler parameters for immediately assessing the results of a percutaneous coronary procedure may be of limited value.

REFERENCES

1. Abizaid A, Mintz GS, Pichard AD, Kent KM, Satler LF, Walsh CL, et al. Clinical, intravascular ultrasound, and quantitative angiographic determinants of the coronary flow reserve before an after percutaneous transluminal coronary angioplasty. *Am J Cardiol* 1998;82:423-8.
2. Tagaki A, Tsurumi Y, Ishii Y, Suzuki K, Kawana M, Kasanuki H. Clinical potential of intravascular ultrasound for physiological assessment of coronary stenosis: relationship between quantitative ultrasound tomography and pressure-derived fractional flow reserve. *Circulation* 1999;100:250-5.
3. Briguori C, Anzuini A, Airolidi F, Gimelli G, Nishida T, Adamian M, et al. Intravascular ultrasound criteria for the assessment of the functional significance of intermediate coronary artery stenoses and comparison with fractional flow reserve. *Am J Cardiol* 2001;87:136-41.
4. Hanekamp CEE, Koolen JJ, Pijls NHJ, Michels HR, Bonnier HJRM. Comparison of quantitative coronary angiography, intravascular ultrasound, and coronary pressure measurement to assess optimum stent deployment. *Circulation* 1999;99:1015-21.
5. Bech GJ, De Bruyne B, Bonnier HJRM, Bartunek J, Wijns W, Peels K, et al. Long-term follow-up after deferral of percutaneous transluminal coronary angioplasty of intermediate stenosis on the basis of coronary pressure measurement. *J Am Coll Cardiol* 1998;31:841-7.
6. Bech GJW, Pijls NHJ, De Bruyne B, Peels KH, Michels R, Bonnier HJRM, et al. Usefulness of fractional flow reserve to predict clinical outcome after balloon angioplasty. *Circulation* 1999;99: 883-8.
7. Kern MJ, Donohue TJ, Aguirre FV, Bach RG, Caracciolo EA, Wolford T, et al. Clinical outcome of the deferring angioplasty in patients with normal translesional pressure-flow velocity measurements. *J Am Coll Cardiol* 1995;25:178-87.
8. Ferrary M, Schenell B, Werner GS, Figulla HR. Safety of deferring angioplasty in patients with normal coronary flow velocity reserve. *J Am Coll Cardiol* 1999;33:83-7.
9. DiMario C, Moses JW, Anderson TJ, Bonan R, Muramatsu T, Jain AC, et al. Randomized comparison of elective stent implantation and coronary balloon angioplasty guided by online quantitative angiography and intracoronary Doppler. *Circulation* 2000; 102:2938-44.
10. Serruys PW, de Bruyne B, Carlier S, Sousa JE, Piek J, Muramatsu T, et al. Randomized comparison of primary stenting and provisional balloon angioplasty guided by flow velocity measurement. *Circulation* 2000;102:2930-7.
11. Doucette JW, Corl Pd, Payne HM, Flynn AE, Goto M, Nassi M, et al. Validation of a Doppler guide wire for intravascular measurement of coronary artery flow velocity. *Circulation* 1992;85: 1899-911.
12. Labovitz AJ, Anthonis DM, Cravens TL, Kern MJ. Validation of volumetric flow measurements by means of a Doppler-tipped coronary angioplasty guide wire. *Am Heart J* 1993;126:1456-61.
13. Ofili EO, Labovitz AJ, Kern MJ. Coronary flow velocity dynamics in normal and diseased arteries. *Am J Cardiol* 1993;71: D3-9.
14. Donohue TJ, Morton JK, Aguirre FV, Bach RG, Wolford T, Bell CA, et al. Assessing the hemodynamic significance of coronary artery stenoses: analysis of translesional pressure-flow velocity relations in patients. *J Am Coll Cardiol* 1993;22:449-58.

15. Miller DD, Donohue TJ, Younis LT, Bach RG, Aguirre FC, Wittry MD, et al. Correlation of pharmacological 99mTc-sestamibi myocardial perfusion imaging with poststenotic coronary flow reserve in patients with angiographically immediate coronary artery stenoses. *Circulation* 1994;89:2150-60.
16. Nishida T, Di Mario C, Kern MJ, Anderson TJ, Moussa I, Bonan R, et al. Impact of final coronary flow velocity reserve on late out following stent implantation. *Eur Heart J* 2002;23:331-40.
17. Hoffman JJ. Maximal coronary flow and the concept of coronary vascular reserve. *Circulation* 1984;70:153-9.
18. Haude M, Caspari G, Baumgart D, Brennecke R, Meyer J, Erbel R. Comparison of myocardial perfusion reserve before and after coronary balloon predilatation and after stent implantation in patients with postangioplasty restenosis. *Circulation* 1996;94:286-97.
19. Kern MJ, Dupouy P, Drury JH, Aguirre FV, Aptekar E, Bach RG, et al. Role of coronary artery lumen enlargement in improving coronary blood flow after balloon angioplasty and stenting: a combined intravascular ultrasound Doppler flow and imaging study. *J Am Coll Cardiol* 1997;29:1520-7.
20. Nanto S, Kodama K, Hori M, Mishima M, Hirayama A, Inoue M, et al. Temporal increase in resting coronary blood flow causes and impairment of coronary flow reserve after coronary angioplasty. *Am Heart J* 1992;123:28-36.
21. Kern MJ, Deligonul U, Vandormael M, Labovitz AJ, Gudipati CV, Gabliani G, et al. Impaired coronary vasodilator reserve in the immediate postcoronary angioplasty period: analysis of coronary artery flow velocity indexes and regional cardiac venous efflux. *J Am Coll Cardiol* 1989;13:860-72.
22. Van Liebergen RAM, Piek JJ, Koch KT, de Winter RJ, Lie KI. Immediate and long-term effect of balloon angioplasty or stent implantation on the absolute and relative coronary blood flow velocity reserve. *Circulation* 1998;98:2133-40.
23. Pan M, Suárez de Lezo J, Medina A, Romero M, Hernández E, Segura J, et al. Microvascular stunning in acute coronary syndromes: early recovery of coronary flow reserve after stenting is associated with improvement in diastolic function. *J Am Coll Cardiol* 1999;33:30A.
24. Bolli R, Triana F, Jeroudi MO. Prolonged impairment of coronary vasodilation after reversible ischemia: evidence for microvascular stunning. *Circulation* 1990;67:332-43.
25. Ishihara M, Sato H, Tateishi H, Kawagoe T, Shimatani Y, Kurisu S, et al. Time course of impaired coronary flow reserve after reperfusion in patients with acute myocardial infarction. *Am J Cardiol* 1996;78:1103-8.
26. Neumann FJ, Blasini R, Schmitt C, Alt E, Dirschinger J, Gawaz M, et al. Effect of glycoprotein IIB/IIIa receptor blockade on recovery of coronary flow and left ventricular function after the placement of coronary-artery stents in acute myocardial infarction. *Circulation* 1998;98:2695-701.
27. Albertal M, Regar E, Van Langenhove G, Carlier SG, Serrano P, Boersma E, et al. Flow velocity and predictors of a suboptimal coronary flow velocity reserve after coronary balloon angioplasty. *Eur Heart J* 2002;23:133-8.