

Late T-Lymphocyte and Monocyte Activation in Coronary Restenosis. Evidence for a Persistent Inflammatory/Immune Mechanism?

Francisco Navarro-López^a, Antonio Francino^a, Antonio Serra^a, Montserrat Enjuto^a, Juan Carlos Reverter^b, Teresa Jimenez de Anta^c and Amadeo Betriu^a

^aLaboratorio de Cardiología Molecular, Departamento de Cardiología (ICMCV). Hospital Clínic (IDIBAPS), Universidad de Barcelona, Barcelona. ^bLaboratorio de Cardiología Molecular. Departamento de Hemoterapia y Hemostasia. Hospital Clínic (IDIBAPS), Universidad de Barcelona, Barcelona. ^cLaboratorio de Cardiología Molecular, Departamento de Microbiología, Hospital Clínic (IDIBAPS), Universidad de Barcelona, Barcelona, Spain

Aims. This study was made to determine if restenosis after percutaneous coronary angioplasty is associated with acute or chronic inflammatory/immunologic activity, and explored possible relationships with latent infection.

Patients and method. Forty-six consecutive patients underwent elective PTCA and 6 months of angiographic follow-up. Peripheral venous blood samples were obtained at baseline, 24-48 h, and 4-6 months post-intervention. Flow-cytometric methods were used to measure early and late circulating leukocyte activation status. IL-6 and TNF-alpha cytokines, and IL-2 soluble receptor concentrations were determined in all plasma samples. *Chlamydia pneumoniae* and *Cytomegalovirus* antibody assays were performed to detect infectious disease.

Results. Angiographic coronary stenosis developed in 27 out of 46 patients. At 6 months of follow-up, these patients showed a significant increase in circulating cytotoxic T-lymphocytes CD3+/CD56+ (18.8 ± 7.1 vs $6.12 \pm 2.7\%$; $p = 0.005$) and activated monocytes (CD11b: $1,383 \pm 624$ vs 990 ± 484 MFI, $p = 0.025$; CD64: 76.0 ± 28.7 vs 56.7 ± 21.8 MFI; $p = 0.014$), with no apparent relation to increased cytokines or latent infectious disease.

Conclusions. Restenosis appears to be associated to inflammatory and immunological activity that persists 6 months after coronary intervention. No relationship was found with the infections studied. The presence of inflammatory activity 4-6 months after PTCA suggest that pharmacological therapeutic interventions to prevent restenosis should be maintained for months.

Key words: Restenosis. Coronary angioplasty. Lymphocytes. Leukocytes. Interleukins. Infection.

Linfocitos T y monocitos activados en la reestenosis coronaria. ¿Reflejan la persistencia de un mecanismo inflamatorio?

Objetivos. El objetivo de este trabajo ha sido estudiar la relación de la reestenosis coronaria postangioplastia con la actividad inflamatoria e inmunitaria en la sangre periférica, y explorar su posible asociación con infecciones latentes.

Pacientes y método. Se estudiaron 46 pacientes consecutivos con angina a los que se practicó una angioplastia coronaria percutánea y un control angiográfico a los 6 meses. Se tomaron muestras de sangre venosa antes de la intervención, 24-48 h después y a los 6 meses. Se determinó la expresión de las moléculas de adhesión en los leucocitos mediante la técnica de la citometría de flujo. Se cuantificaron las concentraciones de las citocinas proinflamatorias interleucina (IL) 6 y factor de necrosis tumoral (TNF) alfa, así como los receptores solubles de la IL-2 en el plasma, y se utilizaron las reacciones antigénicas para detectar la infección por *Chlamydia pneumoniae* y *Cytomegalovirus*.

Resultados. Los pacientes con reestenosis coronaria angiográfica (27 de 46) presentaron un aumento significativo de los linfocitos T citotóxicos CD3+/CD56+ ($18,8 \pm 7,1$ frente a $6,12 \pm 2,7\%$; $p = 0,005$) y de monocitos activados (CD11b: 1.383 ± 624 frente a 990 ± 484 MFI; $p = 0,025$; CD64: $76,0 \pm 28,7$ frente a $56,7 \pm 21,8$ MFI; $p = 0,014$) a los 6 meses, sin relación aparente con el aumento de las citocinas o la positividad de las reacciones antigénicas infecciosas.

Conclusiones. La reestenosis coronaria se asocia a una reacción inflamatoria/inmunitaria persistente, que no parece estar relacionada con las infecciones latentes estudiadas. La persistencia de actividad inflamatoria a los 4-6 meses sugiere que las intervenciones destinadas a prevenir la reestenosis deberían mantenerse durante meses.

Palabras clave: Reestenosis. Angioplastia coronaria. Linfocitos. Leucocitos. Interleucina. Infección.

Full English text available at: www.revespcardiol.org

Financed by a grant from the Spanish Ministry of Education (SAF97-0124).

Correspondence: Dr. F. Navarro-López
Servicio de Cardiología, Hospital Clínic, Universidad de Barcelona,
Villarroel, 170, 08036 Barcelona, Spain
E-mail: navarro@medicina.ub.es

Received 29 September 2002.

Accepted for publication 17 January 2003.

INTRODUCTION

It is currently accepted that atheroma plaques have inflammatory characteristics.¹ Thus it is reasonable to assume that inflammation may play a key role in the genesis of post-angioplasty coronary restenosis.

ABBREVIATIONS

PTCA: percutaneous transluminal coronary angioplasty

IL-6: interleukin 6

TNF- α : tumor necrosis factor alpha

IL-2 sR: interleukin 2 soluble receptor

CMV: cytomegalovirus

Pathologists have described the infiltration of inflammatory cells (monocytes and macrophages) and immunocytes (T-lymphocytes) in restenosis tissue.²⁻⁴ In addition, angiographic monitoring studies have associated restenosis with previous or PTCA-induced inflammatory responses. This inflammatory response is detected clinically by the activation of circulating leukocytes (monocytes and polymorphonuclear leukocytes) that express adhesion molecules on the cell surface,^{5,6} the increase in proinflammatory cytokines especially interleukin 6 (IL-6) and tumor necrosis factor alpha (TNF- α) produced by activated monocytes,^{7,8} and by an acute-phase increase in reactant protein, such as C-reactive protein synthesized by the liver and regulated by IL-6.^{9,10} However, the origin, nature and long-term behavior¹¹ of this inflammation is unknown, although recently it has been suggested that it might be related to local or systemic infection,¹²⁻¹⁴ a thrombotic phenomenon¹⁵ or an additional specific immune process.¹⁶

We prospectively analyzed the relationship between coronary restenosis and post-PTCA chronic and acute inflammatory/immunological response as shown by: *a*) leukocyte activation (lymphocytes, monocytes and neutrophils) in peripheral venous blood, and *b*) production of proinflammatory (IL-6 and TNF- α) and immune (IL-2 sR) cytokines. As a secondary objective we studied the possible relationship between restenosis and latent infection.

PATIENTS AND METHODS

This was a prospective study of 46 consecutive patients with angina pectoris, aged 38-76 years, who had undergone elective PTCA in 1988; 23 of these patients had also undergone atherectomy. Table 1 shows the characteristics of the patients who participated in this study. Patients who had suffered angina in the week prior to the study were excluded to minimize the possible effects of the acute phase of unstable angina on leukocyte activation. We also excluded patients with myocardial infarction of less than 15 days' evolution, and those with peripheral vascular disease. A follow-up coronary angiography was performed after 6 months. The study was approved by the ethics com-

mittee of the hospital, and informed consent was obtained from all patients.

Coronary angiography and percutaneous transluminal coronary angioplasty

All coronary angiographies were done with the Judkins technique using a 6 Fr femoral introducer sheath. This was subsequently replaced with a larger one (8 Fr) to perform PTCA with or without a Palmaz-Schatz stent implantation or a directional atherectomy following the standard technique. The coronary intervention was considered successful when residual stenosis in the angiography was <50%, in the absence of further complications. The introducer was removed 4 h after the intervention or later the same day if the activated coagulation time was less than 170 s. Each patient received 10 000 U of intravenous heparin before the procedure. Post-intervention treatment was the same for all patients (ticlopidine and aspirin).

Quantitative analysis of the initial and 6-months follow-up coronary angiography was performed by two independent observers using a computerized system (ImageComm Systems, USA). Minimum luminal diameter, interpolated reference diameter, and the percentages of stenosis were determined in end-diastole, using the same projection for all coronary angiographies (i.e., initial, post-intervention, and after 6-months). The guide catheter was used as the reference for calibration. Late loss during the follow-up period was defined as the difference between mini-

TABLE 1. Demographic and clinical data

	Patients with no restenosis (n=19)	Patients with restenosis (n=27)	P
Age, years	59 \pm 13	57 \pm 10	.500
Sex: Male, %	16 (84.2%)	21 (77.8%)	.716
Unstable angina	6 (31.6%)	12 (44.4%)	.566
Last angina episode, days	20 (15-37)	27 (12-78)	.867
Risk factors			
Diabetes	6 (31.6%)	5 (18.5%)	.484
Cigarette smoking	6 (31.6%)	12 (44.4%)	.465
Hypertension	5 (27.8%)	14 (56%)	.119
Total cholesterol, mg/dL	217 \pm 37	203 \pm 49	.310
HDL-C, mg/dL	34.8 \pm 11	39.3 \pm 11	.200
Medication			
ASA	17 (89.5)	25 (92.6%)	1.000
Nitrates	3 (15.8%)	10 (38.5%)	.182
Statins	13 (68.4%)	15 (61.5%)	.483
Calcium antagonists	8 (42.1%)	12 (44.4%)	1.000
Betablockers	13 (68.4%)	16 (61.5%)	.523

Data are expressed as the mean \pm standard deviation (SD), number and percentage (%) of patients or the median and interquartile range. HDL-C: high density lipoprotein cholesterol.

luminal diameter in the post-PTCA and 6-months coronary angiographies and the loss index. Restenosis was defined as a $\geq 50\%$ narrowing of the lumen in the segment treated at 6-months follow-up, if this had been $< 50\%$ after the intervention.

Leukocyte activation. Flow cytometry and adhesion molecules

Lymphocyte, monocyte and neutrophil activation was analyzed by flow cytometry to quantify the expression of adhesion molecules in the cellular membrane (surface markers).

We analyzed three samples of peripheral venous blood from each patient drawn immediately before the angioplasty, 24-48 h later and after 6 months. Venipuncture was done without a tourniquet and the samples were collected in a test-tube with EDTA, which was immediately placed without prior fixation in ice and kept at -20°C . Each sample was analyzed in duplicate.

We measured receptor expression by direct immunofluorescence. Samples were analyzed with the following antibodies: CD11a, CD11b and CD11c (Dako, Barcelona, Spain); CD3, CD16, CD33 and CD56 (Becton and Dickinson, Calif., USA); CD66a and CD66b (CLB, Amsterdam); and CD64 (Serotec). We used either FITC or PE-conjugated anti-mouse monoclonal antibodies (isotype-matched) (IgG1 FITC, Immunotech; and IgG2 PE, Caltag) as labeled controls. We also added 100 μL of total blood with saturated concentrations of anti-human monoclonal antibodies conjugated with FITC or PE (phycoerythrin). After incubation for 20 min at room temperature in the dark, erythrocytes were lysed and leukocytes fixated using a commercial solution (FACS Lysing Solution, Becton and Dickinson). Cells were immediately washed twice with PBS and stored at 4°C in the dark.

Immediately after the staining procedure, we used a FACScan flow cytometer (Becton Dickinson, Mountain View, Calif., USA) to measure the fluorescence of 2×10^6 cells using Lysis II software. We identified neutrophils, monocytes and lymphocytes by their dispersion properties. Samples were read in logarithmic scale with FL1 (fluorescein, fluorescence at 530 nm) or FL2 (phycoerythrin, fluorescence at 585 nm). Mean fluorescence intensity (MFI) was expressed in arbitrary units. We calculated the percentage of cytotoxic T-lymphocytes and natural killer cells (NK) by CD3 and CD56 positivity.

Cytokines

We collected blood samples in Vacutainer tubes, and after coagulation blood components were separated by centrifugation and stored in assay tubes at

-80°C . We determined the concentrations of IL-6, TNF- α and IL-2 sR (the IL-2 soluble receptor) by a high sensitivity solid-phase immunoassay (IL-6 and TNF- α : EASIA, Medgenix Diagnostics; IL-2 sR, Immunotech). All determinations were done in duplicate, and mean values were calculated.

Chlamydia pneumoniae and cytomegalovirus antibodies

We obtained anti-cytomegalovirus (CMV) IgG antibody values using an ELISA assay kit (Cytomegelisa II), and anti-*Chlamydia pneumoniae* IgG antibody values by indirect immunofluorescence. Antibody titers below 1/64 were considered negative. The tests were performed without knowledge of the angiographic data.

Statistical analysis

Data are presented as the mean \pm SEM (standard error of the mean). We analyzed the differences between the two groups of patients with and without restenosis using Student's t test or the χ^2 test. Intra-group changes in all three stages (pre-PTCA, and acute and chronic post-PTCA) were analyzed by repeat measure ANOVA. We analyzed the correlation between inflammatory marker data with the nonparametric test for Spearman's rho. Data were considered statistically significant for values of $P < .05$. We used SPSS v.9. software for the statistical analysis.

RESULTS

Clinical, demographic and angiographic characteristics

After 6 months, 27 of the 46 consecutive patients presented angiographic restenosis (59%; 95% CI, 44.5%-73%). Tables 1 and 2 show the baseline demographic, angiographic and clinical data for patients with and without restenosis. No significant differences were found. In 4 patients, follow-up coronary angiography was done after only 4-5 months because they presented effort angina.

T-lymphocytes

Patients with coronary restenosis at 6-months follow-up also showed a significant increase in cytotoxic T-lymphocytes (CD3+ and CD56+) compared to baseline figures ($P < .011$ for repeat measure ANOVA, and $P = .007$ for paired sample ANOVA), reaching higher levels than patients without restenosis (10.8 ± 7.0 versus $6.1 \pm 2.8\%$; $P = .005$) (Figure 1). The levels of cytotoxic T-lymphocytes in the late phase showed good correlation with the baseline figures ($r = 0.490$; $P = .001$) (Figure 2A). We found no rela-

TABLE 2. Angiographic data

	Patients with no restenosis (n=19)	Patients with restenosis (n=27)	P
Implanted stents	9 (47.4%)	10 (37.0%)	.552
Atherectomy	7 (36.8%)	10 (37.0%)	.989
No. of lesions			.599
Anterior descending artery	9	14	
Left circumflex artery	5	6	
Right coronary artery	5	6	
No. vessels (1 vessel/>1 vessel)	8/13	11/14	.625
Reference diameter, mm	3.17±.53	3.09±.62	.659
Length of the lesion	8.18±2.8	11.5±7.6	.077
Stenosis diameter, %			
Pre-PTCA	80.3±8.7	78.7±14.4	.678
Post-PTCA	20.2±11.6	23.9±12.7	.324
After 6 months	31.0±12.6	77.6±15.2	.000
Gain, mm	1.89±.59	1.70±.71	.329
Loss, mm	0.34±.47	1.6±.47	.000

Data are given as the mean±standard deviation (SD).

tionship between the percentage of lymphocytes at baseline or after 6 months and the presence of angina during the last month, antecedents of unstable angina, stent implantation or atherectomy. There were no significant differences in positivity for CD3/CD56 in T-lymphocytes or natural killer cells.

Monocyte and polymorphonuclear cell activation

In patients with restenosis we also found that monocytes showed a significant increase in the expression of adhesion molecules Mac-1/CD11b at 6 mo (1383±625 vs. 990±484 MFI; $P=.025$), and CD64/FcγRI (76±29 vs. 57±22 MFI; $P=.014$) when compared to monocytes in patients without restenosis

(Figure 3). In contrast, we found no differences in neutrophil markers Mac-1 (CD11b) and CD66b (BGP-1) (Figure 4).

The expression of CD11b ($r=0.646$; $P<.0001$) and CD64 ($r=0.563$; $P<.0001$) monocyte markers showed a high correlation with the percentage of cytotoxic T-lymphocytes at 6 mo (Figure 2B). Restenosis developed in all patients with >10% cytotoxic T-lymphocytes and >1000 MFI units in CD11b monocytes (22%) (Figure 2B). We observed no relationship with neutrophil markers.

IL-6, TNF-α and IL-2-RS cytokines

Plasma concentrations of IL-6 and TNF-α increased significantly after the intervention, but only TNF-α concentrations remained high at 6 months ($P<.004$ for repeat measure ANOVA); however, these results were independent of whether patients suffered restenosis or not. There was a slight increase in L-2-sR cytokine at 6 months in patients with restenosis, but this did not reach statistical significance (66±5.5 ng/mL vs 69±8.5 ng/mL; $P=.87$). High levels (>80 ng/mL) were found in three patients who did not present restenosis, and in eight who did ($P=.234$) (Figure 5). The ratio was similar to the values observed at pre-PTCA. We found no clear correlation between cytokines and leukocyte activation.

Chlamydia pneumoniae and cytomegalovirus

We found no significant differences between patients with restenosis and those without. A total of nine (55.5%) patients with restenosis and 15 without (47.4%) were seropositive for *C. pneumoniae* IgG antibodies. The percentages of CMV seropositive patients with and without restenosis were 68.4% and 74.1%, respectively ($P=.093$).

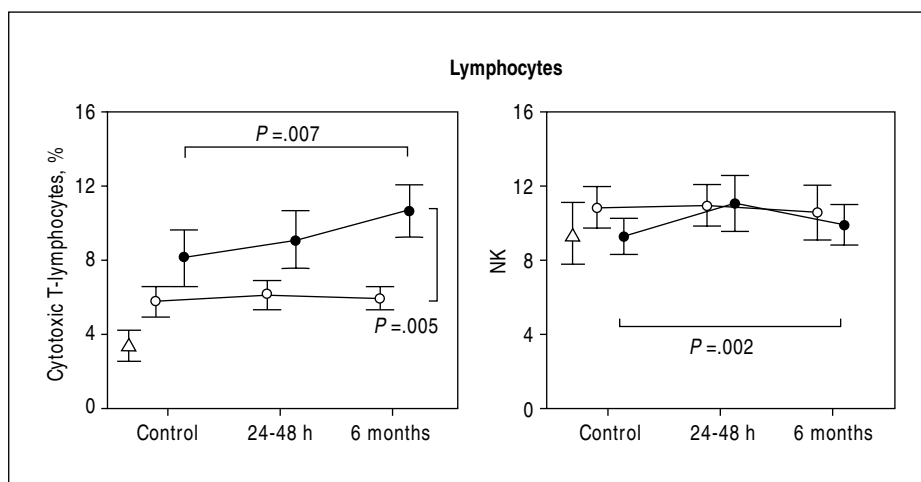


Fig. 1. Percentage of cytotoxic and natural killer (NK) T-lymphocytes, pre-angioplasty (control), 24-48 h later, and 6 months after intervention. Black circles: patients who developed restenosis. White circles: patients who did not develop restenosis. Triangles: normal values. Percentage±standard error of the mean (SEM). A significant increase in cytotoxic lymphocytes was found after 6 months in patients who developed restenosis when compared to baseline values ($P=.007$), and in patients who did not develop restenosis ($P=.005$). The increase in NK lymphocytes was also significant in patients with restenosis when compared to levels at baseline.

Fig. 2. A: correlation between cytotoxic T-lymphocytes (CD3+/CD56+) at 6 months and levels before the intervention ($r=0.490$; $P=.001$). Black circles: patients who developed restenosis. White circles: patients who did not develop restenosis. Dashed vertical and horizontal lines: maximum normal value of lymphocytes (10%). B: correlation between late inflammatory/immune response as represented by T-lymphocytes (CD3+/CD56+) and CD11b monocytes (fluorescence intensity expressed as arbitrary MFI units, $r=0.563$; $P=.0001$). All patients (22% of the sample) with high levels of T-lymphocytes above 10% (horizontal dashed line) and CD11b monocytes with >1000 MFI units (vertical line) developed restenosis.

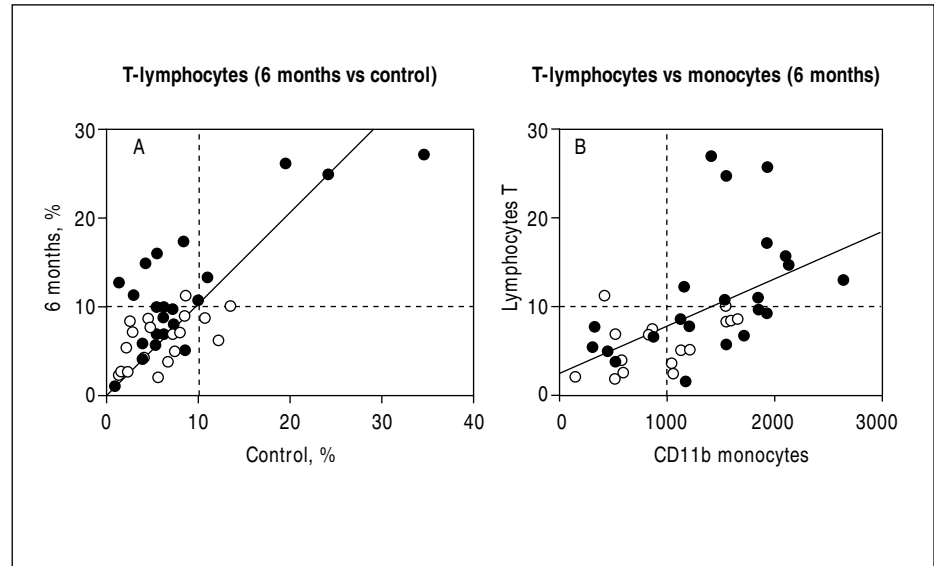
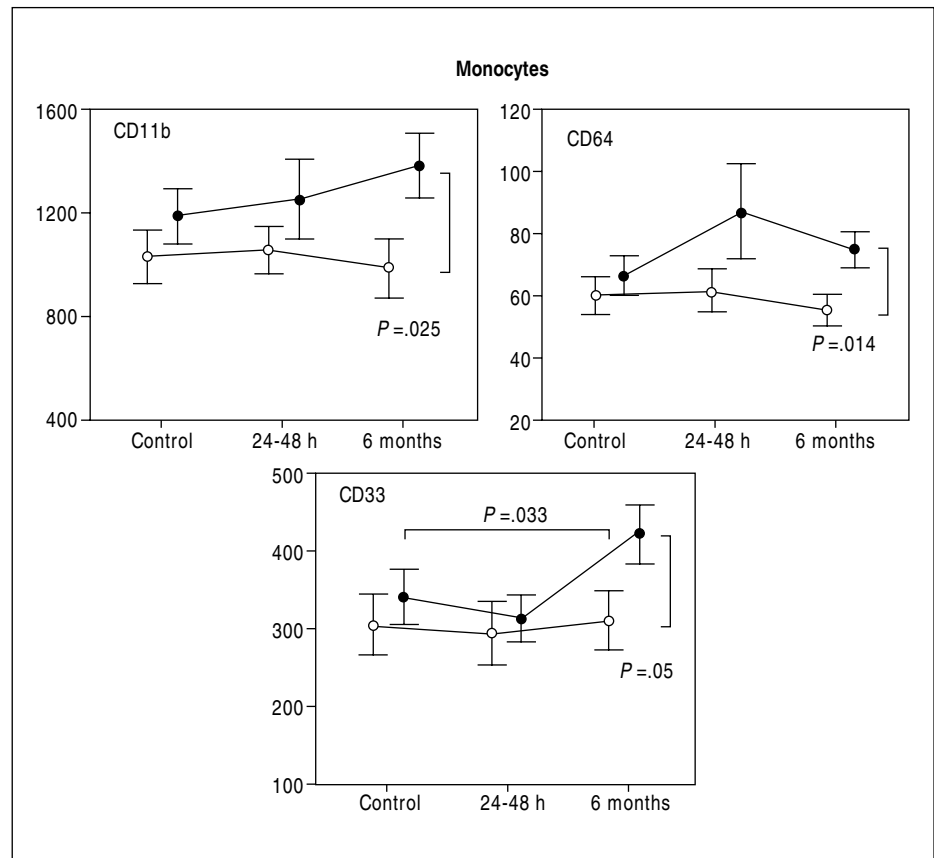


Fig. 3. Monocyte activation manifesting as the expression of CD11b, CD64 and CD33, before, 24-48 h, and 6 months after intervention. Black circles: patients who developed restenosis. White circles: patients who did not develop restenosis. X-axis: fluorescence intensity expressed as arbitrary MFI units \pm SEM. A significant increase in the expression of CD11b ($P=.033$) and CD64 ($P=.014$) can be observed at 6 months in patients who develop restenosis when compared to patients without restenosis. The expression of CD33 has increased at 6 months when compared to control values in patients with restenosis ($P=.033$).



Seropositivity values did not change markedly during the 6-months study period. Only one patient without previous exposure became positive after 6 months.

DISCUSSION

Acute inflammatory response

Although leukocyte activation as a response to TCPA did not reach statistically significant values, the increase in IL-6 and TNF- α concentrations after 24-

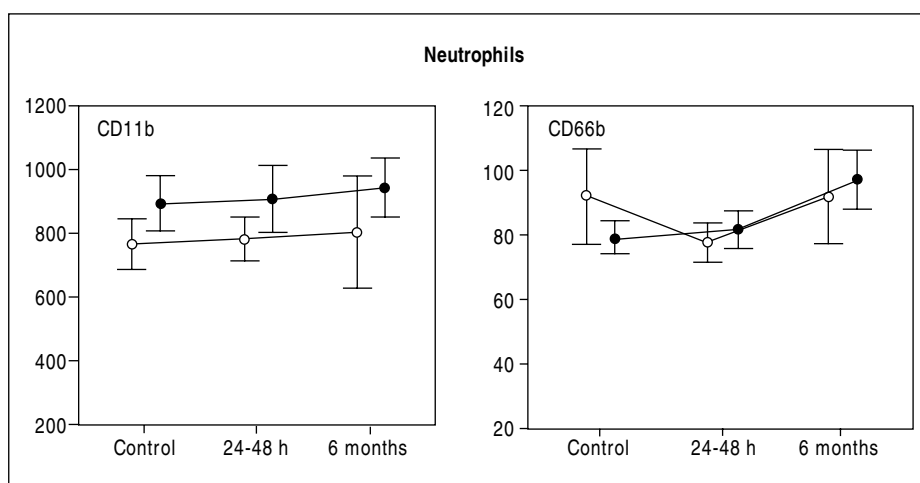


Fig. 4. Polymorphonuclear leukocyte activation in venous blood revealed by the expression of CD11b and CD66b, before, 24-48 h, and 6 months after intervention. Black circles: patients who developed restenosis. White circles: patients who did not develop restenosis. X-axis: fluorescence intensity expressed as arbitrary MFI units \pm SEM.

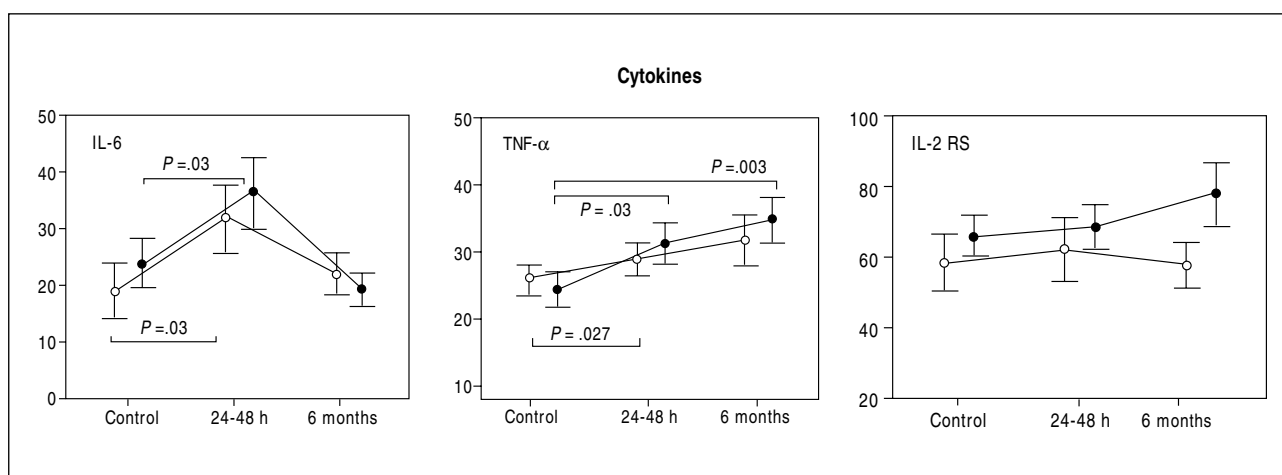


Fig. 5. Plasma concentration of IL-6, TNF- α and IL-2 sR before (control), after 24-48 h, and 6 months after intervention. Black circles: patients who developed restenosis. White circles: patients who did not develop restenosis. X-axis: ng/mL \pm SEM. See the text for details.

48 h revealed the well-known acute inflammatory response induced by vascular trauma which involved a chain of events: *a*) leukocyte activation upon passage through the coronary circulation, which is characterized by the expression of adhesion molecules such as CD11b/CD18(Mac-1), the ICAM-1 ligand in the cellular membrane;¹⁶⁻²⁰ *b*) the increase in IL-6 production by activated monocytes that stimulates the expression of adhesion molecules in injured tissue, and thus facilitates cellular infiltration and lesion-repairing processes,^{7,8} and *c*) the increase in the liver of C-reactive protein synthesis mediated by IL-6.^{9,10} This acute response is similar to that described in patients with unstable angina.²¹ In our study, monocyte and neutrophil activation showed very good correlation with the increase in IL-6 cytokines, suggesting that these markers are not very sensitive to PTCA-induced inflammation or that their activity peaks do not coincide.

Although this acute response may be related to the intensity of the vascular trauma, the post-PTCA increase in IL-6 and TNF- α shows very good correlation with pre-PTCA baseline values, regardless of whether patients underwent stent implants or atherectomy. This suggests that the intensity of the acute response may accurately reflect the sensitivity of the inflammatory/immune system to inflammation-producing stimuli.⁷ In some cases, leukocyte activation was increased at baseline, possibly suggesting an underlying chronic inflammatory process of low intensity which is believed to play an etiological role in ischemic heart disease.²²

However, we could not identify any relationship between inflammatory activity and plaque instability, as described previously, because there was no association with antecedents of a stable or unstable angina or the most recent episode of angina.

Some authors have speculated that the acute respon-

se might be a determinant of the magnitude of the scarring process in the lesion which, if excessive, might lead to obstructive hypertrophy of the intima.^{5,6} However, we found no relationship between restenosis and the intensity of the acute inflammatory response, leukocyte activation or baseline inflammatory activity.

Late inflammatory response: T-lymphocytes and inflammatory response

Our most important finding, for which we found no precedents in the literature, was that patients with restenosis showed an increase in inflammatory response that persisted 4-6 months after the intervention, as indicated by the increase in activated monocytes (inflammatory cells) and circulating cytotoxic T-lymphocytes (immune cells). T-lymphocytes have also been reported in the acute phase of PTCA¹⁶ and in patients with unstable angina.²³ The persistence of this chronic inflammatory state similar to that described in atherosclerotic lesions^{24,25} might cause restenosis to develop as suggested by the frequent observation of monocytes/macrophages and T-lymphocytes mainly of the cytotoxic/suppressor type in restenosis tissue.

The magnitude of this increase in the late inflammatory response may also be related to the underlying leukocyte activation already present before PTCA. This persistent hypersensitivity may be equated with that described in monocytes 6 months after the acute episode in unstable angina.²⁶ However, no evidence is available to explain the persistence of the inflammatory response.

Recently, the possibility that T-lymphocytes are involved in a specific autoimmune response that might promote inflammation has aroused great interest.²⁷⁻³¹ If this were the case, coronary diseases would have some resemblance to T-lymphocyte-dependant autoimmune diseases such as rheumatoid arthritis.³² This hypothesis is supported by reports of T-lymphocytes in the atheroma expressing IL-2 sR cytokine which is considered to be a definite sign that these cells are activated by plaque-specific antigens. This would mean that there is a local immune response.⁸ An increase in IL-2 sR plasma levels has been reported in stable and unstable angina, and it has been suggested that this increase could serve as a marker for restenosis.¹⁶ In our case, however, we found no relationship between IL-2 sR and restenosis. Therefore the increase we found in CD3/CD56 T-lymphocytes does not necessarily mean there is a specific immune response.

Inflammatory response and slow infections

The post-PTCA inflammatory response might be related to CMV infections or other latent infections frequently detected in atherectomy specimens.¹³ In fact,

the incidence of restenosis in patients who have undergone atherectomy is higher when they are CMV-seropositive (43%) than when they are CMV-seronegative (8%). Although our results do not confirm a relationship between restenosis or the inflammation markers under study and chronic or acute infection by *C. pneumoniae* or CMV, this could be due to the small size of our sample.

Study limitations. Could the inflammatory response be a consequence of restenosis?

Strictly speaking, and based on the data from this study, we cannot rule out the possibility of the inflammatory response being the effect rather than the cause of restenosis. Several explanations have been suggested for acute leukocyte activation in the microcirculation. For example, ischemia-reperfusion episodes, necrosis, or the persistence of a bleeding or inflamed surface in the coronary artery operated on or in other plaques, could explain this response, as leukocyte activation seems not to take place during passage through an intact stenosis.¹⁹ However, the absence of acute clinical episodes during PTCA follow-up in our sample makes it very unlikely that late leukocyte activation occurs through a similar mechanism.

The number of patients and the heterogeneity of the population under study, which included patients with stable and unstable angina of more than 1 week's duration, prevents us from elucidating whether there existed differences in baseline inflammatory activity attributable to recent coronary episodes or chronic underlying activity, or whether the late inflammatory response was more pronounced with stent implantation or atherectomies, even though the statistical analysis yielded negative results.

CONCLUSIONS

The increase in the late lymphocyte and monocyte inflammatory response reinforces the notion that an inflammatory process is involved in the pathogenesis of restenosis. The intensity of this response is related to the inflammatory state at baseline, which does not seem to be dependent on the existence of slow infections — such as those caused by *C. pneumoniae* — but rather suggests an autoimmune origin. The persistence of this inflammatory response could have clinical implications, because it suggests that prevention of restenosis might require measures that are not only restricted to the acute stage of the intervention, but should be extended for several months after PTCA.

ACKNOWLEDGEMENTS

This work was partly financed by a grant from the Spanish Ministry of Education (CICYT, SAF97-0124).

REFERENCES

- Ross R. Atherosclerosis—an inflammatory disease. *N Engl J Med* 1999;40:115-26.
- Moreno PR, Bernardi VH, López-Cuellar J, Newell J, McMellon C, Gold HK, et al. Macrophage infiltration predicts restenosis after coronary interventions in patients with unstable angina. *Circulation* 1996;94:3098-102.
- Kornowski R, Hong MK, Tio FO, Bramwell O, Wu H, Leon MB. In-Stent restenosis: contribution of inflammatory responses and arterial injury to neointimal hyperplasia. *J Am Coll Cardiol* 1998;31:224-30.
- Piek JJ, Van der Wal AC, Meuwissen M, Koch KT, Chamuleau SAJ, Teeleing P, et al. Plaque inflammation in restenotic coronary lesions of patients with stable and unstable angina. *J Am Coll Cardiol* 2000;35:963-7.
- Pietersma A, Kofflard M, De Wit EA, Stijnen T, Koster JF, Serruys PW, et al. Late lumen loss after coronary angioplasty is associated with the activation status of circulating phagocytes before treatment. *Circulation* 1995;91:1320-5.
- Inoue T, Sakai Y, Morooka S, Hayashi T, Takayanagi K, Takabatake Y. Expression of polymorphonuclear leukocyte adhesion molecules and its clinical significance in patients treated with percutaneous transluminal coronary angioplasty. *J Am Coll Cardiol* 1996;28:1127-33.
- Liuzzo G, Buffon A, Biasucci LM, Caligiuri G, Vitelli A, Altamura S, et al. Enhanced inflammatory response to coronary angioplasty in patients with severe unstable angina. *Circulation* 1998;98:2370-6.
- Linkoff AM, Kereiakes DJ, Mascelli MA, Deckelbaum LI, Barnathan ES, Patel KK, et al. Abciximab suppresses the rise in levels of circulating inflammatory markers after percutaneous coronary revascularization. *Circulation* 2001;104:163-7.
- Buffon A, Liuzzo G, Biasucci I. Preprocedural serum levels of C-reactive protein predict early complications and late restenosis after coronary angioplasty. *J Am Coll Cardiol* 1999;34:1512-21.
- Gottsauner-Wolf M, Zasmata G, Hornykewycz M. Plasma levels of C-reactive protein after coronary stent implantation. *Eur Heart J* 2000;21:1152-8.
- Libby P, Schwartz D, Brogi E, Taanaka H, Clinton SK. A cascade model for restenosis: a special case for atherosclerosis progression. *Circulation* 1992;86(Suppl III):47-52.
- Ramires JAF, Higuchi ML. *Mycoplasma pneumoniae* y *Chlamidia pneumoniae* se asocian con la inflamación y la rotura de las placas coronarias ateroscleróticas. *Rev Esp Cardiol* 2002;55(Supl 1):2-9.
- Zhou YF, Leon MB, Waclawiw MA, Popma JJ, Yu ZX, Finkel T, et al. Association between prior cytomegalovirus infection and the risk of restenosis after coronary atherectomy. *N Engl J Med* 1996;335:624-30.
- Bermejo García J, Martínez P, Martín Rodríguez JF, de la Torre Carpena M, Bustamante Bustamante R, Guerrero Peral AB, et al. Inflamación e infección en la enfermedad coronaria estable y en el síndrome coronario agudo. *Rev Esp Cardiol* 2001;54:453-9.
- Merino Otermin A, Artaiz Urdaci M, Bregada García J, Riera Sagrera M, Vidal Salvá B, Rodríguez Fernández A. El eptifibatide reduce los valores de proteína C reactiva tras angioplastia coronaria. *Rev Esp Cardiol* 2002;55:186-9.
- Blum A, Sclarovsky S, Shohat B. T lymphocyte activation in stable angina pectoris and after percutaneous transluminal coronary angioplasty. *Circulation* 1995;91:20-2.
- De Servi S, Mazzone A, Ricevuti G, Fioravanti A, Bramucci E, Angoli L, et al. Granulocyte activation after coronary angioplasty in humans. *Circulation* 1990;82:140-6.
- Ikeda H, Nakayama H, Oda T, Kuwano K, Yamaga A, Ueno T, et al. Neutrophil activation after percutaneous transluminal coronary angioplasty. *Am Heart J* 1994;128:1091-8.
- Neumann FJ, Ott I, Gawaz M, Puchner G, Schömig A. Neutrophil and platelet activation at balloon-injured coronary artery plaque in patients undergoing angioplasty. *J Am Coll Cardiol* 1996;27:819-24.
- Serrano C, Ramires JAF, Venturini M, Arie S, D'Amico E, Zweier JL, et al. Coronary angioplasty results in leukocyte and platelet activation with adhesion molecules expression. Evidence of inflammatory responses in coronary angioplasty. *J Am Coll Cardiol* 1997;29:1276-83.
- Mazzone A, De Servi S, Ricevuti G. Increased expression of neutrophil and monocyte adhesion molecules in unstable coronary artery disease. *Circulation* 1993;88:358-63.
- Haught WH, Mansour M, Rothlein R, Kishimoto TK, Mainolfi EA, Hendricks JB, et al. Alterations in circulating intercellular adhesion molecule-1 and L-selectin: further evidence for chronic inflammation in ischemic heart disease. *Am Heart J* 1996;132:1-8.
- Neri Serneri GG, Prisco D, Maretini F, Gori AM, Brunelli C, Poggessi L, et al. Acute T-cell activation is detectable in unstable angina. *Circulation* 1997;95:1806-12.
- Van der Waal AC, Piek JJ, de Boer OJ, Koch KT, Teeling P, van der Loos CM, et al. Recent activation of the plaque immune response in coronary lesions underlying acute coronary syndromes. *Heart* 1998;80:14-8.
- Van der Wal AC, Das PK, Bentz van de Berg D, van der Loos CM, Becker AE. Atherosclerotic lesions in humans. In situ immunophenotypic analysis suggesting an immune mediated response. *Lab Invest* 1988;61:166-70.
- Emeson EE, Robertson AL Jr. T lymphocytes in aortic and coronary intimas. Their potential role in atherogenesis. *Am J Pathol* 1988;130:369-76.
- Liuzzo G, Angiolillo DJ, Buffon A, Rizzello V, Colizzi C, Gineti F, et al. Enhanced response of blood monocytes to in vitro lipopolysaccharide-challenge in patients with recurrent unstable angina. *Circulation* 2001;103:2236-43.
- Blum A, Vardinon N, Kaplan G, Laniado S, Yust I, Burk M, et al. Autoimmune and inflammatory responses may have an additive effect in postpercutaneous transluminal coronary angioplasty restenosis. *Am J Cardiol* 1998;81:339-41.
- Caligiuri G, Liuzzo G, Biasucci LM, Maseri A. Immune system activation follows inflammation in unstable angina: pathogenic implications. *J Am Coll Cardiol* 1998;32:1295-304.
- Liuzzo G, Kopecky SL, Frye RL, O'Fallon M, Maseri A, Goronzy JJ, et al. Perturbation of the T-cell repertoire in patients with unstable angina. *Circulation* 1999;100:2135-9.
- Caligiuri G, Paulsson G, Nicoletti A, Maseri A, Hansson GK. Evidence for antigen-driven T-cell response in unstable angina. *Circulation* 2000;103:1114-9.
- Pascari V, Yeh ETH. A tale of two diseases. Atherosclerosis and rheumatoid arthritis. *Circulation* 1999;100:2124-6.