

Table

Percentage of Correct Responses Among the Students in the SAM Group According to Heart Sound*

Heart sound	Baseline, n (%)	Final, n (%)	Improvement, %	P
Mitral stenosis	6 (24)	18 (72)	48	<.001
Mitral regurgitation	11 (44)	22 (88)	44	<.001
Aortic stenosis	15 (60)	24 (96)	36	.001
Aortic regurgitation	8 (32)	22 (88)	56	<.001
Third sound	7 (28)	17 (68)	40	<.001
Fourth sound	2 (8)	9 (36)	28	.008
Pericardial friction rub	4 (16)	24 (96)	80	<.001
Normal	6 (24)	15 (60)	36	.001

SAM, Student Auscultation Manikin.

* The characteristics of the murmurs are specified in the description of the methods.

After training, both the students and residents in the SAM group showed a significant improvement in the percentage of correct responses, unlike the participants assigned to the control group. The rate of correct identification by the students in this group increased from 27% to 38% ($P=.2$), whereas the students in the SAM group improved from 25% to 70% ($P<.005$). The residents in the control group improved from 40% to 47% ($P=.4$); in contrast, the residents in the SAM group improved from 33% to 78% ($P<.005$).

The Table shows the changes in the percentages of correct diagnoses based on specific sounds after training in the SAM group. Recognition of the 8 sounds analyzed significantly improved.

Correct interpretation of heart sounds is a skill that requires training, and it is understood to be the task of medical schools to provide proper instruction in this area. However, this is not happening, and these skills—like other basic skills—are not being correctly taught or evaluated.^{4,5} The utilization of simulators appears to be an attractive training option. Their use for teaching cardiac auscultation has been validated in previous experiences. For example, Barrett et al.⁶ had participants listen to 4 cardiac murmurs 500 times using a simulator or recordings of murmurs on a compact disk, with a total of 6 h of training. Our protocol required fewer repetitions (300 per murmur) and less instruction time (2.2 h) with satisfactory results, and will help students to recognize murmurs in real patients.

In short, undergraduate and postgraduate students in our medical school correctly identify only about one third of the heart sounds they hear. A training program involving a heart sound simulator can significantly improve this skill. It would be interesting to reevaluate these students at distinct time periods to determine the need to repeat these modules throughout their training.

FUNDING

A resident fellowship from the Pontificia Universidad Católica de Chile.

Gonzalo Martínez, Eduardo Guarda,* Ricardo Baeza, Bernardita Garayar, Gastón Chamorro, and Pablo Casanegra

División de Enfermedades Cardiovasculares, Escuela de Medicina, Pontificia Universidad Católica de Chile, Santiago, Chile

*Corresponding author:

E-mail address: eguarda@med.puc.cl (E. Guarda).

Available online 13 July 2012

REFERENCES

1. Dolara A. The decline of cardiac auscultation. The ball of the match point is poised on the net. *J Cardiovas Med*. 2008;9:1173–4.
2. Shaver JA. Cardiac auscultation: a cost-effective diagnostic skill. *Curr Probl Cardiol*. 1995;20:441–530.
3. Mangione S. Cardiac auscultatory skills of physicians-in-training: comparison of three English-speaking countries. *Am J Med*. 2001;110:210–6.
4. Mangione S, Nieman LZ. Cardiac auscultatory skills of internal medicine and family practice trainees: A comparison of diagnostic proficiency. *JAMA*. 1997;278:717–22.
5. González-López JJ, Gómez-Arnau Ramírez J, Torremocha García R, Albelda Esteban S, Alió del Barrio J, Rodríguez-Artalejo F. Conocimientos sobre los procedimientos correctos de medición de la presión arterial entre estudiantes universitarios de ciencias de la salud. *Rev Esp Cardiol*. 2009;62:568–71.
6. Barrett MJ, Lacey CS, Sekara AE, Linden EA, Gracely EJ. Mastering cardiac murmurs: the power of repetition. *Chest*. 2004;126:470–5.

<http://dx.doi.org/10.1016/j.rec.2012.03.021>

Malignant Ventricular Arrhythmias During Surgical Procedures for Pacemaker Generator Replacement: Description of Two Cases

Arritmias ventriculares malignas durante cirugías de recambio de generador de marcapasos: descripción de dos casos

To the Editor,

Although electric scalpels or electrosurgery have provided a major advance in surgical procedures in general, they are a source of electromagnetic interference that may have an impact on patients with cardiovascular implantable electronic devices, especially when these are used in monopolar modality. This is the most common modality used except in the case of microsurgery or ophthalmic surgery procedures, in which bipolar electrocautery is more common. Thus, problems can arise such as

oversensing and pacing inhibition, irreversible damage to the generator, device reprogramming or resetting, inappropriate defibrillator therapy due to oversensing false tachyarrhythmias or even, in rare cases, the induction of potentially fatal arrhythmias.¹ In monopolar electrosurgery and electrocautery, the electric current is applied through the tip of the electric scalpel to the area of interest and from this point flows through the patient's body until reaching the large surface area return electrode, that is, the dispersive pad on the patient's skin.

We describe two cases in which malignant ventricular arrhythmias occurred in association with electrocautery during cardiovascular implantable electronic devices revision surgical procedures.

Case 1 was a 69-year-old man with hypertension and preserved ventricular function, who was admitted for elective replacement of a pacemaker generator which had reached its replacement date. For 9 years, he had a normally functioning dual-chamber

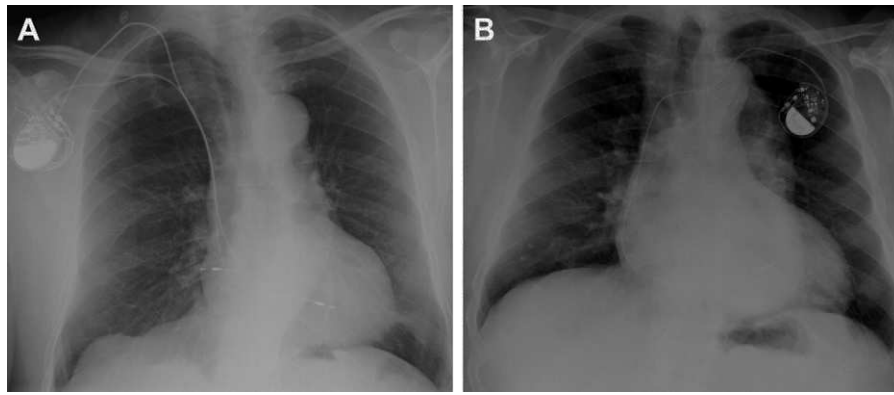


Figure 1. Posteroanterior chest radiograph of the patients in case 1 (A) and case 2 (B) after the first implantation.

pacemaker system (Vitatron Vita 2 model 830), with active fixation electrodes positioned in the right atrial appendage (Vitatron Crystalline ICL08JB-53 cm) and in the right ventricular septal wall (Vitatron Crystalline ICL08B-58 cm) (Fig. 1). Before surgery, the patient's own heart rate was confirmed at 60 bpm, with excellent sensing and stimulation parameters. To perform the procedure, the device was reprogrammed to VVI mode at 40 bpm in bipolar configuration. We used an electrocautery system (Valleylab Force FX) programmed for cutting and coagulation in monopolar mode (cutting power, 25 W; coagulation power, 35 W) with a dispersive pad positioned on the outside of the patient's right thigh. After incision with a conventional scalpel, electrocautery was used in monopolar mode throughout the procedure. During initial dissection of the subcutaneous tissue, and coinciding with the electrocoagulation of an arteriole at a pulse of no more than 3 s, the patient suddenly lost consciousness with ventricular fibrillation rhythm documented on the monitor. This was immediately treated using an external biphasic defibrillator to deliver a nonsynchronized shock of 200 J, converting to sinus bradycardia at 42 bpm (Fig. 2). At the time of the event, the generator was still within the fibrous capsule and connected to the electrodes. The patient regained consciousness without sequelae and the generator replacement procedure was completed without further

incident. We checked the sensing and stimulation parameters of the electrodes with the new generator implanted, which were similar to those observed before the procedure. No incidents were documented during post-discharge follow-up.

Case 2 was a 74-year-old man with a single-chamber pacemaker (Identity ADx SR 5180 and a Tendril 1888TC/58 pacing lead; St Jude Medical) (Fig. 1). The patient had hypertension with nonischemic dilated cardiomyopathy and severe left ventricular systolic dysfunction. He was admitted in order to upgrade to an implantable cardiac resynchronization therapy defibrillator for primary prevention. The device was programmed to VVI mode at 40 bpm in bipolar configuration; the patient's own heart rate was 50 bpm with excellent parameters. We used the same equipment as described in case 1, using the same electrocautery system in bipolar mode. When the fibrous capsule covering the generator was opened to release it—while applying short electrocautery pulses to the surface of the generator in contact with the fibrous tissue—the patient reported dizziness with very rapid wide QRS-complex regular tachycardia (Fig. 2), which was documented on the monitor, immediately followed by syncope. The tachycardia was terminated with a biphasic shock of 360 J. The procedure continued without further incident while contact between the tip of electric scalpel and the implanted generator and lead was

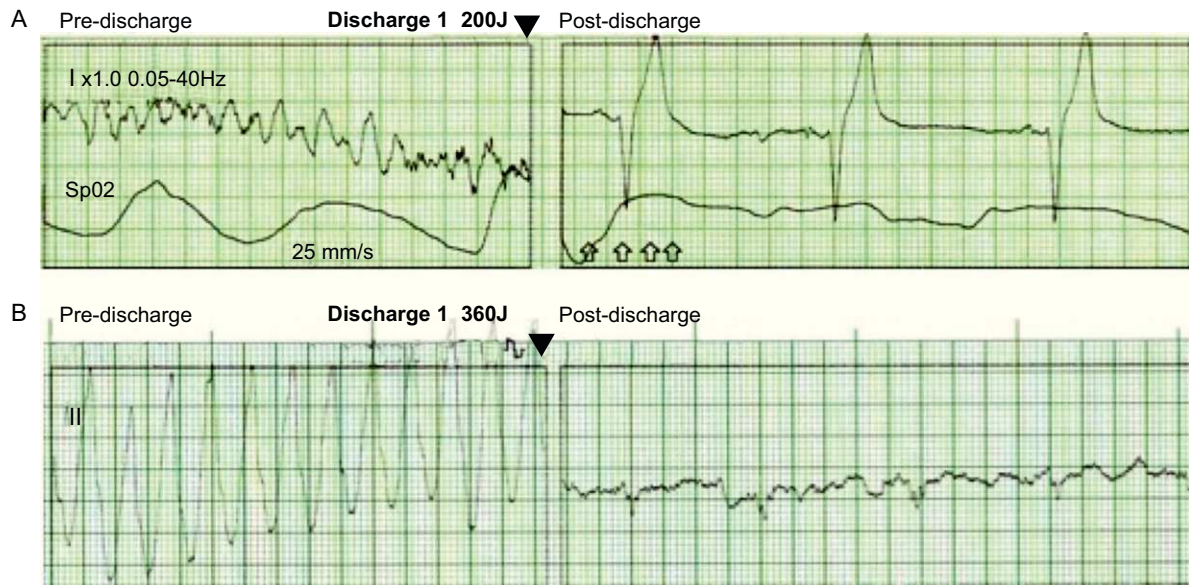


Figure 2. Rate trace of the patients in case 1 (A) and case 2 (B) from the external monitor-defibrillator during an induced malignant ventricular arrhythmia episode (left) and immediately after the shock applied (right).

avoided. One lead was implanted in the right atrium, 1 in the left ventricle and 1 for defibrillation in the right ventricular apex. The permanent pacemaker lead was left *in situ* with a silicone end-cap. No further incidents have been documented during patient follow-up.

In the cases presented, the mechanism underlying the induction of ventricular fibrillation could have been due to the continuous transmission—through the ventricular electrode to the interface with the myocardium—of the electrocautery radiofrequency pulses applied to the surrounding tissue or the pacemaker generator itself,² although long pulses were not applied and it was programmed in bipolar mode in both cases. The cases presented raise the issue of possible complications with the use of electrocautery, especially in patients with cardiovascular implantable electronic devices. Although the frequency of complications is low,² they are potentially fatal, and therefore a number of precautionary measures should be applied, including placing the dispersive pad as far from the generator as possible, reducing the energy pulses to less than 5 s' duration and, as a matter of course and in all cases, having continuous monitoring and advanced resuscitation equipment available during the procedure.³ Nevertheless, as long as the risk of bleeding is not especially high, a cold scalpel, with careful dissection followed by complete homeostasis, may be sufficient, thus completely avoiding the use of the electric scalpel in many of these interventions.

Marta Pachón, Miguel A. Arias,* Alberto Puchol, Miguel Jerez-Valero, and Luis Rodríguez-Padial

Unidad de Arritmias y Electrofisiología Cardíaca, Servicio de Cardiología, Hospital Virgen de la Salud, Toledo, Spain

*Corresponding author:

E-mail address: maapalomares@secardiologia.es (M.A. Arias).

Available online 17 July 2012

REFERENCES

1. Levine PA, Balady GJ, Lazar HL, Belott PH, Roberts AJ. Electrocautery and pacemakers: management of the paced patient subject to electrocautery. *Ann Thorac Surg.* 1986;41:313–7.
2. Lo R, Mittrache A, Quan W, Cohen TJ. Electrocautery-induced ventricular tachycardia and fibrillation during device implantation and explantation. *J Invasive Cardiol.* 2007;19:12–5.
3. Crossley GH, Poole JE, Rozner MA, Asirvatham SJ, Cheng A, Chung MK, et al. The Heart Rhythm Society (HRS)/American Society of Anesthesiologists (ASA) Expert Consensus Statement on the perioperative management of patients with implantable defibrillators, pacemakers and arrhythmia monitors: facilities and patient management. *Heart Rhythm.* 2011;8:1114–54.

<http://dx.doi.org/10.1016/j.rec.2012.04.008>

Cardiogenic Shock Secondary to Metamizole-induced Type II Kounis Syndrome

Shock cardiogénico secundario a síndrome de Kounis tipo II inducido por metamizol

To the Editor,

Although the first case was described more than 20 years ago, recent years have seen a marked increase in reports of cases of acute coronary syndrome in the context of allergic reactions, known as Kounis syndrome. Traditionally, 2 variants of the syndrome were reported: type I (due to coronary vasospasm), which occurs in patients with normal coronary arteries, and type II (due to coronary thrombosis) in patients with atherosclerosis.

This syndrome is triggered by the release of inflammatory mediators during mast cell degranulation, although these mediators are also increased in patients with acute coronary syndrome due to non-allergic causes.¹

Among the possible triggering factors of Kounis syndrome are hymenoptera stings, drugs, food, environmental exposure, and diverse conditions such as bronchial asthma, mastocytosis, etc. Any medication can cause this syndrome, but most cases have been reported in relation to beta-lactam antibiotics and non-steroidal anti-inflammatory drugs.

Although the pathophysiology of thrombosis of drug-eluting stents is multifactorial, a recent review by Chen et al.² states that Kounis syndrome can be one of the potential causes. The simultaneous use of drugs such as clopidogrel and acetylsalicylic acid in these patients may also act as a potential antigen. These findings have led to the recent proposal to create a new classification for Kounis syndrome that includes type III in relation to thrombosis of drug-eluting stents.³ There have also been reported cases of *tako-tsubo* cardiomyopathy associated with Kounis syndrome through the release of inflammatory mediators.⁴

We present the case of a 53-year-old woman who was receiving vildagliptin/metformin for type 2 diabetes mellitus and atorvastatin for hypercholesterolemia. She smoked 20 cigarettes a day, and had had an osteoporotic D12 vertebral fracture after physical effort 10 days previously, which was treated conservatively by fitting a corset brace and analgesia with paracetamol and ibuprofen. She went to the emergency department for intense back pain despite analgesic and anti-inflammatory treatment. Five minutes after receiving a vial of intravenous metamizole, she started to show generalized urticaria, chest pain, and intense dyspnea, accompanied by severe hypotension (systolic blood pressure: 70 mmHg). The initial electrocardiogram showed sinus tachycardia at 120 bpm with ST elevation in the anterior leads. Treatment began with volume replacement, steroids, and intravenous antihistamines. The patient was also administered 1 vial of subcutaneous adrenaline. Despite these measures, the patient remained in refractory shock, with worsening of the respiratory problems with progressive desaturation, requiring orotracheal intubation and mechanical ventilation. Noradrenaline and dobutamine perfusion was started and an intra-aortic balloon counterpulsation pump was fitted. The hemodynamics department was notified to perform an emergency cardiac catheterization, and the coronary angiography found thrombotic occlusion in the proximal portion of the anterior descending artery. A drug-eluting stent was implanted. An emergency echocardiogram showed antero-septo-apical hypokinesia, with a left ventricle ejection fraction of 35%. A Swan-Ganz catheter was inserted, which confirmed a low cardiac index and high peripheral vascular resistance, data that were compatible with cardiogenic shock. The serum creatine kinase and troponin T peak values were 2426 IU/L and 7.36 ng/mL, respectively. The patient's subsequent clinical course was satisfactory. Treatment with inotropic and vasopressor agents was gradually reduced until its withdrawal, while the intra-aortic balloon counterpulsation pump was removed after 48 h and the endotracheal tube after 3 days. Upon discharge, the patient received treatment