

Morphologies Suggestive of V₁ and V₂ Lead Misplacement

To the Editor:

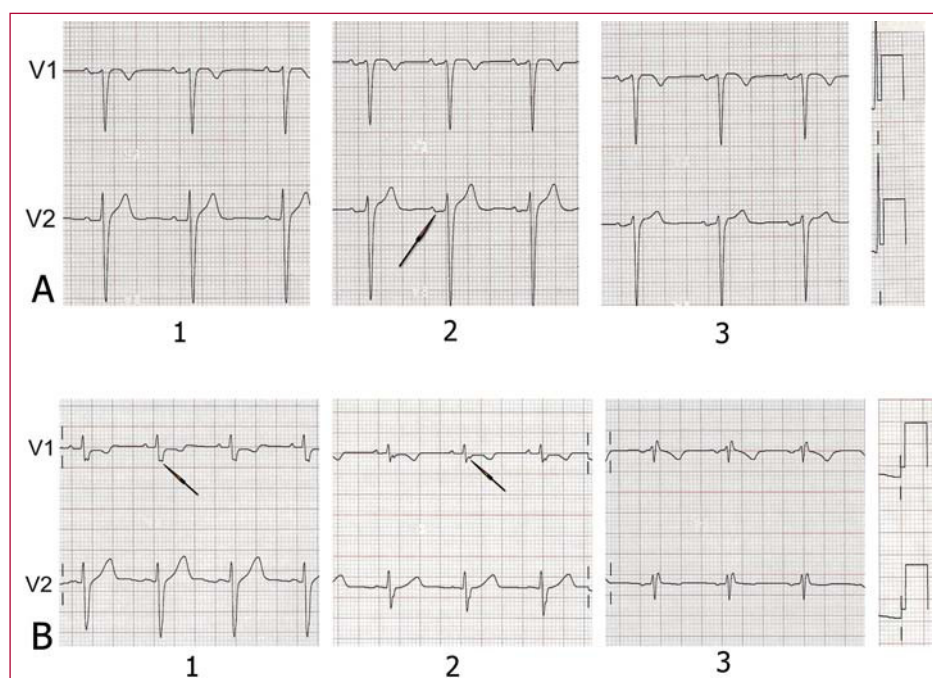
Many of the electrocardiograms (ECG) that are done every day present artefacts generated by inadequate placement of the electrodes.¹ It is very important for the correct interpretation of the ECG that the leads are situated in their assigned places. Variation in the placement of the precordial electrodes is a common source of error (Figure 1). Wenger et al² determined the differences in their placement among 30 experienced technicians as compared with their correct placement, and found that in over 50% of cases the V₁ and V₂ electrodes were placed above the fourth intercostal space. These electrodes are the “guide” electrodes for the other leads in the horizontal plane. From a clinical point of view, relevant changes

are produced in more than 50% of the automated interpretations of the ECG due to incorrect placement of the precordial electrodes.³ Important alterations are found in all the waves and all the segments of the ECG with the high recording of V₁ and V₂, identifying images that might lead to false diagnoses and important changes in the P wave,⁴ and an increase in the negative component is frequently recorded in this latter with the upward displacement of the V₁ and V₂ leads (Figure 2A). However, an exclusively or predominantly negative P wave in V₁, and sometimes in V₂, can be recorded with the electrodes correctly situated in persons with certain cardiac disorders that cause left atrial growth. As a result of the high placement of V₁, Bayés de Luna⁵ described the recording of the rSr' morphology accompanied by an exclusively negative P wave as a sign of incorrect placement (Figure 2B). The appearance of an rSr' electrocardiographic pattern in V₁ can be predicted if an r' of a certain magnitude is recorded in aVR or a notch in the ascending branch

Figure 1. Location of the angle of Louis to identify the second intercostal space and then the third and fourth intercostal spaces.

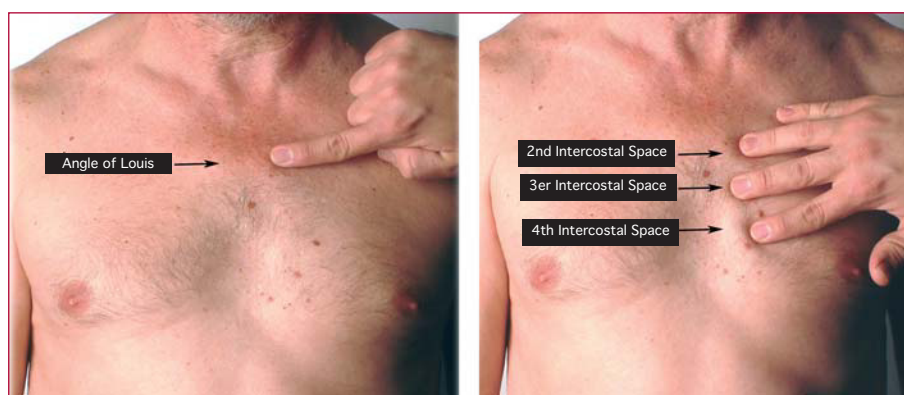

Figure 2. A: P wave with a normal morphology in V₁ and V₂ in the fourth intercostal space (1); in the third intercostal space (2), although the P wave in V₁ presents a morphology that might indicate correct placement, the diphasic P wave in V₂ (arrow) indicates a high placement; in the second intercostal space (3), the alterations are more obvious (3). B: rSr' morphology with a negative P wave in the second intercostal space (3), but not in the third (2), where the third vector presents in the upper branch of the S wave (arrow) and its nadir (arrow) when the electrodes are placed correctly (1).



of the S wave in V_1 with the electrode correctly placed. Here it is important to stress the importance of the correct placement of the V_1 and V_2 electrodes, especially in order not to diagnose that a patient has right bundle branch block when rSr' is recorded in V_1 . The presence of a negative P wave in the same lead, the duration of the $QRS \leq 0.1$ s and the disappearance of the rSr' morphology after placing electrodes in the fourth intercostal space ensure that it is due to incorrect placement of the leads and not to disease. Additionally, in this case the rSr' morphology presents a narrow r' , and although the T wave may be negative, there is no rise in the ST, which distinguishes it from the morphology seen in the Brugada syndrome.⁵

We must therefore suspect inadequate placement of the electrodes in a patient with no cardiac disorder who has an exclusively negative P wave in V_1 , especially if this is accompanied by a rSr' morphology. Additionally, the V_2 recording of the negative component of the P wave, on many occasions accompanied by a diphasic P wave in V_1 with a usual predominance of the negative

component, is also a firm indication of the high placement of these electrodes.

REFERENCES

1. Rudiger A, Hellermann JP, Mukherjee R, Follath F, Turina J. Electrocardiographic artifacts due to electrode misplacement and their frequency in different clinical settings. *Am J Emer Med.* 2007;25: 174-8.
2. Wenger W, Kligfield P. Variability of precordial electrode placement during routine electrocardiography. *J Electrocardiol.* 1996;29: 179-84.
3. Hill NE, Goodman J. Importance of accurate placement of precordial leads in the 12 leads in the 12 lead electrocardiogram. *Heart Lung.* 1987;16:561.
4. García Niebla J. Imágenes electrocardiográficas derivadas de una incorrecta colocación de los electrodos V_1 - V_2 . *Enferm Cardiol.* 2004;11:38-44.
5. Bayés de Luna A. Basic electrocardiography: Normal and abnormal patterns. Boston: Blackwell; 2007. p. 24-6.

Javier García-Niebla

Centro de Salud Valle del Golfo,
El Hierro, Santa Cruz de Tenerife, Spain