

Negative Contractile Reserve With Low-Dose Dobutamine in Patients With Ischemic Cardiomyopathy Investigated by Gated Myocardial Perfusion SPECT

Jaume Candell-Riera,^a Guillermo Romero-Farina,^a Marta Milá,^b Santiago Aguadé-Bruix,^b Gemma Cuberas,^a and David García-Dorado,^a on behalf of the RECAVA (Red temática de enfermedades Cardiovasculares) Research Team

^aServicio de Cardiología, Área del Corazón, Hospital Universitario Vall d'Hebron, Universidad Autónoma de Barcelona, Barcelona, Spain.

^bServicio de Medicina Nuclear, Hospital Universitario Vall d'Hebron, Universidad Autónoma de Barcelona, Barcelona, Spain.

Introduction and objectives. To investigate negative contractile responses in the left ventricle during low-dose dobutamine (LDD) gated single-photon emission computed tomography (SPECT) in patients with ischemic cardiomyopathy.

Methods. Sixty-eight consecutive patients (mean age, 60 [11] years; 7 male) with ischemic cardiomyopathy (ie, left ventricular ejection fraction [LVEF] $\leq 40\%$) were evaluated using gated-SPECT at rest and during LDD infusion. Associations between a negative contractile reserve (ie, a ≥ 1 -grade improvement in wall thickening score with LDD infusion) and scintigraphic viability criteria and coronary angiography findings were analyzed.

Results. Some 42.6% (29/68) of patients had a negative contractile reserve in one or more segments. In 14.7% ($n=10$), the LVEF decreased by $\geq 4\%$ with LDD. These patients had more segments with a negative contractile reserve ($2.8 [2.5]$ vs $0.87 [0.40]$; $P=.042$), and the cut-off value on receiver operating characteristic curve analysis was ≥ 2 segments with a negative contractile reserve (sensitivity 70%, specificity 74%, positive likelihood ratio 2.71, negative likelihood ratio, 0.40). Some 94% (74/79) of segments with a negative contractile reserve were in viable myocardium (ie, normal or viable on scintigraphy). Twelve of 17 segments with akinesia or severe hypokinesia and a negative contractile reserve satisfied scintigraphic viability criteria, with the majority (10/12) lying in territories supplied by a patent coronary artery.

Conclusions. A negative contractile reserve was not uncommon in patients with ischemic cardiomyopathy and was associated with a general decrease in left ventricular

systolic function. It was observed mainly in myocardial segments that appeared viable on scintigraphy and were supplied by a patent coronary artery.

Key words: Negative contractile reserve. Dobutamine. Gated-SPECT. Ischemic cardiomyopathy. Coronary anatomy.

Reserva contráctil negativa con bajas dosis de dobutamina en los pacientes con miocardiopatía isquémica estudiados mediante gated-SPECT de perfusión miocárdica

Introducción y objetivos. Analizar la respuesta contráctil negativa (RCN) del ventrículo izquierdo (VI) en la gated-SPECT con bajas dosis de dobutamina (BDD) en pacientes con miocardiopatía isquémica (MI).

Métodos. Se estudió prospectivamente a 68 pacientes (media de edad, 60 ± 11 años; 7 mujeres) con MI mediante gated-SPECT en reposo y durante la infusión de BDD. Se relacionó la RCN (aumento de la puntuación del engrosamiento ≥ 1 unidad) con los criterios gammagráficos de viabilidad y los resultados de la coronariografía.

Resultados. El 42,6% (29/68) de los pacientes presentó uno o más segmentos con RCN. En el 14,7% ($n = 10$) de los pacientes se observó una disminución de la fracción de eyección $\geq 4\%$ con las BDD. Estos pacientes se caracterizaron por tener un mayor número de segmentos con RCN ($2,8 \pm 2,5$ frente a $0,87 \pm 0,4$; $p = 0,042$), con un valor de corte en el análisis de curva ROC ≥ 2 segmentos con RCN (sensibilidad, 70%; especificidad, 74%; +LR, 2,71; -LR, 0,40). El 94% (74/79) de los segmentos con RCN correspondía a miocardio vivo (normal o viable gammagráficamente). De los 17 segmentos con acinesia o hipocinesia severa y RCN, 12 (71%) tenían criterios gammagráficos de viabilidad y en su mayoría (10/12) correspondían a territorios con arteria coronaria abierta.

Conclusiones. La RCN no es un fenómeno infrecuente en los pacientes con MI y se relaciona con una disminución de la función sistólica general del VI. Mayoritariamente se observa en segmentos con criterios gammagráficos de viabilidad y dependientes de una arteria coronaria abierta.

This study was partially financed by the Redes temáticas de enfermedades Cardiovasculares, Instituto Carlos III (Red C03/01, RECAVA).

Correspondence: Dr. J. Candell-Riera.
Servicio de Cardiología. Hospital Universitari Vall d'Hebron. Universitat Autònoma de Barcelona.
Pg. Vall d'Hebron, 119-129. 08035 Barcelona. Spain.
E-mail: jcandell@vhebron.net

Received December 18, 2008.

Accepted for publication November 11, 2009.

Palabras clave: *Respuesta contráctil negativa. Dobutamina. Gated-SPECT. Miocardiopatía isquémica. Anatomía coronaria.*

ABBREVIATIONS

CX: left circumflex artery
 EF: ejection fraction
 IC: ischemic cardiomyopathy
 LAD: left anterior descending artery
 LDD: low-dose dobutamine
 LV: left ventricle
 NCR: negative contractile response
 RCA: right coronary artery
 SPECT: single-photon emission computed tomography

INTRODUCTION

The noninvasive assessment of left ventricular contractile reserve is relevant to the clinical management of patients with ischemic heart disease and systolic dysfunction. Conventional imaging techniques that assess contractile reserve include echocardiography,¹⁻⁹ gated-SPECT,⁶⁻¹⁸ magnetic resonance imaging^{19,20} and, less frequently, cardiac computerized tomography²¹ and cardiac catheterization²² with low-dose dobutamine (LDD) infusion. At low doses, dobutamine can increase contractility without inducing ischemia. In clinical practice, the results of these tests provide relevant data that can influence decisions regarding treatment.

The analysis of left ventricular contractile reserve normally focuses on assessing improvements in myocardial wall thickening or contractility using LDD infusion or a biphasic response during echocardiography as indicators of myocardial viability. In general, less attention is paid to the segments in which contractility decreases with LDD (negative contractile response [NCR]). The aim of this study was to analyze, using gated-SPECT myocardial perfusion with LDD, the decrease in left ventricle (LV) wall segment thickening in patients with ischemic cardiomyopathy (IC) and its relationship to overall left ventricular systolic function, with evidence of viability provided by scintigraphy and with normal coronary anatomy.

METHODS

Patients

A total of 68 consecutive patients <75 years of age with a diagnosis of IC were assessed using gated-

SPECT myocardial perfusion at rest and during LDD infusion. The patients were recruited from 8 hospitals and, at the discretion of their clinical cardiologist, underwent gated-SPECT at rest for the myocardial viability study. The images were sent to a Centralized Imaging Unit for analysis. Ischemic cardiomyopathy was defined as confirmed coronary artery disease using contrast-enhanced coronary angiography, with LVEF $\leq 40\%$ during gated-SPECT myocardial perfusion at rest, and in the absence of other heart disease.²³ Exclusion criteria were previous coronary revascularization, cardiac pacemakers, and the presence of any other disease with poor short-term prognosis.

Design

The patients who had been assessed using gated-SPECT myocardial perfusion and fulfilled the selection criteria were given a new appointment and, after obtaining signed informed consent in each center within 10 days of the previous test, underwent gated-SPECT at rest using LDD and under uniform image acquisition protocols at each center. Image interpretation and statistical tests were conducted in the imaging unit of the coordinating center whose ethical committee had approved the study.

Gated-SPECT Using Low-Dose Dobutamine

First, a dose of 740 MBq to 925 MBq ⁹⁹Tc-tetrofosmin was injected at rest, and images acquired at rest 30 min later. Next, 5 $\mu\text{g/kg/min}$ dobutamine was infused over 3 min. The dobutamine dose was increased to 7.5 $\mu\text{g/kg/min}$ at the same time as a second gated-SPECT²⁴ acquisition procedure was conducted over 11 min, with continuous ECG monitoring and blood pressure checked every 3 min. Images were acquired using gamma cameras equipped with a high-resolution collimator, following a semi-circular orbit starting in the 30° right anterior oblique view with image capture every 3° until a 180° turn was completed in the left posterior oblique view. A 5th-order Butterworth filter at a cutoff frequency of 0.4 was used for image reconstruction. The images were obtained in short axis, horizontal long axis, and vertical long axis.

The LV was divided into 17 segments,²⁵ and a score was assigned to each one according to its degree of perfusion (0 = normal perfusion; 1 = mild hypoperfusion; 2 = moderate hypoperfusion; 3 = severe hypoperfusion; and 4 = no perfusion).²³ Two blinded observers made a semiquantitative analysis of each segment, assigning scores for both contractility and wall thickening (0 = normal; 1 = mild reduction; 2 = moderate reduction; 3 = severe reduction; and 4 = none).^{23,24}

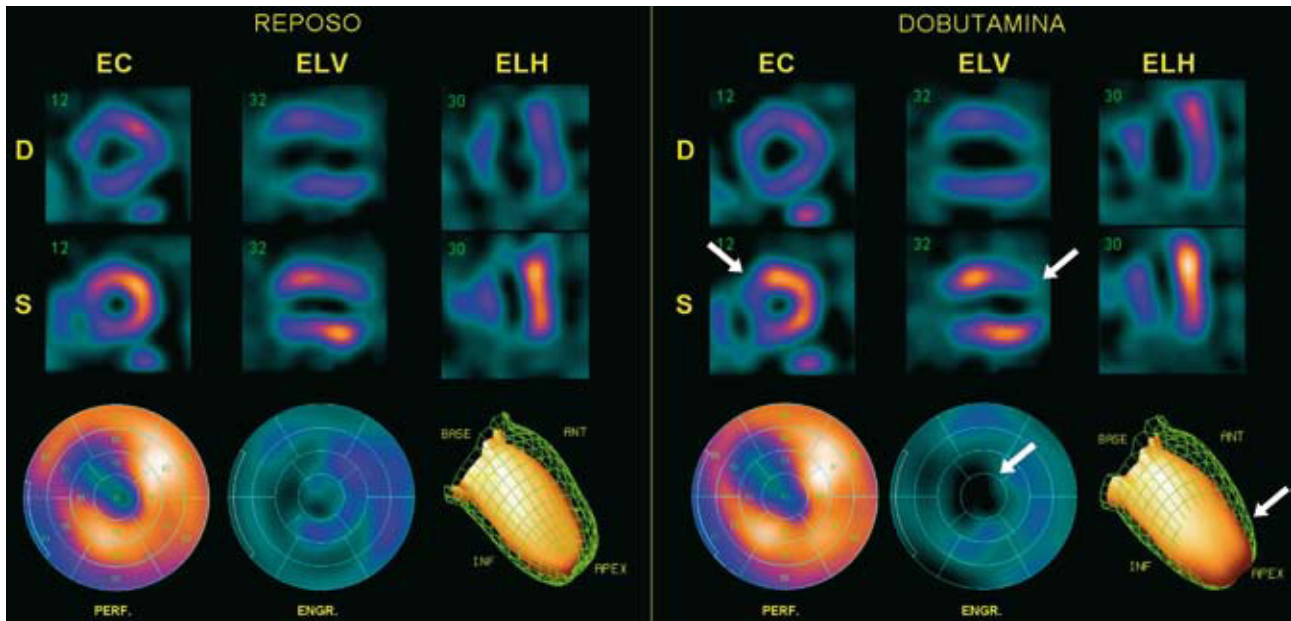


Figure 1. Gated-SPECT myocardial perfusion. Example of negative contractile reserve in the antero-septo-apical region during low-dose dobutamine (LDD) infusion. A decrease can be seen between rest (R) and LDD infusion in thickening and contractility of the antero-apical region (arrows), together with a decreased ejection fraction of 4%. ANT indicates anterior; D, diastole; EC, short axis; ELH, horizontal long axis; ELV, vertical long axis; ENGR, polar map of thickening; INF, inferior; PERF, polar map of perfusion; S, systole.

Segments were considered as viable on scintigraphy when they had a grade 3-4 contractility score and a grade 0, 1, or 2 perfusion score or when they had some baseline wall thickening or grades 0, 1, and 2 with LDD. A segment was considered contractile-reserve negative when the wall thickening score increased by ≥ 1 unit (Figure 1) during LDD infusion. The anterior, septal and apical segments (1, 2, 7, 8, 13, 14, 17) were assigned to the left anterior descending coronary artery (LAD); the lower segments (3, 4, 9, 10, and 15) to the right coronary artery (RCA); and the lateral segments (5, 6, 11, 12, 16) to the left circumflex artery.²⁵

Left ventricle ejection fraction and ventricular volumes (end-systolic volume [ESV] and end-diastolic volume [EDV]) during gated-SPECT at rest and during LDD infusion were measured using quantitative gated-SPECT methodology.²⁶ Inter-observer variability for LVEF assessed by gated-SPECT was 0.5 (2.6) points for LVEF as assessed in the imaging unit where these calculations were performed.²⁷

Coronary Angiography

In total, 68 patients were evaluated using contrast-enhanced coronary angiography. This was performed using one of the 2 Philips systems, either the Optimus M200 (biplane) or Integris (monoplane). In all cases, a field of view of 17.8 cm was used. The observer visually assessed coronary stenosis and this

assessment was confirmed by another interventional cardiologist. Significant coronary stenosis was considered present when this was $>50\%$ in any of the 3 main coronary vessels (LAD, CX, and RCA) and in the left main coronary artery. The coronary artery was considered open or non-occluded when stenosis was $<100\%$.

Statistical Analysis

Discrete variables are expressed as percentages and continuous variables as means (standard deviation). The χ^2 test was used to compare 2 independent discrete variables; when the number of expected values in one or more boxes in the contingency table was <5 , Fisher's exact test was used. The Student *t* test for independent samples was used to compare independent continuous variables; if the number of subjects was <30 , the Mann-Whitney test was used. The cut-off value for the number of segments with NCR able to cause a decrease in LVEF $>3\%$ was determined by analysis of the receiver operating characteristic (ROC) curves. The association between the decrease in LVEF (dependent variable) and the number of segments with NCR (independent variable) in each coronary territory was assessed by linear regression analysis adjusted for LVEF and resting volumes, age, and sex (ENTER method). The following variables were introduced into the model: NCR of the region under study, LVEF at rest, EDV

at rest, ESV at rest, age, and sex. All the variables were analyzed using the SPSS software package (SPSS, version 15, Chicago, IL, USA). A *P* value of $<.05$ was used as a cutoff for statistical significance.

RESULTS

The clinical characteristics of the 68 patients studied are shown in Table 1. No type of clinical, hemodynamic, or electrocardiographic complication was observed during LDD infusion. In total, 42.6% (29/68) of the patients presented one or more segments with NCR. The prevalence of segments with NCR during LDD infusion was 6.8% (79/1156 segments), corresponding to 6.9% (33/476) of the segments supplied by the LAD, 9.1% (31/340) of the segments supplied by the RCA, and 4.4% (15/340) of the segments supplied by the CX. All the segments with akinesia or severe hypokinesia ($n=476$) were segments with a grade 3-4 wall thickening score. The prevalence of NCR in these segments was 3.6% (17/476).

TABLE 1. Clinical, Scintigraphic, and Coronary Angiographic Characteristics of the Patients at the Time Inclusion in the Study

Age, mean (SD), y	60 (11.6)
Sex (women)	7 (10.3)
Hypertension	38 (55.9)
Diabetes mellitus	22 (32.4)
Smokers	43 (63.2)
Hypercholesterolemia	40 (58.8)
Previous infarction	64 (94.1)
Anterior infarction	50 (73.5)
Inferior infarction	14 (20.6)
CCS class I-II angina	9 (13.2)
CCS class III-IV angina	3 (4.4)
NYHA class I-II dyspnea	19 (27.9)
NYHA class III-IV dyspnea	8 (11.8)
Beta-blockers	35 (51.5)
Calcium channel blockers	4 (5.9)
ACEI or ARA-II	36 (52.4)
Nitrites	20 (29.4)
Gated-SPECT, mean (SD)	
LVEF, %	30.5 (8.5)
EDV, mL	193 (68)
ESV, mL	138 (61)
SPS at rest	27.7 (9.2)
STS at rest	31.2 (14.7)
Coronary angiography	
Occluded LAD	22 (32.4)
Occluded CX	6 (8.8)
Occluded RCA	14 (20.6)

ACEI indicates angiotensin-conversion enzyme inhibitors; ARA-II, angiotensin II receptor antagonists; CCS, Canadian Cardiovascular Society; CX, left coronary circumflex artery; LAD, left anterior descending coronary artery; NYHA, New York Heart Association; RCA, right coronary artery; SPS, summed perfusion score; STS, summed thickening score.

Data are expressed as n (%) or mean (standard deviation).

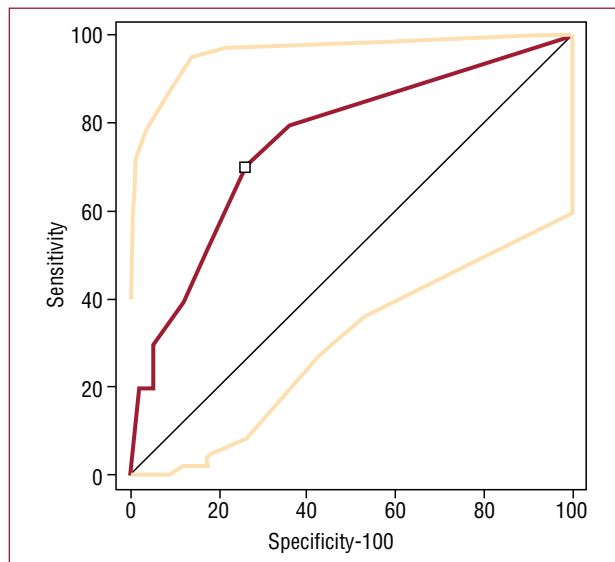


Figure 2. Determination of the cut-off value of the number of segments with negative contractile response (NCR) for a decrease in ejection fraction $\geq 4\%$ by analysis of receiver operating characteristic curves.

Negative Contractile Response and Overall Left Ventricular Systolic Function

The ROC curve analysis indicated a cutoff value of ≥ 2 segments with NCR for a 1-point decrease in LVEF $\geq 4\%$ (sensitivity, 70%; confidence interval [CI], 34.8-93; specificity, 74.14% [61%-84.7%]; positive likelihood ratio = 2.71; negative likelihood ratio = 0.40) (Figure 2). During LDD infusion, 35.3% ($n=24$) of the patients presented an increase in LVEF $< 4\%$, and 14.7% ($n=10$) of the patients presented a decrease in LVEF $\geq 4\%$. No clinical differences were observed between the patients with and without a decrease in LVEF $\geq 4\%$ (Table 2).

A linear, negative and significant association (adjusted for LVEF and resting volume, age, and sex) was observed between the number of segments with NCR in the territory of the LAD ($\beta = -1.98$; 95% CI, -3.19 to -0.75 ; $P = .002$; ANOVA, $F = 5.500$; $P < .001$; $r^2 = 0.4$) and the RCA ($\beta = -1.98$; 95% CI, -3.21 to -0.698 ; $P = .003$; ANOVA, $F = 5.296$; $P < .001$; $r^2 = 0.4$) in relation to the decrease in LVEF.

The patients with a decreased LVEF $\geq 4\%$ had a significantly greater number of segments with NCR (2.8 [2.5] vs 0.87 [0.4]; $P = .042$). A significant increase in ESV was observed in the patients with a decreased LVEF $\geq 4\%$ during LDD infusion, as well as a greater number of patients with ≥ 2 segments with NCR (Table 3).

Negative Contractile Response and Viability on Scintigraphy

During LDD infusion, greater NCR was observed in patients with baseline grade 0-2 wall thickening

TABLE 2. Clinical Characteristics of the Patients With and Without a Decrease in LVEF $\geq 4\%$

Variables	Decreased LVEF $\geq 4\%$ (n=10)	At Rest (n=58)	P
Age, mean (SD), y	60 (11.6)	61 (9.4)	.386
Sex (women)	1 (10)	6 (10.3)	.974
Hypertension	5 (50)	33 (57.8)	.642
Diabetes mellitus	2 (20)	20 (35)	.349
Smokers	5 (50)	38 (66.5)	.311
Hypercholesterolemia	5 (50)	35 (61)	.498
Previous infarction	9 (90)	55 (94.8)	.84
Anterior infarction	7 (70)	43 (74.1)	.87
Inferior infarction	2 (20)	12 (20.7)	.678
CCS class I-II angina	1 (10)	8 (13.8)	.744
CCS class III-IV angina	1 (10)	8 (13.8)	.201
NYHA class I-II dyspnea	2 (20)	17 (29.3)	.714
NYHA class III-IV dyspnea	1 (10)	7 (12.1)	.851
Beta-blockers	6 (60)	29 (50.8)	.736
Ca++ channel blockers	1 (10)	3 (5.2)	.485
ACEI or ARA-II	7 (70)	29 (50.7)	.320
Nitrites	4 (40)	16 (28)	.470

ACEI indicates angiotensin-conversion enzyme inhibitors; ARA-II, angiotensin II receptor antagonists; CCS, Canadian Cardiovascular Society; NYHA, New York Heart Association.

Data are expressed as n (%) or mean (standard deviation).

TABLE 3. Characteristics of Gated-SPECT and Coronary Angiography in Patients With and Without a Decrease in LVEF $\geq 4\%$

	Without a Decrease in LVEF $\geq 4\%$ (n=58)	With a Decrease in LVEF $\geq 4\%$ (n=10)	P
Gated-SPECT with LDD			
Δ ESV, mean (SD), mL	-7.58 (20)	9.3 (20)	.024
Δ EDV, mean (SD), mL	-0.96 (26.8)	-3.4 (27.5)	.652
≥ 2 segments with NCR	15 (25.9)	7 (70)	.010
Coronary angiography			
Number of patent arteries	2.41 (0.7)	2.2 (0.63)	.371
Patent LAD	41 (70.7)	5 (50)	.274
Patent RCA	46 (79.3)	8 (80)	.96
Patent CX	53 (91.4)	9 (90)	.97

CX indicates left circumflex artery; LAD, left anterior descending artery; NCR, negative response contractile; RCA, right coronary artery; Δ EDV, end-diastolic volume difference (dobutamine-rest); Δ ESV, end-systolic volume difference (dobutamine-rest).

Data are expressed as n (%) or mean (standard deviation).

compared to the segments with grade 3 wall thickening (16.43% vs 3.5%, respectively; difference, 16.9%; 95% CI, 5.8-20.7; $\chi^2=11.286$; $P<.001$).

A total of 40.9% (195/476) of the segments with severely decreased wall thickening (grade 3-4) in the baseline study corresponded to segments appearing viable on scintigraphy, since they presented grade 0-2 perfusion in the baseline images (Figure 3).

Of the 79 segments with NCR, 17 (21.5%) corresponded to segments with akinesia or severe hypokinesia, in which viability had to be studied. In total, 70.6% (12/17) of these were viable according to a perfusion score ranging from 0 to 2. The remaining 62 segments with NCR were located in regions which did not undergo a myocardial viability assessment, since under baseline conditions they presented normal perfusion or thickening or a mild-to-moderate decrease. Thus, 93.7% (74/79) of

the segments with NCR were associated with live myocardium (normal or viable), since only 6.3% (5/79) of the segments with NCR had scintigraphic signs of necrosis, defined as grade 4 perfusion plus grade 3-4 wall thickening (Figure 3).

Negative Contractile Response and Coronary Angiography

In total, 22.1% (15/68) of LAD presented ostial or proximal occlusion and 10.3% (7/68), medial or distal occlusion. Some 64.5% (21/33) of the anteroseptal segments with NCR were supplied by a patent LAD. Of the RCA segments, 10.3% (7/68) presented ostial or proximal occlusions and 10.3% (7/68) medial or distal occlusions. Some 87% (27/31) of the segments with NCR were supplied by a patent RCA, and 2.9% (2/68) of CX presented ostial or proximal occlusions

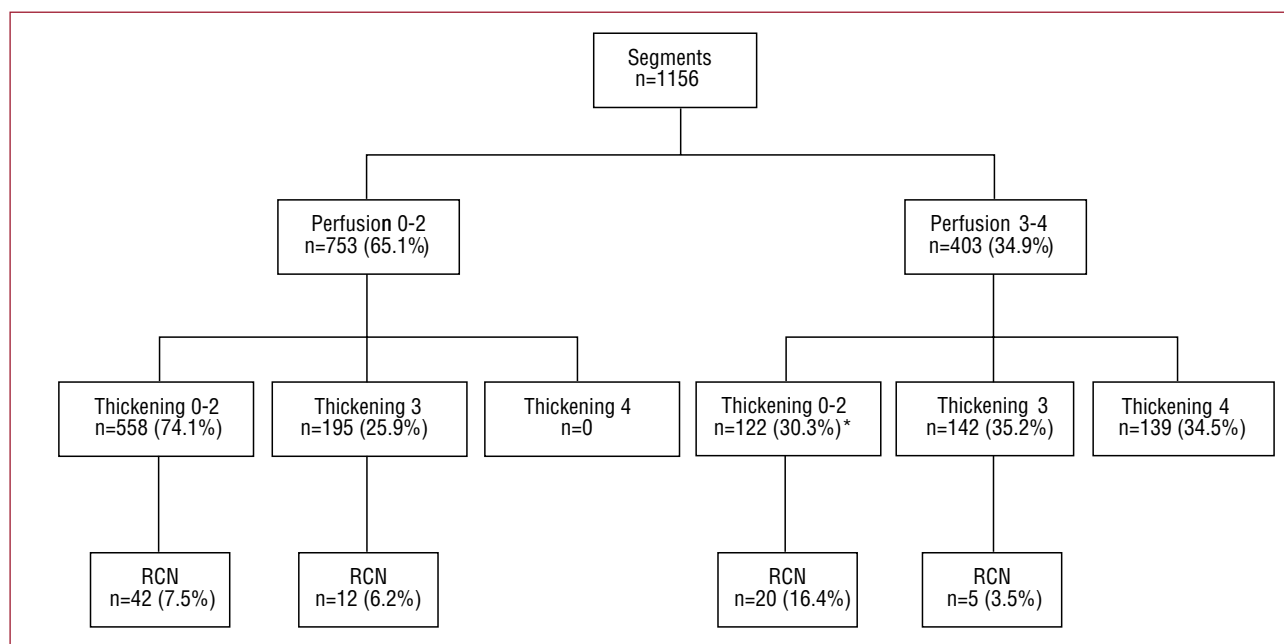


Figure 3. Flow chart of the 1156 segments associated with baseline perfusion, baseline thickening and negative contractile reserve (NCR). *All the segments had a baseline thickening score of 2.

and 5.9% (4/68) presented medial or distal occlusions. The CX was patent in 100% (15/15) of the segments with NCR in territories supplied by this artery.

Of the 12 viable segments with NCR, 83.3% (10/12) were associated with a patent coronary artery; 3 were in the territory of the LAD (all supplied by a patent artery), 7 in the territory of the RCA (5 with a patent artery), and 2 in the territory of the CX (both with a patent artery).

DISCUSSION

The segmental analysis of systolic thickening and left ventricular segmental contractility is complex. Generally, contractile reserve—segmentary or overall—is assessed during dobutamine infusion and it can be observed that some segments can respond with an increase, a decrease, or no change in wall thickening.²⁴ To date, echocardiographic,¹⁻⁹ nuclear cardiology,⁶⁻¹⁸ and magnetic resonance imaging studies¹⁹⁻²⁰ have highlighted positive contractile reserve as a synonym of myocardial viability. On the other hand, the significance of a deterioration in segmental systolic function or NCR due to an inotropic stimulus, which can significantly influence the decrease in LVEF, has received little attention.

This study investigated NCR in a population of patients with IC using gated-SPECT at rest to assess myocardial viability for medical reasons. The first and striking finding was that the prevalence of patients with 1 or more segments with NCR was 42.6%. Overall, 6.8% of the segments presented

this type of response, a similar percentage to that reported in an echocardiography study.¹⁷

In 14.7% of patients, LVEF decreased by $\geq 4\%$, a lower percentage than that found in other series (26%-31.2%), although these studies included patients with LVEF $> 50\%$.^{1,12} The patients with a decrease in LVEF of this magnitude were characterized by having more segments with NCR and a greater increase in end-systolic volume.

Another important finding to bear in mind is that the majority of the segments with NCR (93.6%) were in live myocardium (normal or viable on scintigraphy). On the other hand, most of the segments with akinesia or severe hypokinesia and NCR appeared viable on scintigraphy and were supplied by a patent coronary artery. The response of the cardiac muscle to an inotropic stimulus is due to a combination of different mechanisms; for example, parietal stress, the tethering effect,²⁸ high-energy phosphate concentrations, the number of normal segments that surround the area with changes in contractility,²⁹ and receptor response.³⁰ However, the mechanisms with the greatest influence on the negative response are parietal stress, the tethering effect and intracellular high-energy phosphate concentrations.

The NCR mechanisms underlying the segments assessed via LDD-SPECT imaging in our series may not be the same as those which induce NCR using high-dose dobutamine (biphasic response) in echocardiographic studies, since the negative component of the biphasic contractile response may

be caused by ischemia during high-dose dobutamine infusion.²⁹ Despite this, both responses are negative and have an impact on ventricular function.

Positron emission tomography (PET) studies have shown that the contractile response is always lower in segments with severe perfusion abnormalities at baseline.³¹ Our results show that the prevalence of NCR is also slightly lower when there are severe perfusion abnormalities on baseline SPECT imaging. These observations may indicate that as myocardial damage increases, a contractile response, whether positive (improvement) or negative (deterioration), is less likely.

Another relevant finding of this study is the association between segments with NCR and the patency of their respective coronary artery. Although TIMI flow and collateral circulation grades were not assessed, the fact that the majority of the segments did not have severely compromised wall thickening at baseline plus the presence of a patent coronary artery could be an indirect indicator of persistent coronary flow and myocardial viability.

Limitations

The number of patients included in this series was low, but it should be borne in mind that the number of patients with IC who undergo LDD gated-SPECT at rest for medical reasons in a single center is limited. For this reason, 8 hospitals participated and followed the same methodology. To keep inter-observer variation in interpreting the results to the minimum, all images were analyzed in a centralized imaging unit.

The criterion for a decrease in LVEF $\geq 4\%$ may seem arbitrary, but was this was agreed on after analyzing the best cutoff point on ROC curves, as described. This cutoff point appears to be clinically relevant and is similar to the one used in other series.^{12,27}

The lack of data on the collateral circulation, distal bed and TIMI flow grade is a limitation of the present study, since this data could have contributed additional information to the complex interpretation of the effect of LDD infusion. In any case, Barilla et al³² found that the recovery of contractility of dysfunctional viable myocardium supplied by occluded arteries during inotropic stimulation with LDD does not depend on increased coronary blood flow, and even occurs in the absence of collateral circulation.

This study does not provide data on exercise SPECT, which would have provided information on the possible presence of ischemia using LDD in the segments with NCR. However, Melon et al³³ have already demonstrated that the infusion of 10 $\mu\text{g}/\text{kg}/\text{min}$ dobutamine can cause ischemia in regions irrigated by severely stenotic arteries.

It should also be highlighted that the low number of patients ($n=10$) in one of the groups could have led to extreme and nonrobust results, and so they should be verified with a larger number of patients.

CONCLUSIONS

A negative contractile reserve on gated-SPECT at rest using LDD was not uncommon in patients with IC and was associated with a decrease in overall LV systolic function. It was mainly observed in segments meeting scintigraphic criteria of viability and that were supplied by a patent coronary artery. The majority of the segments with severe contractile dysfunction and NCR appeared viable on scintigraphy and were supplied by patent coronary arteries.

RECAVA RESEARCHERS (RED TEMÁTICA DE ENFERMEDADES CARDIOVASCULARES)

Gustavo de León,^a Joan Castell-Conesa.^b Hospital Universitari Vall d'Hebron, Barcelona, Spain.

Martín de la Fuente,^a Juan José Martínez Sampere.^b Hospital Clínico Universitario San Cecilio, Granada, Spain.

Maximiliano Diego Domínguez,^a Ricardo Ruano.^b Hospital Universitario, Salamanca, Spain.

José Alfonso Jurado López,^a María Jesús Pérez Castejón.^b Instituto de Cardiología, Madrid, Spain.

Jordi Magriñá Ballarà,^a M. África Muxí Pradas.^b Hospital Clínic, Barcelona, Spain.

Carlos Peña Gil,^a Virginia Pubul Núñez.^b Complejo Universitario Hospitalario, Santiago de Compostela. A Coruña, Spain.

José Antonio Ferrero Cabedo,^a Irene Casáns Tormo.^b Hospital Clínico, Valencia, Spain.

Miguel Hartáiz Urdaci,^a María José García Velloso.^b Clínica Universitaria de Navarra, Pamplona, Navarra, Spain.

^aServicio de Cardiología.

^bServicio de Medicina Nuclear.

REFERENCES

1. Everaert H, Vanhove Ch, Franken R. Low-dose dobutamine gated single-photon emission tomography: comparison with stress echocardiography. *Eur J Nucl Med*. 2000;27:413-8.
2. Leoncini M, Marcucci G, Sciagra R, Frascarelli F, Traini AM, Mondanelli D, et al. Nitrate-enhanced gated technetium 99m sestamibi SPECT for evaluating regional wall motion at baseline and during low-dose dobutamine infusion in patients with chronic coronary artery disease and left ventricular dysfunction: comparison with two-dimensional echocardiography. *J Nucl Cardiol*. 2000;7:426-31.
3. Leoncini M, Marcucci G, Sciagra R, Mondanelli D, Traini AM, Magni M, et al. Comparison of baseline and low-dose dobutamine technetium-99m sestamibi scintigraphy with low-

- dose dobutamine echocardiography for predicting functional recovery after revascularization. *Am J Cardiol.* 2000;86:153-7.
4. Yoshinaga K, Morita K, Yamada S, Komuro K, Katoh C, Ito Y, et al. Low-dose dobutamine electrocardiography-gated myocardial SPECT for identifying viable myocardium: comparison with dobutamine stress echocardiography and PET. *J Nucl Med.* 2001;42:838-44.
5. Leoncini M, Sciagra R, Bellandi F, Maioli M, Sestini S, Marcucci G, et al. Low-dose dobutamine nitrate-enhanced technetium 99m sestamibi gated SPECT versus low-dose dobutamine echocardiography for detecting reversible dysfunction in ischemic cardiomyopathy. *J Nucl Cardiol.* 2002; 9:402-6.
6. Hanekom L, Jenkins C, Jeffries L, Case C, Mundy J, Hawley C, et al. Incremental value of strain rate analysis as an adjunct to wall-motion scoring for assessment of myocardial viability by dobutamine echocardiography: a follow-up study after revascularization. *Circulation.* 2005;112:3892-900.
7. Rizzello V, Poldermans D, Schinkel AF, Biagini E, Boersma E, Elhendy A, et al. Long term prognostic value of myocardial viability and ischaemia during dobutamine stress echocardiography in patients with ischaemic cardiomyopathy undergoing coronary revascularisation. *Heart.* 2006;92: 239-44.
8. Schinkel AF, Poldermans D, Elhendy A, Bax JJ. Prognostic role of dobutamine stress echocardiography in myocardial viability. *Curr Opin Cardiol.* 2006;21:443-9.
9. Sawada SG, Safadi A, Gaitonde RS, Tung N, Mahenthiran J, Gill W, et al. Stress-induced wall motion abnormalities with low-dose dobutamine infusion indicate the presence of severe disease and vulnerable myocardium. *Echocardiography.* 2007;24:739-44.
10. Everaert H, Vanhove Ch, Franken R. Effects of low-dose dobutamine on left ventricular function in normal subjects as assessed by gated single-photon emission tomography myocardial perfusion studies. *Eur J Nucl Med.* 1999;26:1298-303.
11. Ruiz-Salmeron RJ, Ponce de León E, López A, Romeo D, del Campo V, Nandayapa R, et al. Capacidad del protocolo de gated-SPECT reposo/dobutamina para predecir la recuperación contráctil posrevascularización de áreas miocárdicas disínergicas. *Rev Esp Cardiol.* 2000;53:1052-62.
12. Everaert H, Vanhove Ch, Franken Ph. Assessment of perfusion, function, and myocardial metabolism after infarction with a combination of low-dose dobutamine tetrofosmin gated SPECT perfusion scintigraphy and BMIPP SPECT imaging. *J Nucl Cardiol.* 2000;7:29-36.
13. Yamagishi H, Akioka K, Hirata K, Sakanoue Y, Toda I, Yoshiyama M, et al. Dobutamine stress electrocardiography-gated Tc-99m tetrofosmin SPECT for detection of viable but dysfunctional myocardium. *J Nucl Cardiol.* 2001;8:58-66.
14. Leoncini M, Marcucci G, Sciagra R, Frascarelli F, Simonetti I, Bini L, et al. Prediction of functional recovery in patients with chronic coronary artery disease and left ventricular dysfunction combining the evaluation of myocardial perfusion and of contractile reserve using nitrate-enhanced technetium-99m sestamibi gated single-photon emission computed tomography and dobutamine stress. *Am J Cardiol.* 2001;87:1346-50.
15. Yoshinaga K, Katoh C, Noriyasu K, Yamada S, Ito Y, Kuge Y, et al. Low-dose dobutamine stress gated SPET for identification of viable myocardium: comparison with stress-rest perfusion SPET and PET. *Eur J Nucl Med Mol Imaging.* 2002;29:882-90.
16. Leoncini M, Sciagra R, Maioli M, Bellandi F, Marcucci G, Sestini S, et al. Usefulness of dobutamine Tc-99m sestamibi-gated single-photon emission computed tomography for prediction of left ventricular ejection fraction outcome after coronary revascularization for ischemic cardiomyopathy. *Am J Cardiol.* 2002;89:817-81.
17. Schinkel AF, Bax JJ, van Domburg R, Elhendy A, Valkema R, Vourvouri EC, et al. Dobutamine-induced contractile reserve in stunned, hibernating, and scarred myocardium in patients with ischemic cardiomyopathy. *J Nucl Med.* 2003;44:127-33.
18. Heiba SH, Abdel-Dayem HM, Gould R, Bernaski E, Marlote M, El-Zeftaway, et al. Value of low-dose dobutamine addition to routine dual isotope gated-SPECT myocardial imaging in patients with healed myocardial infarction or abnormal wall thickening by echocardiogram. *Am J Cardiol.* 2004;93:300-6.
19. Bree D, Wollmuth JR, Cupps BP, Krock MD, Howells A, Rogers J, et al. Low-dose dobutamine tissue-tagged magnetic resonance imaging with 3-dimensional strain analysis allows assessment of myocardial viability in patients with ischemic cardiomyopathy. *Circulation.* 2006;114:133-6.
20. Bove CM, DiMaria JM, Voros S, Conaway MR, Kramer CM. Dobutamine response and myocardial infarct transmural: functional improvement after coronary artery bypass grafting-initial experience. *Radiology.* 2006;240:835-41.
21. Habis M, Capderou A, Ghostine S, Daoud B, Caussin C, Riou JY, et al. Acute myocardial infarction early viability assessment by 64-slice computed tomography immediately after coronary angiography: comparison with low-dose dobutamine echocardiography. *J Am Coll Cardiol.* 2007;49:1178-85.
22. Sanchis J, Bodí V, Berenguer A, Insa L, Mainar L, Valls A, et al. Determinantes de la RC en la zona del infarto. Estudio cuantitativo mediante ventriculografía de contraste con dobutamina. *Rev Esp Cardiol.* 2000;53:617-24.
23. Romero-Farina G, Candell-Riera J, Aguadé-Bruix S, Castell-Conesa J, De León G. Analysis of apical remodeling in gated myocardial perfusion SPECT imaging in ischemic cardiomyopathy. *J Nucl Cardiol.* 2008;15:225-31.
24. Candell-Riera J, Romero-Farina G, Milá M, Aguadé-Bruix S; por el grupo de investigadores de RECAVA (Red temática de enfermedades cardiovasculares). Análisis del engrosamiento segmentario ventricular izquierdo con bajas dosis de dobutamina mediante gated-SPECT en la miocardiopatía isquémica. *Rev Esp Cardiol.* 2008;61:1061-9.
25. Cerqueira MD, Weissman NJ, Dilsizian V, Jacobs AK, Kaul S, Laskey WK, et al. Standardized myocardial segmentation and nomenclature for tomographic imaging of the heart: a statement for healthcare professionals from the Cardiac Imaging Committee of the Council on Clinical Cardiology of the American Heart Association. *Circulation.* 2002;105:539-42.
26. Germano G, Kiat H, Kavanagh PB, Moriel M, Mazzanti M, Su HT, et al. Automatic quantification of ejection fraction from gated myocardial perfusion SPECT. *J Nucl Med.* 1995;36:2138-47.
27. Castell-Conesa J, Aguadé-Bruix S, García-Burillo A, González JM, Canela T, Oller G, et al. Reproducibilidad de la gated-SPECT de perfusión miocárdica en la valoración de la función ventricular y su comparación con la ventriculografía isotópica. *Rev Esp Cardiol.* 2004;57:931-8.
28. Mazzadi AN, André-Fouët X, Costes N, Croisille P, Revel D, Janier MF. Mechanisms leading to reversible mechanical dysfunction in severe CAD: alternatives to myocardial stunning. *Am J Physiol Heart Circ Physiol.* 2006;291:H2570-82.
29. Afridi I, Kleiman NS, Raizner AE, Zoghbi WA. Dobutamine echocardiography in myocardial hibernation. Optimal dose and accuracy in predicting recovery of ventricular function after coronary angioplasty. *Circulation.* 1995;91:663-70.
30. Banas MD, Balda S, Suzuki G, Canty JM Jr, Fallavollita JA. Determinants of contractile reserve in viable, chronically dysfunctional myocardium. *Am J Physiol Heart Circ Physiol.* 2007;292:H2791-7.
31. Panza JA, Dilsizian V, Curiel RV, Unger EF, Laurienzo JM, Kitsiou AN. Myocardial blood flow at rest and contractile reserve in patients with chronic coronary artery disease and left ventricular dysfunction. *J Nucl Cardiol.* 1999;6:487-94.

32. Barilla F, de Vincentis G, Mangieri E, Ciavolella M, Pannitteri G, Scopinaro F, et al. Recovery of contractility of viable myocardium during inotropic stimulation is not dependent on an increase of myocardial blood flow in the absence of collateral filling. *J Am Coll Cardiol.* 1999;33:697-704.
33. Melon PG, de Landsheere CM, Degueldre C, Peters JL, Kulbertus HE, Pierard LA. Relation between contractile reserve and positron emission tomographic patterns of perfusion and glucose utilization in chronic ischemic left ventricular dysfunction: implications for identification of myocardial viability. *J Am Coll Cardiol.* 1977;30:1651-9.