

Image in cardiology

Optical Coherence Tomography in Complicated Coronary Angioplasty



Tomografía de coherencia óptica en angioplastia complicada

Pilar Carrillo,* Ramón López-Palop, and Alberto Cordero

Sección de Cardiología, Hospital Universitario de San Juan de Alicante, San Juan de Alicante, Alicante, Spain

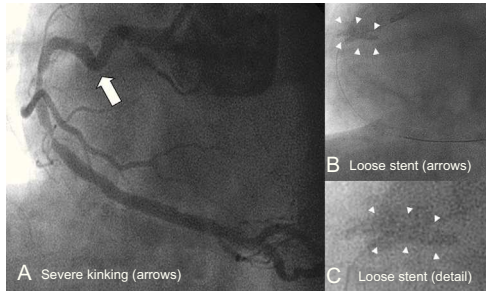


Figure 1.

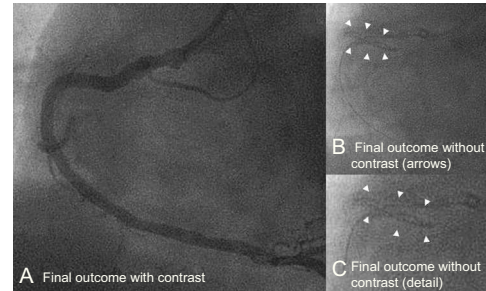


Figure 2.

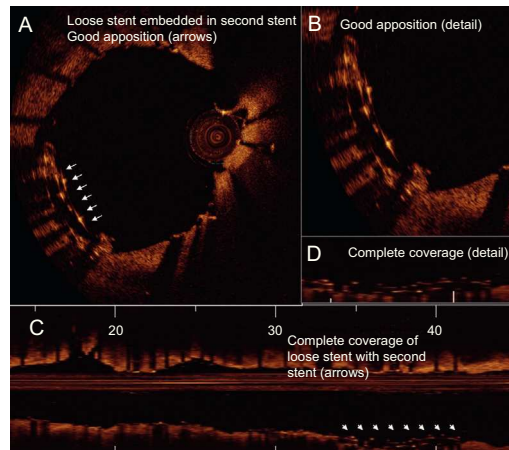


Figure 3.

A 70-year-old man was admitted to hospital with acute coronary syndrome with ST segment depression in inferior leads and elevated troponin. Coronary angiography revealed a lesion in the right coronary artery, after a tortuous and calcified proximal path (Figure 1A). After difficulties were encountered in advancing through the vessel, the lesion was predilated with a balloon and an unsuccessful attempt was made to place a 3 × 18 mm steel drug-eluting stent. On withdrawal of the device, it became detached in the proximal segment of the right coronary artery (Figures 1B and 1C).

Attempts to recover the stent with a balloon and with a loop were unsuccessful and it was decided to embed the stent, somewhat shortened by the salvage attempts, against the wall of the artery, with the support of a catheter guidewire and a second 3 × 24 mm cobalt-chromium drug-eluting stent outside the first stent, covering the distal lesion. After placement, the contrast-enhanced angiographic image was optimal (Figure 2A) but the contrast-free image of the loose stent was similar to that prior to placement of the second stent (Figures 2B and C).

Optical coherence tomography was performed to explain the angiographic image and to ensure appropriate apposition/deployment had occurred (Figures 3A and B). The second stent completely covered the first loose stent and apposition to the target segment of the coronary vessel was complete (Figures 3C and D). Antiplatelet therapy was doubled in intensity for 1 year. This case demonstrates the usefulness of invasive imaging techniques when angiography is insufficient for therapeutic decisions or for confirming the outcome of a complicated angioplasty.

* Corresponding author:
E-mail address: pcarrillosaez@gmail.com (P. Carrillo).
Available online 2 December 2014