

## Image in cardiology

## Paced Tachycardia by Biventricular Pacemaker



## Taquicardia estimulada por marcapasos biventricular

Marta Pachón, Irene Narváez, and Miguel A. Arias\*

Unidad de Arritmias y Electrofisiología Cardíaca, Servicio de Cardiología, Hospital Virgen de la Salud, Toledo, Spain

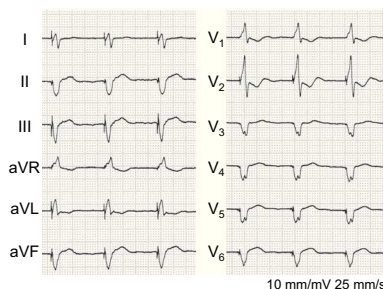


Figure 1.

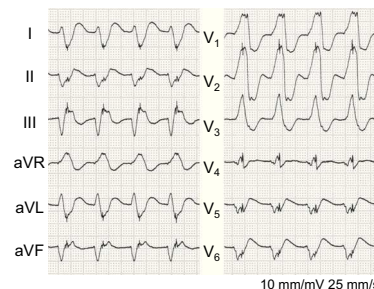


Figure 2.

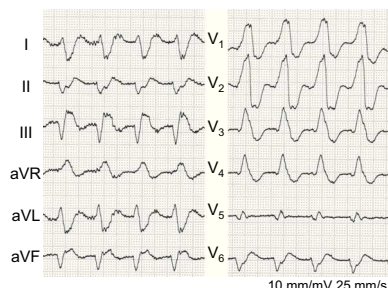


Figure 3.

A 61-year-old man with ischemic dilated cardiomyopathy and chronic atrial fibrillation, and being treated with amiodarone, complained of episodes of vertigo. He was found to have regular monomorphic wide QRS complex tachycardia at 104 bpm, with a self-limited pacemaker spike in the middle of each QRS complex (Figure 1). He had a biventricular pacemaker (Medtronic Syncra CRT-P) programmed in VVIR mode at 70 bpm to 130 bpm, with biventricular pacing of 98% (Figure 2). His arrhythmia was a sustained monomorphic ventricular tachycardia, as it was characterized as being a regular very wide QRS complex tachycardia in chronic atrial fibrillation, with right superior axis and initiation of ventricular activation preceding the pacing spikes. The benefits of cardiac resynchronization therapy are related to the achievement of rates of biventricular pacing near 100%. It is for this reason that current devices are accompanied by algorithms aimed at achieving biventricular pacing even during premature ventricular contractions or atrial fibrillation with native conduction. The prior activation of the ventricular sense response algorithm, programmed in this case for a maximum rate of 130 bpm, was what caused the pacing spikes in this monomorphic ventricular tachycardia to appear in the middle of each complex, as it detected ventricular events occurring below the programmed rate of 130 bpm (a circumstance that was probably related to the treatment with an antiarrhythmic agent), paced from both ventricular leads. This supposition was corroborated during an episode of tachycardia that occurred after the deactivation of the algorithm (Figure 3), in which the absence of pacing spikes was observed.

\* Corresponding author.

E-mail address: [maapalomares@secardiologia.es](mailto:maapalomares@secardiologia.es) (M.A. Arias).

Available online 21 February 2015