

## Percutaneous Closure of Patent Foramen Ovale in Young Patients With Cryptogenic Stroke: Long-Term Follow-up

Francisco Mazuelos, José Suárez de Lezo, Manuel Pan, Dolores Mesa, Mónica Delgado, Martín Ruiz, Soledad Ojeda, and Fátima Esteban

Servicio de Cardiología, Hospital Universitario Reina Sofía, Córdoba, Spain

Percutaneous closure of patent foramen ovale (PFO) has been proposed as a therapeutic option for cryptogenic stroke. The aim of this article was to describe the experience with this treatment at our center. Up until February 2006, percutaneous closure of PFO was carried out in 52 patients who presented with one or more cryptogenic strokes or transient ischemic attacks. The procedure was carried out under anesthesia and was guided by transesophageal echocardiography. The overall success rate was 100%. Transesophageal echocardiography carried out immediately after device implantation found no evidence of right-to-left shunting in 27 patients. During a mean follow-up of 26 months in 49 patients, none presented with a new ischemic episode or with complications attributable to the device. Echocardiographic follow-up showed that the foramen ovale had been completely sealed in all cases.

**Key words:** Patent foramen ovale. Cerebral ischemia. Percutaneous closure.

### Cierre percutáneo de foramen oval permeable en pacientes jóvenes con ictus criptogénico: seguimiento a largo plazo

El cierre percutáneo del foramen oval permeable es una de las opciones terapéuticas propuestas para el ictus criptogénico. El objetivo del presente trabajo es describir la experiencia de nuestro centro. Hasta febrero de 2006, se ha tratado con cierre percutáneo de foramen oval permeable a 52 pacientes que habían presentado uno o más ictus o ataques isquémicos transitorios criptogénicos. El procedimiento se realizó con anestesia y guiado por ecocardiografía transesofágica (ETE). La tasa de éxito primario fue del 100%. Inmediatamente tras el implante del dispositivo, en 27 pacientes no se observó paso derecha-izquierda por ETE. Tras un seguimiento clínico medio de 26 meses en 49 pacientes, ninguno ha tenido nuevos episodios isquémicos ni complicaciones atribuibles al dispositivo. El seguimiento ecocardiográfico mostró en todos un sellado completo del foramen oval.

**Palabras clave:** Foramen oval permeable. Isquemia cerebral. Cierre percutáneo.

## INTRODUCTION

Studies have shown the association between patent foramen ovale (PFO) and cryptogenic stroke. Currently, treatment of these patients is controversial, although data exist that favor percutaneous PFO closure.<sup>1</sup> The objective of the present report is to study immediate and long-term follow-up results for a consecutive series of patients with cryptogenic stroke and percutaneous PFO closure.

## METHODS

From January 2000 thru February 2006, 52 patients aged <60 years diagnosed with PFO and stroke underwent percutaneous closure in our hospital. All were diagnosed with acute stroke or transient ischemic attacks (TIA), and underwent full clinical examination (Table 1). Diagnosis of cardioembolic pathology was ruled out by echography. Foramen permeability was analyzed with Gelafundin 4% injected via a peripheral vein in baseline conditions and following the Valsalva maneuver.

Percutaneous foramen closure was indicated in patients with cryptogenic stroke, PFO, some of the following echocardiographic criteria, and considered at risk of new neurologic event as described elsewhere<sup>2,3</sup>: recurrence of neurologic clinical events, substantial contrast shunting at rest (>20 microbubbles), interatrial septal aneurysm (ISA) defined as  $\geq 11$  mm total excursion in left and/or

Correspondence: Dr. F. Mazuelos Bellido.  
Servicio de Cardiología. Hospital Reina Sofía.  
Avda. Menéndez Pidal, s/n. 14004 Córdoba. España.  
E-mail: franciscomazuelos@gmail.com

Received September 12, 2007.

Accepted for publication November 7, 2007.

**TABLE 1. Study Protocol**

Basic study
Full clinical record
12-Lead electrocardiogram
Chest x-ray
General analysis: routine blood, biochemical, and coagulation study
General hematologic study
Hypercoagulability study
Antiphospholipid syndrome study
Neurologic study
Cerebral imaging technique (computerized tomography [CT], magnetic resonance [MR])
Carotid Doppler and/or CT-Angio arteriography of supraaortic trunks, and/or MR-Angio and/or cerebral angiography
Cardiologic study
Transthoracic echocardiography
Transesophageal echocardiography

right atrium,<sup>4</sup> and substantial septum primum membrane mobility (>6 mm).

Implantation was undertaken with angiographic control and general anesthesia due to the difficulty entailed in keeping patients under transesophageal echocardiographic (TEE) monitoring during the procedure. Prior to implantation, pulmonary artery angiography in cava inferior was conducted to evaluate spontaneous left-to-right and

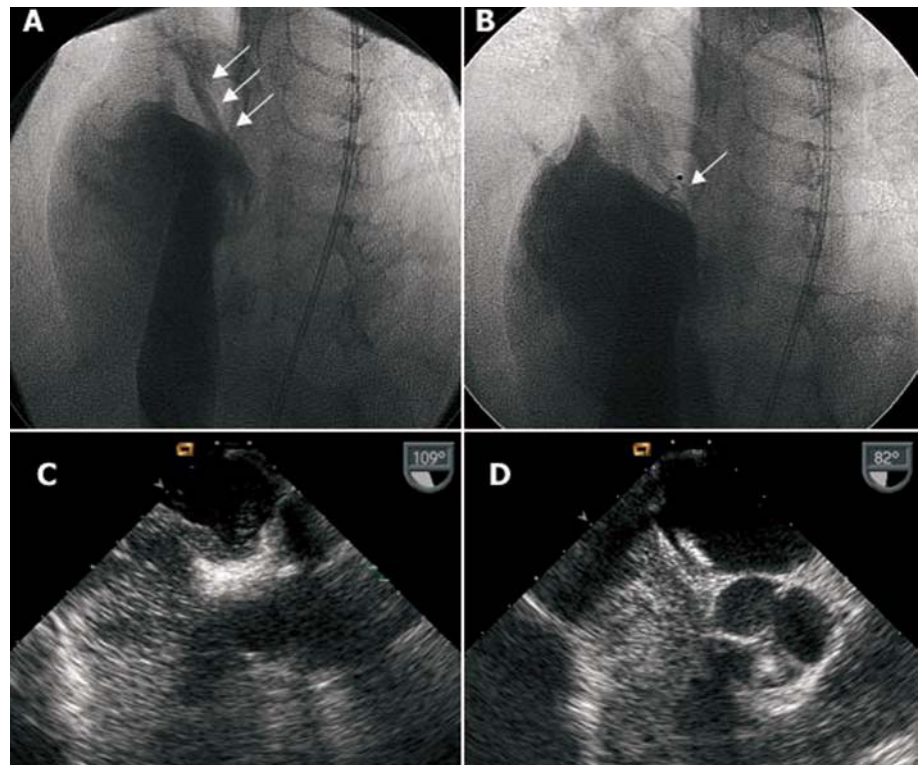
right-to-left shunting (Figure 1). Later echographic bubble contrast was injected to determine right-to-left shunting by TEE in baseline conditions and after the forced expiratory respiration maneuver; this was repeated after implantation (Figure 1).

We chose to deploy devices with a major diameter smaller than the total interatrial septum length determined by TEE retroaortic projection (Figure 2). In patients with septal aneurysm, we opted for a device slightly larger than the aneurysm base measure. Choice of device to deploy—Amplatzer (AGA Medical, Minnesota, USA), Intrasept (Cardia Inc., Minnesota, USA), or Helex (W.L. Gore, Arizona, USA)—was left to individual operators except in patients with septal aneurysm, when Amplatzer devices were always used. We had access to 18, 25, and 35 mm Amplatzer devices and 20, 25, and 30 mm Helex devices.

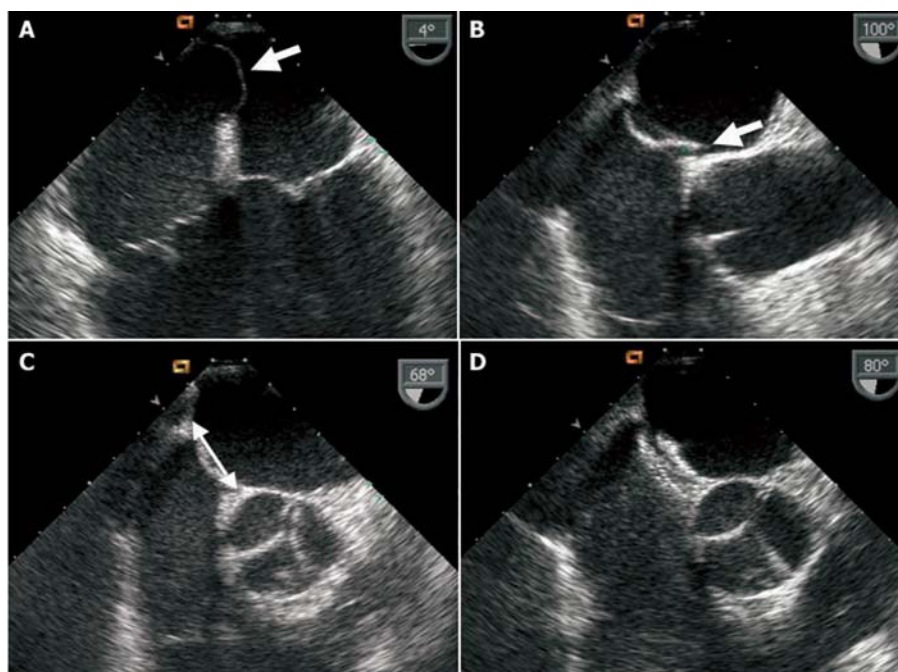
All patients received prophylactic antibiotic treatment following implantation and antithrombotic treatment with dalteparin (10 000 IU/day for 1 month) and aspirin (150 mg/day indefinitely).<sup>5,6</sup>

We conducted transthoracic echography (TTE) using second harmonic imaging and contrast prior to discharge and clinical follow-up and contrast echography at 6 months and 1 year, and in subsequent annual clinical follow-ups.

We present quantitative variables as mean (SD) and qualitative variables as percentages of the total. Data analysis was with SPSS 8.0.



**Figure 1.** A: baseline angiography with contrast injection in right atrium showing right-to-left shunting. B: angiography of implanted device, sealing foramen ovale, with contrast injection in right atrium. C: transesophageal echography of right-to-left contrast shunting. D: transesophageal echography of implanted device, without right-to-left shunting.



**Figure 2.** Transesophageal echography. A: aneurysm of interatrial septum. B: anatomic patent foramen ovale (arrow). C: measuring septum to choose device size (arrow). D: image of implanted device.

## RESULTS

We performed percutaneous PFO closure in 52 patients aged <60 years. Table 2 presents their clinical and echographic characteristics. Devices were successfully implanted in all patients. We used Amplatzer devices in 40 (76%) patients, Helex in 11 (22%), and Intrasept in 1. In 4 patients, we used an Amplatzer device for cribriform interatrial communication closure as they presented multiple membrane perforations. Device size was 35 mm in 25% of patients, 30 mm in 12%, 25 mm in 54%, and ≤20 mm in 10%.

All patients with ISA presented a base measure of >25 mm, so we used 35 mm Amplatzer devices. At the end of the procedure, we found residual bubble shunting in 12 patients (24%) in baseline situation and in 25 patients (48%) following forced expiration; this was considered mild in 11 patients.

No major complications or device embolization occurred. At discharge, we found residual shunting in 2 (4%) patients using contrast TTE.

We have conducted follow-up of 49 patients for a median of 26 months (range, 2-72; percentiles 25-75, 8-39). Three patients were lost to follow-up.

No clinical neurologic events, or events of any other type attributable to the procedure or device (endocarditis, embolization, fracture) occurred. At 6 months, the late TTE study found no residual shunting in any patient.

## DISCUSSION

Since Overell et al's meta-analysis,<sup>7</sup> the association between PFO and cryptogenic stroke has been clear and

**TABLE 2. Patients' Baseline and Echographic Characteristics**

Patients, n	52
Age, median (percentiles 25-75)	45.5 (35-54)
Gender (men/women)	26/26
Cardiovascular risk factors, %	
Smoking	49
Obesity	31
Hypercholesterolemia	28
Arterial hypertension	17
Diabetes mellitus	8
Oral contraceptives (% of women)	7
Patients with ≥2 cardiovascular risk factors, %	7
Characteristics of neurologic event, %	
Stroke type	
TIA	70
ACV	30
Number of strokes, %	
1 Single episode	74
2 Events	13
≥2 Events	13
Accompanied by migraine	11
Related with Valsalva maneuver	3
Baseline echographic characteristics, %	
Interatrial septal aneurysm	42
Substantial septum primum membrane mobility	17
Contrast shunting in baseline situation	86
Substantial baseline shunting	24
Contrast shunting with Valsalva maneuver	100
Substantial shunting with Valsalva maneuver	82

contrast TEE has proven the most adequate method of diagnosis.<sup>8</sup> In patients with PFO, several studies have

described risk factors for stroke<sup>3</sup> similar to those we used as indications for closure.<sup>9</sup>

In the absence of randomized studies comparing medical treatment with percutaneous closure, the high rate of recurrence with medical treatment, as much as 13%,<sup>10</sup> and the existence of studies that favor percutaneous closure<sup>11</sup> make this a widely-used option. In Spain, in 2005, 182 percutaneous PFO closure procedures were performed.<sup>12</sup>

Incidence of recurrence following closure varies, ranging from 0.6% to 7.8%.<sup>11</sup> In our study, there has been no recurrence. This may be due to the antithrombotic drug regimen used—not described in other studies—possible favoring adequate, rapid sealing of the device without thrombotic aggregation. Despite residual shunting following discharge in 4%, at 6-month echocardiographic follow-up no patient presented shunting, which coincides with results described elsewhere.<sup>13</sup> In contrast, the major complications associated with percutaneous closure—in 1.5% of patients in the series described<sup>1</sup>—were not present in our study.

While procedures were conducted with TEE guidance, anesthesia can be avoided by using intracavity echography.

In our experience, percutaneous closure is a safe option in young patients with cryptogenic stroke and PFO, without recurrence or events in the long-term.

### Limitations

The absence of a control group of patients with cryptogenic stroke and PFO treated medically prevents us from comparing both therapeutic options, but the rate of recurrence of neurologic events in patients with medical treatment was what motivated our decision to use percutaneous closure. The late evolution of these patients seems to endorse this decision. The finalization of randomized studies under way at the time of writing, and prolonged follow-up should lead to a more definitive ratification of these findings.

### REFERENCES

1. Khairy P, O'Donnell CP, Landzberg MJ. Transcatheter closure versus medical therapy of patent foramen ovale and presumed paradoxical thromboemboli: a systematic review. *Ann Intern Med.* 2003;139:753-60.
2. Mas JL, Arquizan C, Lamy C, Zuber M, Cabanes L, Derumeaux G, et al. Recurrent cerebrovascular events associated with patent foramen ovale, atrial septal aneurysm, or both. *N Engl J Med.* 2001;345:1740-6.
3. Mesa D, Franco M, Suárez de Lezo J, Muñoz J, Rus C, Delgado M, et al. Prevalencia de foramen oval permeable en pacientes jóvenes con accidente isquémico cerebral de causa desconocida. *Rev Esp Cardiol.* 2003;56:662-8.
4. Pearson AC, Nagelhout D, Castello R, Gomez CR, Labovitz AJ. Atrial septal aneurysm and stroke: a transesophageal echocardiographic study. *J Am Coll Cardiol.* 1991;18:1223-9.
5. Pan M, Suárez de Lezo J, Medina A, Romero M, Segura J, Mesa D. Tratamiento percutáneo de los aneurismas del septo interauricular. *Rev Esp Cardiol.* 2005;58:222-6.
6. Rodríguez M, Suárez de Lezo J, Pan M, Romero M, Segura J, Pavlovic D, et al. Cierre percutáneo de comunicaciones interauriculares grandes. *Rev Esp Cardiol.* 2003;56:888-93.
7. Overell JR, Bone I, Lees KR. Interatrial septal abnormalities and stroke: a meta-analysis of case-control studies. *Neurology.* 2000; 55:1172-9.
8. Hara H, Virmani R, Ladich E, Mackey-Bojack S, Titus J, Reisman M, et al. Patent foramen ovale: current pathology, pathophysiology, and clinical status. *J Am Coll Cardiol.* 2005;46:1768-76.
9. de Castro S, Cartoni D, Fiorelli M, Rasura M, Anzini A, Zanette EM, et al. Morphological and functional characteristics of patent foramen ovale and their embolic implications. *Stroke.* 2000;31:2407-13.
10. Nedeltchev K, Arnold M, Wahl A, Sturzenegger M, Vella EE, Windecker S, et al. Outcome of patients with cryptogenic stroke and patent foramen ovale. *J Neurol Neurosurg Psychiatry.* 2002; 72:347-50.
11. Windecker S, Wahl A, Nedeltchev K, Arnold M, Schwerzmann M, Seiler C, et al. Comparison of medical treatment with percutaneous closure of patent foramen ovale in patients with cryptogenic stroke. *J Am Coll Cardiol.* 2004;44:750-8.
12. Registro Español de Hemodinámica. Sección de Hemodinámica. SEC; 2005 [citado 7 Sep 2007]. Disponible en: [http://www.hemodinamica.com/C\\_enlaces/sec\\_actividad/reg\\_anual/resultados/2005\\_v1\\_04062006.pdf](http://www.hemodinamica.com/C_enlaces/sec_actividad/reg_anual/resultados/2005_v1_04062006.pdf)
13. Braun M, Gliach V, Boscheri A, Schoen S, Gahn G, Reichmann H, et al. Transcatheter closure of patent foramen ovale (PFO) in patients with paradoxical embolism. Periprocedural safety and mid-term follow-up results of three different device occluder systems. *Eur Heart J.* 2004;25:424-30.