

Permanent His-Bundle Pacing in Patients With Infra-Hisian Atrioventricular Block

Rafael Barba-Pichardo,^a Pablo Morfía-Vázquez,^a José Venegas-Gamero,^a Fernando Maroto-Monserrat,^a Manuela Cid-Cumplido,^b and Manuel Herrera-Carranza^a

^aUnidad de Arritmias y Marcapasos, Servicio de Cuidados Críticos y Urgencias, Hospital Juan Ramón Jiménez, Huelva, Spain.

^bServicio de Cuidados Intensivos, Hospital Reina Sofía, Córdoba, Spain.

Introduction and objectives. Permanent His-bundle pacing is effective in patients with supra-Hisian atrioventricular block. We report our experience in patients with infra-Hisian atrioventricular block.

Methods. The study involved selected patients referred for syncope and intraventricular conduction disturbance, infra-Hisian atrioventricular block, with left ventricular dyssynchrony and no coronary sinus access. All patients underwent electrophysiological study to evaluate infra-Hisian atrioventricular conduction, both at baseline and after flecainide administration. We selected patients with an indication for permanent pacing in whom His-bundle pacing produced a narrow QRS complex. Leads were implanted in the right atrium, in the bundle of His, and at the apex of the right ventricle, and connected to the atrial, left ventricular, and right ventricular terminals, respectively, of a biventricular pacemaker generator. All pacemakers were programmed in DDD mode with a left ventricle-right ventricle interval of 80 ms.

Results. Between February and December 2004, 7 patients met the study's inclusion criteria. The His-bundle lead was implanted successfully in 5. The His-bundle pacing threshold remained stable in 2 patients, whereas it increased in 3. During follow-up, at between 2 and 12 months, no lead dislodgement or failure to capture was observed. Echocardiography did not disclose any deterioration in ventricular function, or any worsening of or new valvular incompetence, but showed that ventricular dyssynchrony had disappeared in previously affected patients.

Conclusions. His-bundle pacing is the only pacing mode capable of inducing a physiologically normal ventricular contraction. It can be used in some patients with infra-Hisian atrioventricular block.

Key words: Bundle branch block. His bundle pacing. Atrioventricular block. Cardiac pacing.

Estimulación hisiana definitiva en pacientes con bloqueos infrahisianos

Introducción y objetivos. La estimulación permanente del haz de His es eficaz en los bloqueos auriculoventriculares suprahisianos. Mostramos nuestra experiencia en bloqueos infrahisianos.

Métodos. Seleccionamos a pacientes derivados por síncope y trastornos de la conducción intraventricular, bloqueo auriculoventricular completo y con asincronía intraventricular izquierda con seno coronario no accesible. En todos se practicó un estudio electrofisiológico en el que se evaluó la conducción infrahisiana basal y tras la administración de flecainida. Entre los pacientes con indicación de marcapasos permanente se seleccionó a aquellos en los que la estimulación del haz de His provocaba un complejo QRS estrecho. Implantamos electrodos en la aurícula derecha, el haz de His y el ápex de ventrículo derecho, conectándolos a las salidas auricular, ventricular izquierda y ventricular derecha de un marcapasos biventricular. Se programaron en modo DDD con un intervalo ventrículo izquierdo-ventrículo derecho de 80 ms.

Resultados. Desde febrero hasta diciembre de 2004 se estudió a 10 pacientes, de los que 7 cumplieron criterios de inclusión; en 5 pudo implantarse un electrodo hisiano. El umbral de estimulación hisiana permaneció estable en 2 y mostró incrementos en 3. Durante el seguimiento de 2 a 12 meses no se han observado dislocamientos o pérdidas de captura. Ecocardiográficamente no ha habido deterioro de la función ventricular ni incompetencias valvulares, y la asincronía intraventricular mejoró en el caso de que estuviera presente.

Conclusiones. La estimulación hisiana constituye el único modo de provocar una contracción ventricular más fisiológica y su utilización es posible en algunos casos de bloqueo infrahisiano.

Palabras clave: Bloqueo de rama. Estimulación en el haz de His. Bloqueo auriculoventricular. Estimulación cardiaca.

SEE EDITORIAL ON PAGES 534-6

Correspondence: Dr. R. Barba Pichardo.
A. Sundheim, 30, 1.º C. 21003 Huelva. España.
E-mail: rbphuelva@yahoo.es

Received March 21, 2005.

Accepted for publication March 9, 2006.

ABBREVIATIONS

AVB: atrioventricular block.
 CBBB: complete bundle-branch block.
 CRBBB: complete right bundle-branch block.
 CLBBB: complete left bundle-branch block.
 EPS: electrophysiology study.
 H: His-bundle electrogram.

TABLE. Conduction Disturbances in Patients Selected for His-Bundle Pacing*

CRBBB	3
CRBBB with first-grade AV block	1
CLBBB	2
Complete infra-Hisian AVB	1

*AV indicates atrioventricular; AVB, atrioventricular block; CRBBB, complete right bundle-branch block; CLBBB, complete left bundle-branch block.

INTRODUCTION

Permanent His-bundle pacing is both effective and safe in patients with supra-Hisian atrioventricular block and can improve ventricular functioning.^{1,2} It is logical to believe, however, that the technique is only appropriate in patients with supra-Hisian atrioventricular block, and that it would be contraindicated in patients with infra-Hisian atrioventricular block.

However, in electrophysiological studies (EPS) we found that His-bundle pacing with a temporary lead led to the disappearance of complete bundle-branch block (CBBB) in some cases (Figure 1). We therefore decided to attempt definitive His-bundle pacing in selected patients with infra-Hisian conduction disturbances.

METHODS

Patient Selection

Between February and December 2004, we included 7 patients with electrocardiographic (ECG) evidence of intraventricular conduction disturbance and EPS

results indicating disturbed infra-Hisian conduction. His-bundle stimulation during EPS in these patients had produced a normal or "fused" QRS complex (Figure 2). Six of the patients proposed for the intervention had been referred for EPS because of syncope. The seventh patient had heart failure due to dilated cardiomyopathy as well as complete left bundle-branch block (CLBBB) and an indication for resynchronization, which was not possible via the coronary sinus. In this patient, the EPS had shown His-bundle block (H 54 ms) which was corrected by His-bundle pacing (Figure 3).

Patients ranged from 63 to 82 years of age. There were 4 women and 3 men. The table shows the type of electrocardiographic disturbances presented by the patients.

Pacemaker Implantation

The 7 patients, 4 of whom had CRBBB (1 with added first grade supra-Hisian atrioventricular block), 2 with CLBBB, and 1 with complete infra-Hisian AVB were proposed for definitive His-bundle pacing using a

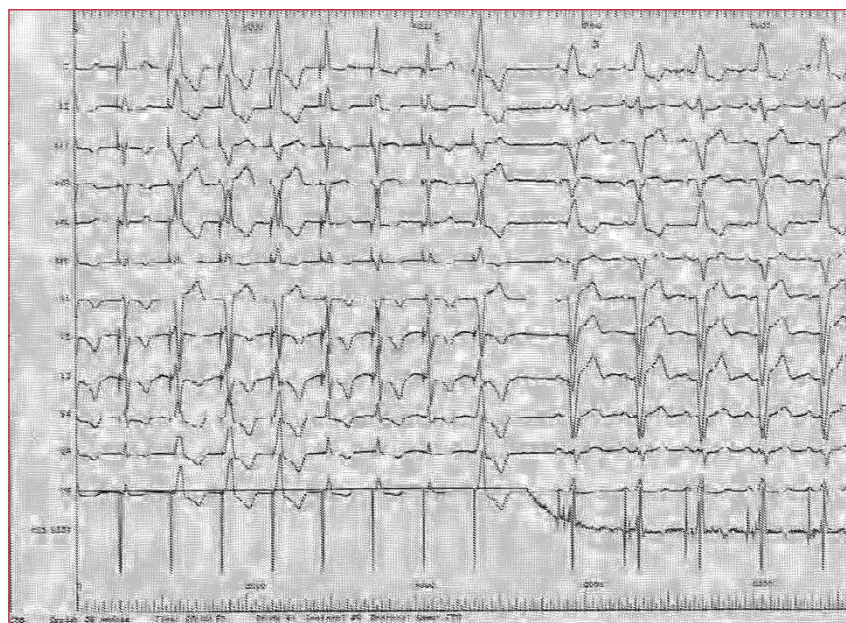


Figure 1. Stimulation via a lead located in the His-bundle (HIS DIST) in a patient with complete left bundle-branch block (CLBBB). In the first 8 complexes, various morphologies of the stimulated QRS are produced, but those marked 1 and 2 show complete disappearance of the bundle-branch block, with spike-QRS latency, due to pure Hisian capture. From 3 onwards, His-bundle pacing is stopped and the baseline CLBBB reappears.

Figure 2. Electrocardiogram of a tetrapolar lead (proximal and distal His reference) and definitive pacing lead (His-bundle pacemaker). The existence of a complete infra-Hisian atrioventricular block can be observed. The final 2 QRS complexes are “stimulated” in the His-bundle via the pacemaker lead, leading to normalized QRS morphology and duration. A indicates auriculogram; H, His-bundle electrogram.

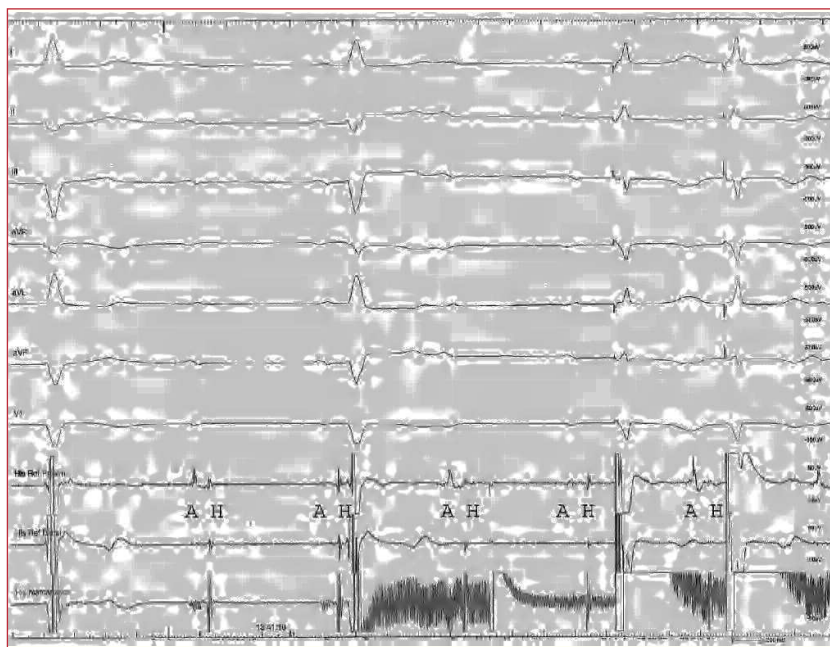
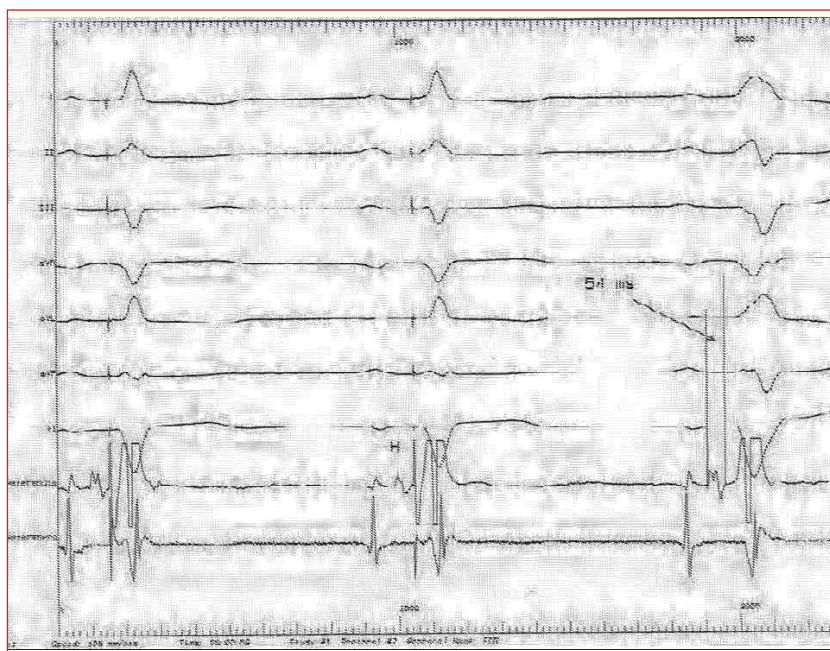


Figure 3. DDD pacemaker with Hisian stimulation. In the first 2 QRS, capture of the His-bundle normalizes the QRS and leads to spike-QRS latency. In the third QRS, the pacemaker was switched off and a complete left bundle-branch block (CLBBB) appears with His-bundle block. The His-bundle electrogram shows the proximal depolarization of the His-bundle. Stimulation was produced distal to the site of the block, which was not refractory as it had not been depolarized, even through the right branch (according to the phenomenon of anisotropy between the two branches). H indicates His-bundle electrogram.



biventricular DDD pacemaker. Previous His-bundle pacing had led to the disappearance of the conduction disturbance in all of the patients.

The technique used for pacemaker implantation has been described elsewhere,² and consists of introducing a tetrapolar lead using fluoroscopy via the femoral vein until activity is registered in the His-bundle (the reference zone). The lead is advanced and the reference zone “mapped” while attempts are made to register activity in the His-bundle; when this is achieved, contact is maintained between the lead and the septum and the fixation helix is removed. Stability

and thresholds are then tested (maximum accepted 2.5 V for 0.4 ms). We used 52 cm, active fixation Tendril SDX, St Jude leads (St Jude, Minneapolis). With this lead, the mechanism used to extract the fixation helix prior to implant leaves several centimeters of guideline uncovered, which are useful for manipulating and stabilizing the lead.

Leads were implanted in the right atrium, in the bundle of His, and, for safety, at the apex of the right ventricle (Figure 4), and connected to the atrial, left ventricular, and right ventricular terminals, respectively, of a biventricular pacemaker generator.

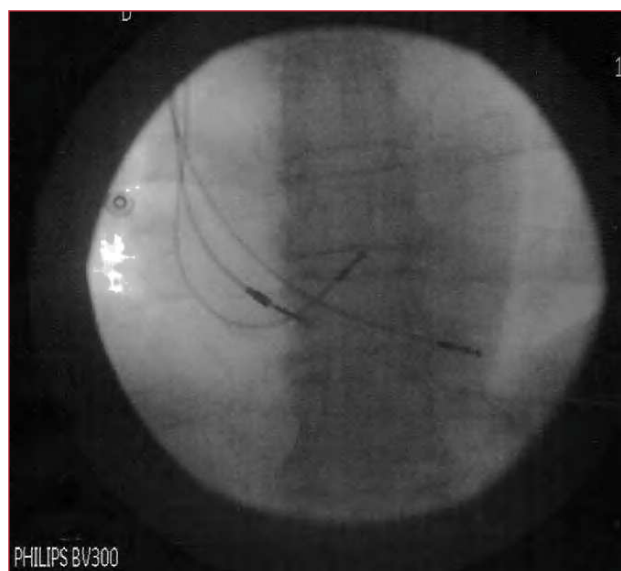

Figure 4. Radiological image of 3 definitive leads placed in the lower interatrial septum, His-bundle, and the right ventricular apex.

By programing an appropriate advance in the left ventricular pacing, it is possible to stimulate the “Hisian zone” exclusively and the right ventricular spike locates on the refractory QRS complex with no opportunity for originating local capture (Figure 5). When the Guidant Contak Renewal TR2CRT-P pacemaker was used (on 3 occasions), the sensitivity of the left ventricular channel was adjusted to be as “blind” as possible to avoid inhibiting stimulation of

the His-bundle because of possible A wave sensing. In another 2 cases, and again to avoid this effect, we used devices in which left ventricular channel sensing was not possible, such as the Medtronic Insync III.

RESULTS

Effects of His-Bundle Pacing

Selective His-bundle pacing using high output voltages (over 2.5 V) in the 2 patients with CRBBB led to the disappearance of the bundle-block and reduced the duration of the QRS complex (Figure 6), which acquired a “pre-excited” aspect. Using low output voltages led to a reappearance of CRBBB with spike-QRS latency and a failure to normalize QRS morphology and duration.

In 2 patients with CLBBB, His-bundle pacing led to the disappearance of the bundle-block and practically normalized QRS duration and morphology. This was the case of the patient with dilated cardiomyopathy (Figure 7).

In the patient with complete infra-Hisian AVB, His-bundle pacing corrected the disturbance and normalized the QRS (Figure 2).

The His-bundle lead was successfully implanted in 5 (71%) of the 7 patients initially selected for the procedure (2 with CRBBB, 1 of whom had first-grade AVB, 2 with CLBBB, and 1 with complete infra-Hisian AVB). Acute His-bundle pacing thresholds were between 1.2 and 2.3 V with a duration of 0.4 ms.

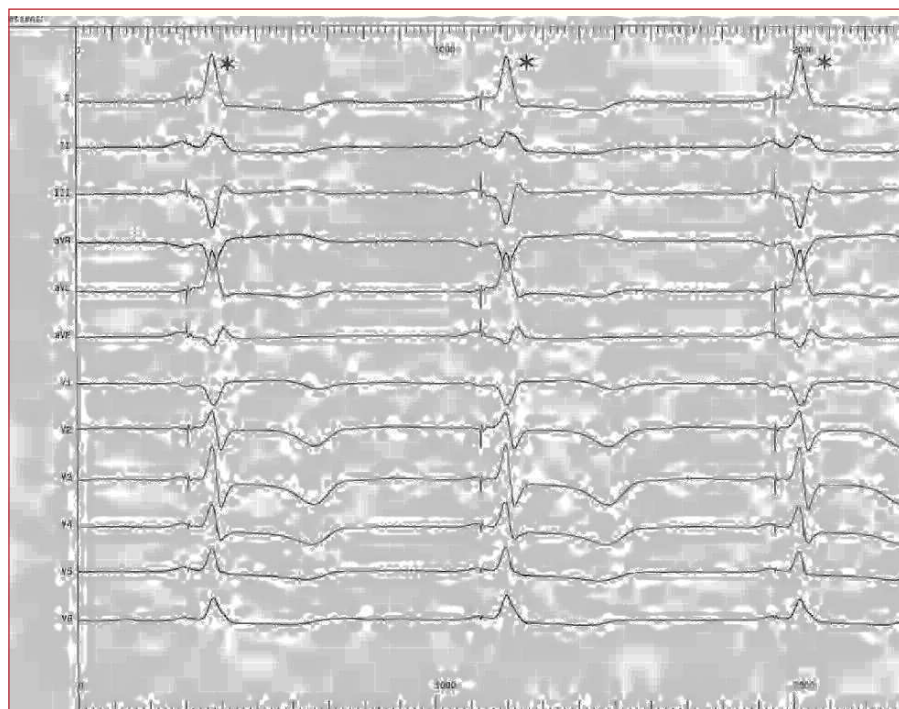


Figure 5. Electrocardiogram of a DDD pacemaker and His-bundle pacing. The asterisk in the descending part of the QRS indicates the back-up pacing in the right ventricle.

Figure 6. A: electrocardiogram with sinus rhythm and 250 ms PR interval showing a complete right bundle-branch block (CRBBB). B: the same electrocardiogram as in A with DDD pacemaker and sequential stimulation in the atrium and His-bundle; the first 2 QRS show His capture and capture of adjacent myocardium, a “fusion” which eliminates the CRBBB, narrows the QRS, and resynchronizes the right ventricle; the last 2 QRS show “pure” Hisian capture, with correction of the atrioventricular block and appearance of CRBBB. C: the same electrocardiogram as in B. The first 2 QRS show His-bundle capture; in the later QRS, His-bundle capture is lost (note the increase of latency in the His spike) and atrioventricular block reappears, with persistence of CRBBB.

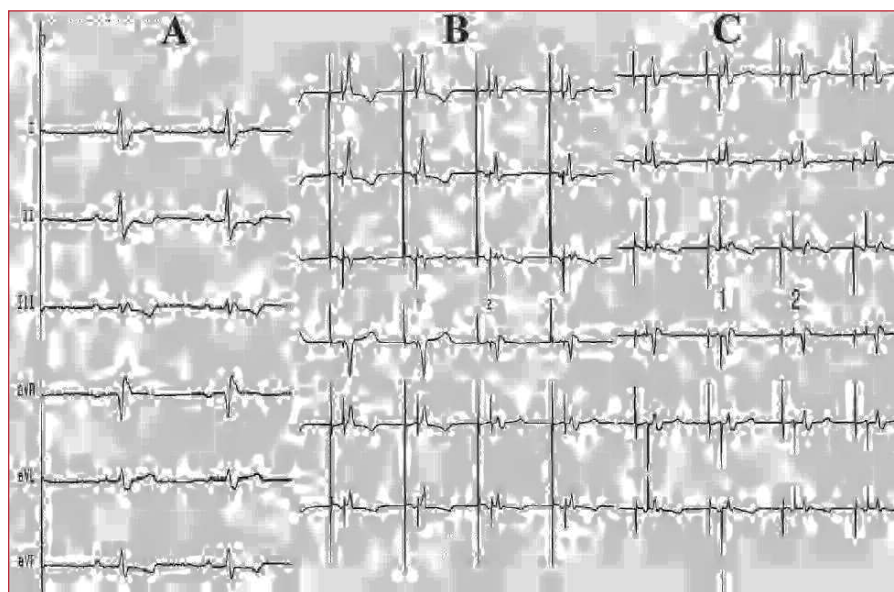



Figure 7. Electrocardiogram showing complete left bundle-branch block (CLBBB). DDD pacemaker activated from the fifth QRS on, with His-bundle pacing leading to a normalized QRS complex and disappearance of the CLBBB.



Fixation of the His-bundle lead required between 12 and 47 mins.

Follow-Up

Between 2 and 12 months follow-up, no lead dislodgement was observed, though the His-bundle pacing threshold increased in three patients to 4, 4.5 and 4.5 V for 0.4 ms at 7, 8 and 10 months, respectively. No problems arose because of oversensing.

The echo-Doppler readings did not deviate significantly from pre-implant values, except in the

patient with dilated cardiomyopathy and CLBBB, in which pre-implant left ventricular dyssynchrony was normalized. There was no evidence of AV valvular incompetence.

DISCUSSION

It has been known for some time³ that selective His-bundle pacing can lead to the disappearance of CBBB. This can be explained by longitudinal dissociation in the His-bundle, a theory based on the anatomical and histological studies of James and Sherf⁴ which sustains that the fibers going to for the right and left branches

of the conduction system are organized longitudinally and separated in the His trunk. This makes cross-excitation between the right and left bundles (anisotropy) difficult. A lesion which only affects part of the His trunk can therefore cause electrocardiographic disturbances typical of CBBBs. This has been confirmed by other authors⁵⁻⁹ and explains why His-bundle pacing in a zone distal to the site of the block and a Hisian extrasystole originating in that region can lead to the disappearance of CBBB.¹⁰

The fact that His-bundle pacing does not always lead to an absolutely normalized QRS complex with clear latency between the spike and the start of the QRS (His-Purkinje conduction time), can be explained by the simultaneous capture of myocardium next to the His-bundle, so that 2 depolarizing fronts are produced. One of these captures the His-bundle and activates the left ventricle via the left branch, while the other captures myocardium in the Hisian region and depolarizes and resynchronizes the right ventricle (Figure 6). The QRS complex obtained is therefore a fusion of the 2 activation fronts, and is similar to that seen in anteroseptal pre-excitation syndromes.

The fact that this did not disappear in any of the CRBBB patients in which the QRS complex was completely normalized, together with the spike-QRS to His-bundle pacing latency, can be explained by the location of the block in a peripheral region of the right branch, distal from the His-bundle.¹¹

In patients with CLBBB, His-bundle pacing produces an almost normal QRS complex, although the short spike-QRS latency indicates some degree of adjacent myocardial capture (fusion). The disappearance of the CRBBB indicates that it is located in the His-bundle (it is impossible to "eliminate" a CLBBB by stimulating sites in the right ventricle) and that stimulation is distal to the site of the blockage (Figure 3), which remains refractory.

In patients with complete infra-Hisian atrioventricular block, the fact that His-bundle pacing produces an almost normal QRS, with minimal latency, can be explained by the mechanism described above. It also shows that the His-bundle block is proximal, and that capture occurs distally to that zone, which is free of refractoriness (Figure 2).

In the patient with dilated cardiomyopathy and CLBBB, evidence for intraventricular resynchronization produced by His-bundle pacing is provided by a return to normal echo-Doppler electromechanical patterns.

We do not know whether the increase in His-bundle pacing threshold over time is due to microdislodgement, fibrosis, or some other mechanism.

CONCLUSIONS

Permanent His-bundle pacing is possible in the majority (71%) of cases with infra-Hisian atrioventricular block and can be attempted when prior stimulation of the His-bundle leads to disappearance of the conduction disturbance (63% of the present series).

We believe that it is worth persevering this pacing site, despite the potential drawbacks, if it means this will pursue myocardial contraction which mimics a physiological contraction. A lack of knowledge regarding the progression of the conduction disturbance, lead stability, and the evolution of pacing thresholds means that, for the time being, it is necessary to ensure ventricular capture using a back-up lead in the right ventricle.

The theory of longitudinal dissociation in the His-bundle is confirmed and explains the findings that we describe.

REFERENCES

1. Deshmukh P, Casavant DA, Romanyshyn M, Anderson K. Permanent, direct His-bundle pacing. A novel approach to cardiac pacing in patients with normal His-Purkinje activation. *Circulation*. 2000;101:869-77.
2. Moriña Vázquez P, Barba Pichardo R, Venegas Gamero J, Álvarez Saiz A, Moreno Lozano V, Fernández Gómez JM, et al. Estimulación permanente del haz de His tras ablación mediante radiofrecuencia del nodo auriculoventricular en pacientes con trastorno de la conducción suprahisiano. *Rev Esp Cardiol*. 2001;54:1385-93.
3. el-Sherif N, Amat Y, León F, Schonfield C, Scherlag BJ, Rosen K, et al. Normalization of bundle branch patterns by distal His bundle pacing. Clinical and experimental evidence of longitudinal dissociation in the pathologic His bundle. *Circulation*. 1978;57:472-83.
4. James TN, Sherf L. Fine structure of the His bundle. *Circulation*. 1971;44:9-28.
5. Narula OS. Longitudinal dissociation in the His bundle; Bundle branch block due to asynchronous conduction within the His bundle in man. *Circulation*. 1977;56:996-1006.
6. Han J, Fabregas RA. Can His bundle lesions produce the electrocardiographic pattern of bundle branch block? *J Electrocardiol*. 1977;10:205-6.
7. Narula OS. The manifestation of bundle branch block due to lesion within his bundle. A dilemma in electrocardiographic interpretations. *Chest*. 1978;78:312-4.
8. Alboni P, Pedroni P, Malacarne C, Masoni A. The bundle branch block anatomically located in His Bundle. *G Ital Cardiol*. 1980;10:1583-7.
9. Sánchez-Quintana D, Yen Ho S. Anatomía de los nodos cardiacos y del sistema de conducción específico auriculoventricular. *Rev Esp Cardiol*. 2003;56:1085-92.
10. Almanza Ceballos A, Molinero Somolinos F, Rubio Sanz R, Desroches W. Longitudinal dissociation in the His bundle of His and infra-His block. *Arch Inst Cardiol Mex*. 1982;52:483-6.
11. Horowitz LN, Alexander JA, Edmunds Jr. Postoperative right bundle branch block: identification of three levels of block. *Circulation*. 1980;62:319-2.