

Recurrent Ventricular Fibrillation in a Patient With Brugada Syndrome Successfully Treated With Procainamide

Rosa M. Sánchez-Aquino, Rafael Peinado, Ana Peinado, José L. Merino, and José A. Sobrino

Unidad de Arritmias, Unidad Médico-Quirúrgica de Cardiología, Hospital Universitario La Paz, Madrid, Spain.

Brugada syndrome is a clinical and electrocardiographic entity characterized by ST segment elevation in the right precordial ECG leads and sudden death or syncope secondary to malignant ventricular arrhythmia, and has a high recurrence rate. We report a patient with this syndrome who had received an automatic implantable defibrillator, who presented with multiple appropriate discharges because of recurrent episodes of ventricular fibrillation. All episodes were started by a premature ventricular beat of the same morphology and coupling interval. Endovenous procainamide administration, paradoxically, was effective in preventing new episodes. The beneficial antiarrhythmic effect of procainamide in this patient is discussed.

Key words: *Brugada syndrome. Ventricular fibrillation. Drugs.*

Full English text available at: www.revvespcardiologia.org

INTRODUCTION

Brugada syndrome is a clinical and electrocardiographic entity characterized by a typical ECG pattern and syncope or sudden death.¹ The condition involves malignant ventricular arrhythmia, polymorphic ventricular tachycardia and ventricular fibrillation and has a high recurrence rate.² The episodes usually present alone, but occasionally appear as multiple episodes of arrhythmia. At present there is little information on the origin and treatment of this condition, although several potential triggering factors have been suggested

Fibrilación ventricular recurrente en un paciente con síndrome de Brugada: tratamiento eficaz con procainamida

El síndrome de Brugada es una entidad clínica electrocardiográfica caracterizada por la elevación del segmento ST en derivaciones precordiales derechas del electrocardiograma (ECG) y por síncope y muerte súbita, originados por episodios de arritmias ventriculares malignas, con una alta probabilidad de recurrencia. Presentamos el caso de un paciente con este síndrome, portador de un desfibrilador automático, que tuvo descargas múltiples por episodios de fibrilación ventricular recurrente. Todos ellos comenzaban con una extrasístole ventricular de igual morfología y acoplamiento. La administración de procainamida intravenosa, paradójicamente, resultó efectiva. Se discute el efecto antiarrítmico beneficioso de dicho fármaco en este caso.

Palabras clave: *Síndrome de Brugada. Fibrilación ventricular. Fármacos.*

recently.³ We describe a patient with this syndrome who had received an implantable cardioverter defibrillator (ICD) and presented arrhythmia with multiple appropriate discharges secondary to episodes of recurrent ventricular fibrillation.

CASE STUDY

A 54-year-old man was seen in April 1996 after aborted sudden death secondary to ventricular fibrillation. The patient had no personal or family history of interest and the physical examination was normal. The electrocardiogram revealed the characteristic pattern of Brugada syndrome (Figure 1). The echocardiogram and cardiac catheterization studies were normal. Electrophysiological study showed an HV interval of 60 ms, and ventricular fibrillation was induced by a drive train followed by two ventricular extrastimuli,

Correspondence: Dr. Rafael Peinado Peinado.
Unidad de Arritmias. UMQ de Cardiología. Hospital Universitario La Paz.
Paseo de la Castellana, 261. 28046 Madrid. España.
E-mail: rpeinado@secardiologia.es

Received 13 March 2003.
Accepted for publication 17 June 2003.

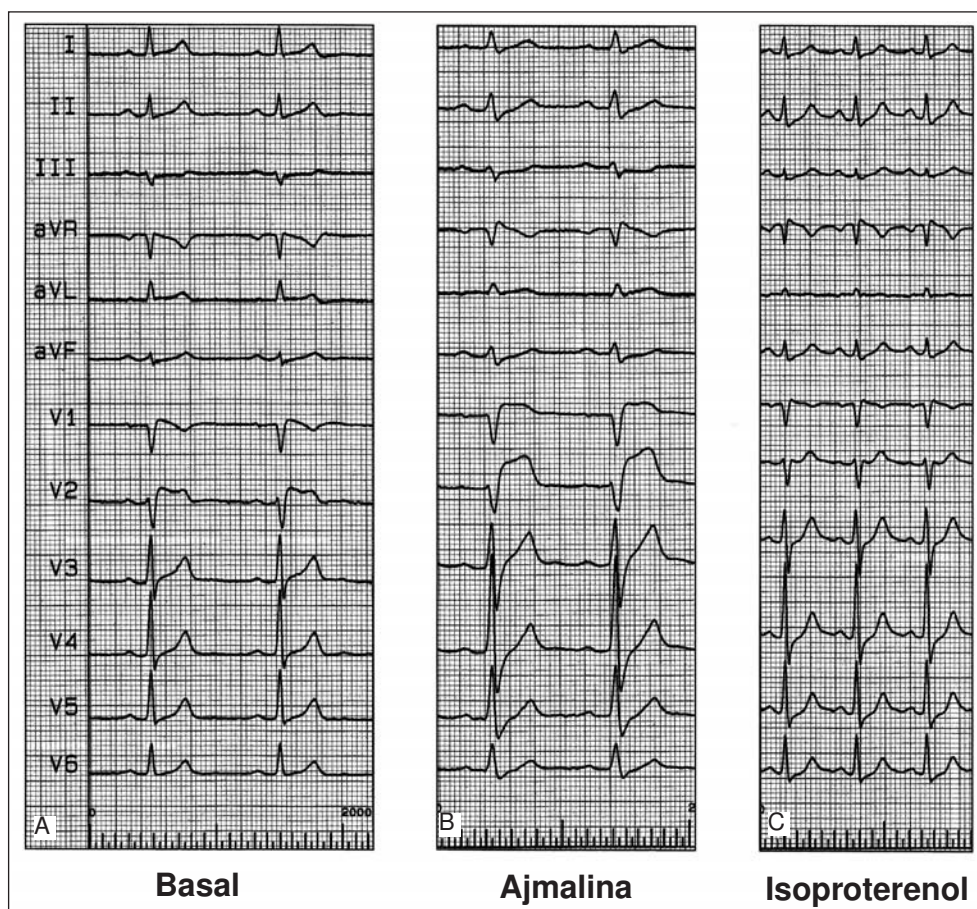


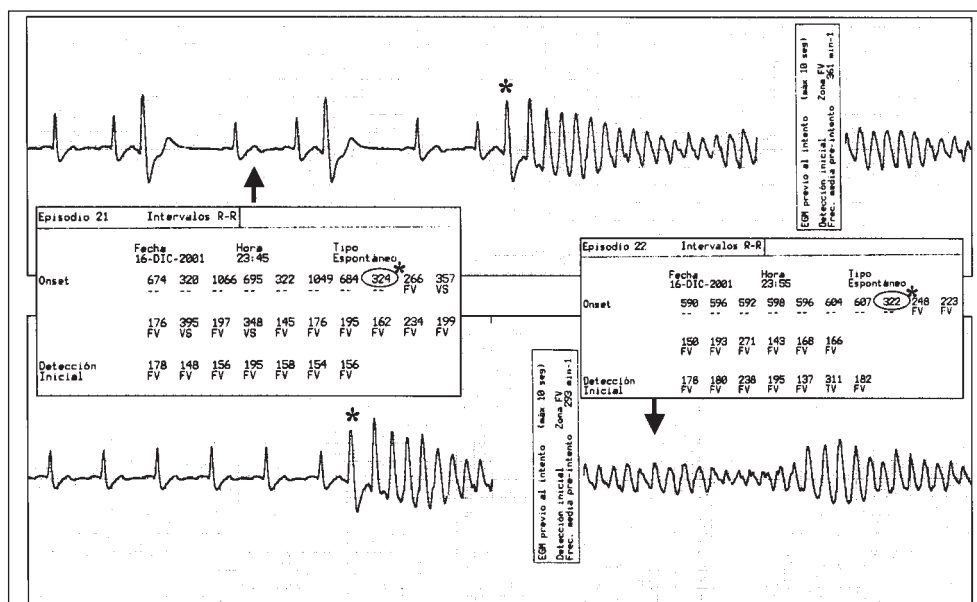
Fig. 1. Fig. 1. 12-lead electrocardiogram under baseline conditions (A) and after ajmaline (B) and isoproterenol (C).

with coupling of 600/250-180 ms from the apex of the right ventricle. The administration of 20 mg of ajmaline produced marked elevation of the J point and ST segment, which normalized with isoproterenol admini-

stration (Figure 1). A single-chamber implantable cardioverter defibrillator was implanted.

On two occasions (August 1998 and November 2001), the patient presented at the emergency room

Fig. 2. Intracardiac electrograms recorded by the implantable cardioverter defibrillator in two of the ventricular fibrillation episodes and text of the episodes with RR interval measurements in ms. Both disclose a premature ventricular beat of the same morphology and coupling (*) with respect to the preceding sinus beat that initiated ventricular fibrillation. The first episode shows two preceding premature beats of the same morphology and similar coupling that did not initiate ventricular fibrillation.



with sudden, recurrent syncopal episodes occurring at rest with no apparent triggering factor, followed by discharge of the implantable cardioverter defibrillator. Both times, the patient had additional episodes shortly after admission and ECG monitoring indicated ventricular fibrillation. Also on both occasions, the patient was given 1 g of intravenous procainamide in 30 min, followed by maintenance infusion of 20 mg/min, with no further arrhythmias. On the first occasion quinidine was prescribed at a dose of 560 mg/day, which the patient decided to discontinue.

In both incidents, interrogation of the implantable cardioverter defibrillator showed six and seven episodes, respectively, of ventricular fibrillation which were terminated by discharge. All episodes started with a premature ventricular beat of the same morphology and similar coupling as the preceding sinus beat (Figure 2). After his second hospital stay, the patient has continued quinidine therapy at the prescribed dosage with no new recurrences of ventricular fibrillation after one year of follow-up.

DISCUSSION

The frequency of Brugada syndrome has not been estimated, although a number of cases have been reported in the literature.^{3,4} There is little information about arrhythmias in patients with this condition. Although several potential triggering factors such as autonomic tone, temperature³ or the use of antiarrhythmic drugs have been suggested, none were found in our patient.

Treatment has not been established as yet, although isoproterenol has been reported to be effective.⁴ This drug was used in our patient because its therapeutic usefulness was not known at the time of the first episode (1998) and because the patient responded well to procainamide administration in the second (2001).

In view of the underlying abnormality of this disorder, it is paradoxical that procainamide was successful in our patient. Although the therapeutic benefit of quinidine at low doses caused by blockade of the tran-

sient outward potassium current (Ito) has been suggested, this effect has not been shown in the case of procainamide. Nevertheless, chronic administration of oral procainamide was not used to prevent recurrence, because of the high incidence of medium- and long-term adverse effects associated with this type of regimen.

We observed that all documented episodes in our patient started with a premature ventricular beat of the same morphology and similar coupling in the morphology channel of the implantable cardioverter defibrillator. The role of premature ventricular beats in triggering ventricular fibrillation, as well as its treatment with catheter ablation, have recently been reported.^{5,6} We attribute the success of procainamide in our patient to suppression of the premature beats, rather than to an effect on the actual mechanism of the syndrome.

REFERENCES

1. Brugada P, Brugada J. Right bundle branch block, persistent ST segment elevation and sudden cardiac death: a distinct clinical and electrocardiographic syndrome. A multicenter report. *J Am Coll Cardiol* 1992;20:1391-6.
2. Brugada J, Brugada R, Antzelevitch C, Towbin J, Nademanee K, Brugada P. Long-term follow-up of individuals with the electrocardiographic pattern of right bundle-branch block and ST-segment elevation in precordial leads V1 to V3. *Circulation* 2002;105:73-8.
3. González Rebollo JM, Hernández Madrid A, García A, García de Castro A, Mejías A, Moro C. Recurrent ventricular fibrillation during a febrile illness in a patient with the Brugada syndrome. *Rev Esp Cardiol* 2000;53:755-7.
4. Tanaka H, Kinoshita O, Uchikawa S, Kasai H, Nakamura M, Izawa A, et al. Successful prevention of recurrent ventricular fibrillation by intravenous isoproterenol in a patient with Brugada syndrome. *Pacing Clin Electrophysiol* 2001;24:1293-4.
5. Kakishita M, Kurita T, Matsuo K, Taguchi A, Suyama K, Shimizu W, et al. Mode of onset of ventricular fibrillation in patients with Brugada syndrome detected by implantable cardioverter defibrillator therapy. *J Am Coll Cardiol* 2000;36:1646-53.
6. Haissaguerre M, Shoda M, Jais P, Nogami A, Shah DC, Kautzner J, et al. Mapping and ablation of idiopathic ventricular fibrillation. *Circulation* 2002;106:962-7.