

## ECG Contest

## Response to ECG, June 2016



## Respuesta al ECG de junio de 2016

José Ángel Rodríguez-Fernández

Servicio de Cardiología, Hospital Universitario de A Coruña, A Coruña, Spain

After electrical cardioversion, the presence of atrial flutter with a conduction ratio of 4:1 was observed (Figure 1). The flutter (F) waves are seen in the ECG rhythm strip to be dissociated from the QRS complexes. A subsequent electrophysiological study confirmed the presence of typical atrial flutter, and a sustained monomorphic ventricular tachycardia with the same morphology as that shown in the original ECG was induced (Figure 2). Both arrhythmias were successfully treated by radiofrequency ablation of the cavotricuspid isthmus, following left ventricular mapping.

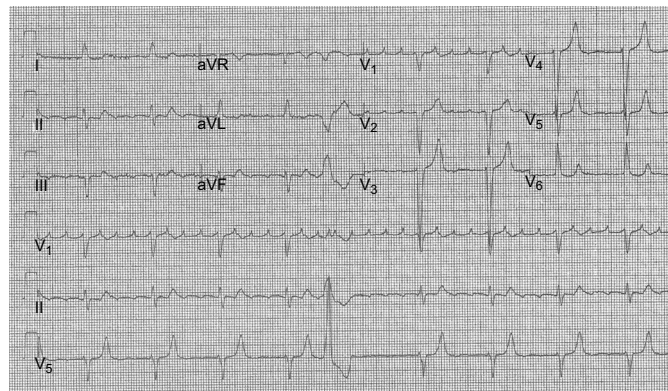


Figure 1.

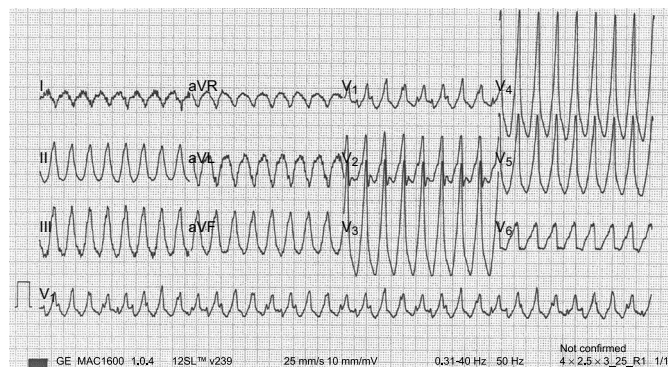


Figure 2.

SEE RELATED ARTICLE:

<http://dx.doi.org/10.1016/j.rec.2016.01.028>

E-mail address: [jose.a.rodriquez.fernandez@sergas.es](mailto:jose.a.rodriquez.fernandez@sergas.es)

<http://dx.doi.org/10.1016/j.rec.2016.01.029>

1885-5857/© 2016 Sociedad Española de Cardiología. Published by Elsevier España, S.L.U. All rights reserved.