

Septal Ablation in Hypertrophic Cardiomyopathy: Current Status

Hubert Seggewiss^a and Angelos Rigopoulos^b

^aMedizinische Klinik 1, Leopoldina-Krankenhaus, Schweinfurt, Germany.

^bDepartment of Cardiology, University of Athens, Athens, Greece.

INTRODUCTION

Symptomatic patients with hypertrophic obstructive cardiomyopathy (HOCM) are treated to reduce symptoms, improve functional capacity and provide better quality of life.^{1,2} Therefore, the extent of the outflow tract gradient and diastolic filling must be improved. Medical therapy, with the administration of negative inotropic drugs such as beta-blockers,³⁻⁵ verapamil^{4,6} or disopyramide,^{7,8} is always the first line of treatment. A large number of patients with marked outflow tract obstruction have severe symptoms which are unresponsive to medical therapy.⁹ In this group, surgical myectomy/myotomy has been the mainstay for decades, providing long-term symptomatic relief in a substantial proportion of patients. The high early postoperative mortality could be reduced to <1%-2% in highly experienced centers.¹⁰⁻¹³ DDD-pacemaker implantation has not proved to be as efficacious in randomized trials, with most of the reported reduction of symptoms being due to a substantial placebo effect.¹⁴⁻¹⁶

Percutaneous transluminal septal myocardial ablation (PTSMA) through alcohol-induced occlusion of a septal branch aims to directly reduce the hypertrophied interventricular septum with subsequent expansion of the left ventricular outflow tract and reduction of the left ventricular outflow tract gradient.¹⁷ This is achieved through a circumscribed

infarction of the area supplied by the occluded septal branch. In this report we give an update on this novel treatment.

TECHNICAL ASPECTS

After initial studies had shown that temporary balloon occlusion of the first large septal branch resulted in a substantial reduction in resting outflow gradient in a minority of patients,^{18,19} Sigwart was the first to report successful non-surgical myocardial reduction after occlusion of the septal branch with 96% alcohol.¹⁸

The original technique of PTSMA has undergone several modifications to date, with the aim of improving the identification of the target septal perforator branch, in order to achieve optimal hemodynamic results with fewer complications.^{18,20,21} Nearly all operators agree that a temporary pacemaker should be placed in the right ventricle because of the risk of trifascicular block during PTSMA. Currently, echocardiography-guided ablation¹⁷ is performed by most active PTSMA groups. We will briefly discuss the advantages of this technique. Echocardiographic monitoring of the procedure was introduced^{21,22} in order to identify the target septal branch and to exclude unintentional alcohol injection to the wrong area, e.g., the papillary muscle or left ventricular free wall (Figure 1). The authors have chosen Levovist® instead of other echo-contrast media, due to its superior visibility during the procedure. Finally, it must be emphasized that hemodynamic and rhythm monitoring in the coronary care unit is required for at least 24 to 48 hours.

Correspondence: Dr. H. Seggewiss.
Medizinische Klinik 1, Leopoldina-Krankenhaus.
Gustav-Adolf-Str. 8. 97422 Schweinfurt, Germany.
E-mail: hseggewiss@leopoldina.de

Full English text available at: www.revespcardiol.org

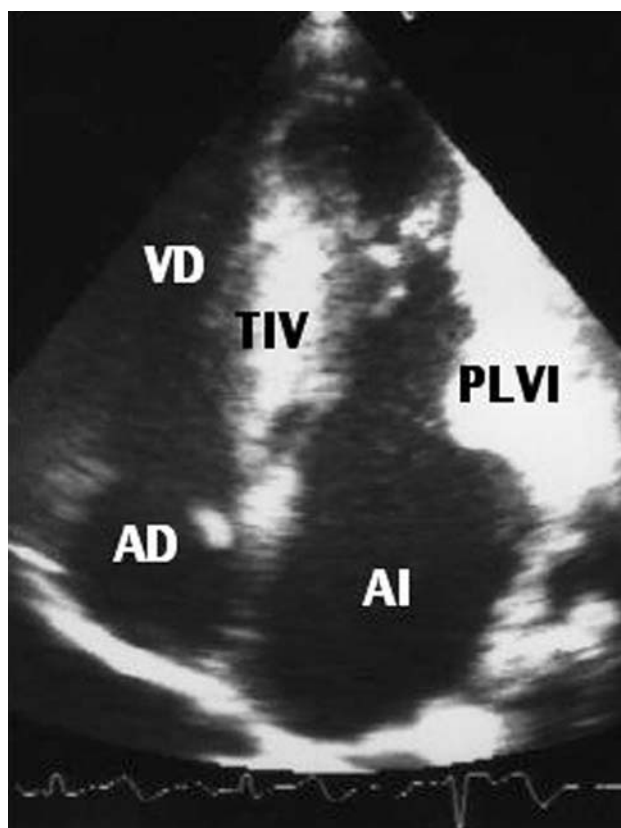


Fig. 1. Apical 4-chamber view with echo-contrast opacification of the intraventricular septum (IVS), and left ventricular free wall (LVFW). RV indicates right ventricle; RA, right atrium; LA, left atrium.

INDICATIONS AND CONTRAINDICATIONS

The clinical indications for PTSMA are symptomatic patients \geq NYHA III/CCS III despite optimal drug therapy or with severe side effects from medication. The patients should have high outflow tract gradients (≥ 50 mm Hg at rest or ≥ 100 mm Hg under stress). In individual patients with less severe symptoms, active treatment can be considered if they have high gradients and additional findings, such as recurrent exercise-induced syncope, abnormal blood pressure response on exercise, paroxysmal atrial fibrillation or an objective reduction in exercise capacity. These considerations are supported by current data that have shown a correlation between hypertrophic cardiomyopathy-related death as well as progressive heart failure and a resting gradient of more than 30 mm Hg.^{23,24} The morphological indications for echocardiography-guided septal ablation are subaortic as well as mid-cavitary obstruction, previous hemodynamically unsuccessful surgical myectomy, or DDD-pacemaker implantation. Patients with concomitant car-

diac diseases indicating surgery, e.g., extensive coronary artery disease, valvular disease, and anatomical changes in the mitral valve or the papillary muscles that cause an outflow tract gradient or mitral regurgitation, should not be treated with PTSMA. It must be noted, however, that in individual patients with single vessel disease amenable to dilatation and stenting, combined percutaneous treatment (percutaneous transluminal coronary angioplasty and PTSMA) has been performed.²⁵

Finally, alcohol should not be injected when myocardial contrast echocardiography fails to identify a target septal branch, or reveals opacification of any cardiac structure other than the target septal area, or when balloon positioning bears the risk of alcohol reflux during injection.

RESULTS

All operators report an acute reduction in left ventricular outflow tract gradient in about 90% of the patients treated.^{17,18,20,21,26-34} Younger patients had smaller reductions in the gradient than older patients,³⁵ probably because of greater septal thickness and additional structural deformities such as abnormal papillary muscles. Nevertheless, about 50% of the young patients with inadequate acute results show improved gradient reduction at follow-up, due to post-infarction remodeling and shrinkage of the ablated area of the septum. Patients in functional class IV showed acute results similar to those in less symptomatic patients.³⁶ In patients with a PTSMA scar that appears too small, the outcome of the remodeling process, which can take up to 12 months, should be awaited. Pre-interventional non-invasive estimation of the underlying histological substrate (fibrosis or muscle) and elongation of the mitral leaflet will probably be helpful in the future to exclude patients from PTSMA, in order to optimize hemodynamic success. Several studies have reported that echo-guidance with myocardial contrast echocardiography (MCE) had a crucial impact on the selection of the ablated area in about a quarter of the patients.¹⁷ Echo-contrast helped to identify an atypical origin in the septal branch as the target vessel, or to avoid injecting alcohol into the wrong site by changing the vessel when echo-contrast opacification had identified the wrong septal areas or other cardiac structures, such as papillary muscles or ventricular free walls. Our findings were confirmed in an autopsy study by Singh et al.³⁷ Furthermore,

TABLE 1. Acute results of PTSMA

Author	Patients (n)	Success without complication (%)	Death (%)	Pacemaker (%)	Comments
Seggewiss et al ²⁰	25	88	4.0	20	No echo-monitoring
Faber et al ²¹	91	97%	2.2	11	Improvement of results by echo-monitoring
Gietzen et al ³¹	50	NR	4.0	NR	12 re-interventions; no echo-monitoring
Nagueh et al ³⁰	29	NR	0	10 (34%)	4 patients with gradients only at dobutamine infusion
Knight et al ²⁶	18	89	0	5*	1 patient alcohol leakage down the LAD
Kornacewicz-Jach et al ²⁹	9	100	0	22	Echo-monitoring
Kuhn et al ⁵²	172	NR	2.3	NR	No echo-monitoring
Seggewiss ¹⁷	290	90	1.0	5.5	DDD-pacemaker with echo-monitoring 4.2%
Boekstegers et al ⁴³	50	NR	0	10	No echo-monitoring; 2 septal branches in 6 patients
Gietzen et al ⁵¹	129	NR	3.1	26	No echo-monitoring; similar results in patients with and without resting obstruction
Schweinfurt (Seggewiss et al 5/00-4/02)	150	92	0.7	1.3	Echo-monitoring

LV indicates left ventricle; LAD, left anterior descending artery; NR, not reported.

*6 patients with pacemaker implantation before PTSMA.

echocardiographic monitoring also permitted the interventional treatment of combined subaortic and mid-ventricular obstruction, as well as a pronounced mid-ventricular obstruction following the reduction of its afterload after successful subaortic myectomy.³⁸

In-hospital death is the most feared complication observed to date, with a rate of up to 4%.³¹ In our own experience with PTSMA in >600 patients, hospital mortality has been less than 1.0%, which is similar to the results from highly experienced surgical myectomy centers (Table 1). These deaths occurred only in older patients and during the post-interventional period, which underlines the importance of careful hospital monitoring. Reports of delayed occurrence of complete heart block up to 10 days after the intervention deserve careful attention, as this event emphasizes the need for close monitoring for arrhythmia during several days after the intervention.³⁹

After the introduction of MCE the number of permanent pacemaker implantations for permanent trifascicular block was reduced to less than 5%, a figure approaching the range of postoperative implantations.¹⁰ Furthermore, the development of complete heart block after septal ablation can be predicted using a score introduced by Faber et al.⁴⁰ In addition to trifascicular blocks, all groups reported the occurrence of bundle-branch block in about 50% of the patients, predominantly involving the right bundle branch, in contrast to many patients after surgical myectomy who develop left bundle

branch block.

In contrast to myocardial infarction due to coronary artery disease, the incidence of significant ventricular dysrhythmia during and after ablation is very low. Another worrisome complication is iatrogenic reflux of alcohol into the left anterior descending coronary artery with transitory vessel occlusion and anterolateral ischemia.^{26,34} This can be avoided by technical improvements such as the use of a slightly oversized balloon and at least 10 minutes of continuous balloon inflation after the last alcohol injection.

Follow-up studies lasting up to 6 years have shown no increased risk of sudden death or arrhythmic complications.⁴¹ On the contrary, an impressive, steady and progressive improvement in symptoms, accompanied by an increase in objective measurements of exercise capacity, is clearly seen.^{17,26,41-43} Echocardiographic measurements document continued progressive reduction of the left ventricular outflow tract gradient.^{17,41} After a mean follow-up of 43 months, 90% of the patients showed complete elimination of the outflow tract gradient. This should be interpreted as an expression of post-interventional remodeling that follows induced septal infarction, analogous to the remodeling following acute myocardial infarction. These findings also underscore the aim of our strategy to induce septal necrosis by alcohol ablation: although it should be large enough to be effective, it should also be kept as small as possible.

Remodeling after PTSMA results in reductions in

TABLE 2. **Advantages and potential drawbacks of percutaneous septal ablation and surgical myectomy**

Percutaneous septal ablation (PTSMA)	Surgical myectomy
<p>Advantage</p> <ul style="list-style-type: none"> Avoidance of cardiopulmonary bypass with attendant risks (older patients with concomitant non-cardiac disease) Treatment of patients with isolated mid-cavitary or combined subaortic and mid-cavitary obstruction Short hospital stay Lower costs <p>Potential drawbacks</p> <ul style="list-style-type: none"> Risk of damage to the left coronary artery with emergency bypass surgery or left main/LAD stenting Technical impossibility of reaching or identifying a target septal branch Lower success in patients with mitral valve leaflet and papillary muscle abnormalities and with large septal thickness (younger patients) 	<p>Advantage</p> <ul style="list-style-type: none"> Immediate and complete relief of resting and provoked obstruction and concomitant mitral regurgitation Documented long-term results up to 30 years Ability to treat coexistent cardiac diseases Short recovery time Coronary artery disease, valve disease Additional treatment of papillary muscle in extended myectomy <p>Potential drawbacks</p> <ul style="list-style-type: none"> Need for high individual level of surgical experience high surgical mortality at inexperienced centers Low risk of postoperative aortic regurgitation LV deterioration after extended myectomy during long-term follow-up, possibly due to More invasive approach requiring extracorporeal circulation

high incidence of left bundle branch block

both ventricular septal thickness and left ventricular posterior wall thickness.^{17,41,44} As in surgical myectomy,⁴⁵ these findings must be interpreted as a result of the elimination of (or at least the reduction in) the pressure overload. Negative effects of the induced septal infarction, particularly left ventricular enlargement, have not been described. Preliminary studies have shown a reduction in reported risk factors for sudden cardiac death, such as exertional syncope, abnormal blood pressure response, and exercise-induced ischemia, after successful PTSMA.⁴⁶

PERSPECTIVES

Up to now, no randomized trials comparing surgical and percutaneous treatment with septal reduction in HOCM have been published.⁴⁷ Non-randomized trials have shown significant reductions in left ventricular outflow tract (LVOT) obstruction and symptomatic improvement with both treatment options.⁴⁸⁻⁵⁰ Therefore, the benefits and drawbacks for each therapeutic method (Table 2) must be weighed when deciding on treatment for LVOT obstruction. This decision should take into consideration several clinical, morphological, and technical factors. Although there are some reports of successful combined simultaneous or diffuse percutaneous treatment of HOCM and coronary artery disease,²⁵ it should be considered that surgery involves primarily the ability to deal with HOCM

and coexistent heart diseases (such as coronary artery disease) or to perform valve replacement. In patients with HOCM and mitral regurgitation, pathological and morphologic findings in the mitral valve apparatus should determine the preferred treatment option. Overall, surgery and percutaneous septal ablation should be considered alternative approaches to HOCM. The final decision should be made on an individual basis for each patient in order to achieve optimal results. In addition to the points mentioned above, the individual experience of the center should be taken into consideration.

CONCLUSION

Nearly one decade after its introduction, percutaneous septal ablation is a promising treatment option for symptomatic patients with HOCM refractory to medical treatment. The morphological, hemodynamic, and clinical effects (Figure 2) have been well described. Intra-procedure echocardiographic monitoring results in optimal targeting of the area of the septum to be ablated, with concomitant reductions in peri-interventional complications and improved acute and medium-term hemodynamic results. However, possible complications and limited long-term effects mandate careful patient selection. In order to avoid overuse of the technique, we would emphasize the importance of restricting alcohol septal ablation to a few centers with extensive experien-

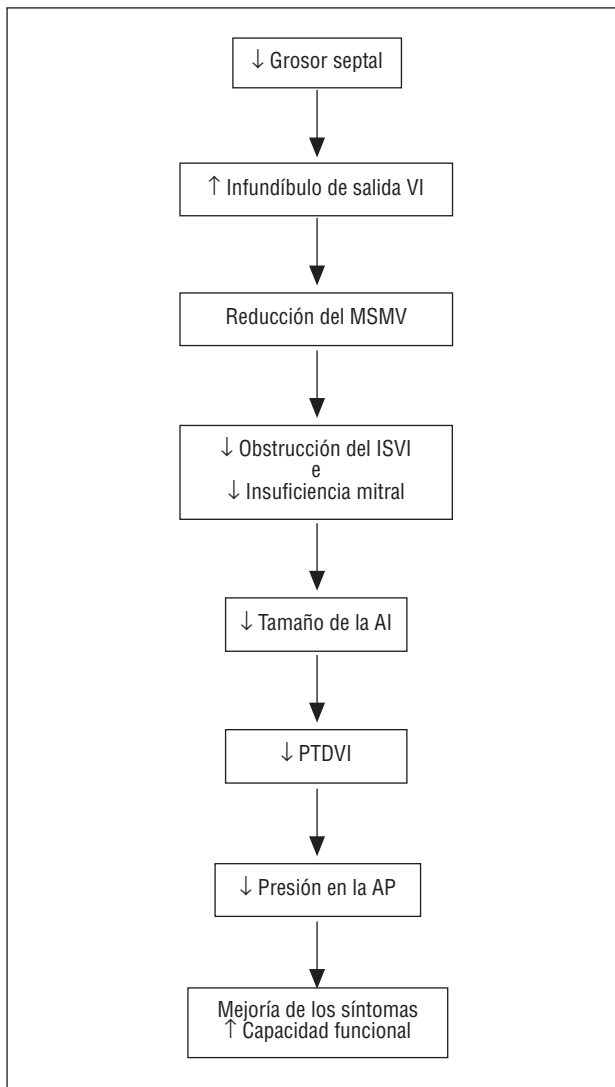


Fig. 2. Morphologic, hemodynamic, and clinical effects of percutaneous septal ablation. (↓ indicates reduction; ↑, increase; LV, left ventricle; SAM, systolic anterior motion of the mitral valve apparatus; LVOT, left ventricular outflow tract; LA, left atrium; LVEDP, left ventricular end-diastolic pressure; PA, pulmonary artery).

ce in interventional and echocardiographic interventions and a solid knowledge of this uncommon disease.

REFERENCES

1. Wigle ED, Rakowski H, Kimball BP, Williams WG. Hypertrophic cardiomyopathy: clinical spectrum and treatment. *Circulation* 1995;92:1680-92.

2. Spirito P, Seidman CE, McKenna WJ, Maron BJ. The management of hypertrophic cardiomyopathy. *N Engl J Med* 1997;336:775-85.
3. Frank MJ, Abdulla AM, Canedo MI, Saylor RE. Long-term medical management of hypertrophic obstructive cardiomyopathy. *Am J Cardiol* 1978;42:993-1001.
4. Haberer T, Hess OM, Jenni R, Krayenbühl HP. Hypertrophic obstructive cardiomyopathy: Spontaneous course in comparison to long-term therapy with propranolol and verapamil. *Z Kardiol* 1983;72:487-93.
5. Harrison DC, Braunwald E, Glick G, Mason DT, Chidsey CA, Ross Jr J. Effects of beta adrenergic blockade on the circulation with particular reference to observations in patients with hypertrophic subaortic stenosis. *Circulation* 1964;29:84-98.
6. Kaltenbach M, Hopf R, Kober G, Bussmann WD, Keller M, Petersen Y. Treatment of hypertrophic obstructive cardiomyopathy with verapamil. *Br Heart J* 1979;42:35-42.
7. Pollick C. Muscular subaortic stenosis: hemodynamic and clinical improvement after disopyramide. *N Engl J Med* 1982;307:997-9.
8. Kimball BP, Bui S, Wigle ED. Acute dose-response effects of intravenous disopyramide in hypertrophic obstructive cardiomyopathy. *Am Heart J* 1993;125:1691-7.
9. Maron BJ. Appraisal of dual-chamber pacing therapy in hypertrophic cardiomyopathy: too soon for a rush to judgment? *J Am Coll Cardiol* 1996;27:431-2.
10. Schulte HD, Gramsch-Zabel H, Schwartzkopff B. Hypertrophe obstruktive Kardiomyopathie: Chirurgische Behandlung. *Schweiz Med Wschr* 1995;125:1940-9.
11. Robbins RC, Stinson EB, Daily PO. Long-term results of left ventricular myotomy and myectomy for obstructive hypertrophic cardiomyopathy. *J Thorac Cardiovasc Surg* 1996;111:586-94.
12. Heric B, Lytle BW, Miller DP, Rosenkranz ER, Lever HM, Cosgrove DM. Surgical management of hypertrophic obstructive cardiomyopathy. Early and late results. *J Thorac Cardiovasc Surg* 1995;110:195-208.
13. Schoendube FA, Klues HG, Reith S, Flachskampf FA, Hanrath P, Messmer BJ. Long-term clinical and echocardiographic follow-up after surgical correction of hypertrophic obstructive cardiomyopathy with extended myectomy and reconstruction of the subvalvular mitral apparatus. *Circulation* 1995;92(Suppl II):122-7.
14. Nishimura RA, Trusty JM, Hayes DL, Ilstrup DM, Larson DR, Hayes SN, et al. Dual-chamber pacing for hypertrophic cardiomyopathy: a randomized, double-blind, crossover trial. *J Am Coll Cardiol* 1997;29:435-41.
15. Maron BJ, Nishimura RA, McKenna WJ, Rakowski H, Josephson ME, Kieval RS. Assessment of permanent dual-chamber pacing as a treatment for drug-refractory symptomatic patients with obstructive hypertrophic cardiomyopathy. A randomized, double-blind, crossover study (M-PATHY). *Circulation* 1999;99:2927-33.
16. Linde C, Gadler F, Kappenberger L, Ryden L. Placebo effect of pacemaker implantation in obstructive hypertrophic cardiomyopathy. PIC Study Group. Pacing in cardiomyopathy. *Am J Cardiol* 1999;83:903-7.
17. Seggewiss H. Current status of alcohol septal ablation for patients with hypertrophic cardiomyopathy. *Curr Cardiol Rep* 2001;3:160-6.
18. Sigwart U. Non-surgical myocardial reduction of hypertrophic obstructive cardiomyopathy. *Lancet* 1995;346:211-4.
19. Kuhn H, Gietzen F, Leuner C, Gerenkamp T. Induction of suba-

- ortic septal ischaemia to reduce obstruction in hypertrophic obstructive cardiomyopathy. Studies to develop a new catheter-based concept of treatment. *Eur Heart J* 1997;18:846-51.
20. Seggewiss H, Gleichmann U, Faber L, Fassbender D, Schmidt HK, Strick S. Percutaneous transluminal septal myocardial ablation (PTSMA) in hypertrophic obstructive cardiomyopathy: acute results and 3-month follow-up in 25 patients. *J Am Coll Cardiol* 1998;31:252-8.
21. Faber L, Seggewiss H, Gleichmann U. Percutaneous transluminal septal myocardial ablation in hypertrophic obstructive cardiomyopathy: acute and 3-months follow-up results with respect to myocardial contrast echocardiography. *Circulation* 1998;98:2415-21.
22. Faber L, Seggewiss H, Fassbender D, et al. Guiding of percutaneous transluminal septal myocardial ablation in hypertrophic obstructive cardiomyopathy by myocardial contrast echocardiography. *J Interv Cardiol* 1998;11:443-8.
23. Maron BJ, Casey SA, Poliac LC, Gohman TE, Almquist AK, Aeppli DM. Clinical course of hypertrophic cardiomyopathy in a regional United States cohort. *JAMA* 1999;281:650-5.
24. Maron MS, Olivetto I, Betocchi S, Casey SA, Lesser JR, Losi MA, et al. Effect of left ventricular outflow tract obstruction on clinical outcome in hypertrophic cardiomyopathy. *N Engl J Med* 2003;348:295-303.
25. Seggewiss H, Faber L, Meyners W, Bogunovic N, Odenthal HJ, Gleichmann U. Simultaneous percutaneous treatment in hypertrophic obstructive cardiomyopathy and coronary artery disease: a case report. *Cathet Cardiovasc Diagn* 1998;44:65-9.
26. Knight C, Kurbaan AS, Seggewiss H, Henein M, Gunning M, Harrington D, et al. Non-surgical septal reduction for hypertrophic obstructive cardiomyopathy: outcome in the first series of patients. *Circulation* 1997;95:2075-81.
27. Lakkis N, Kleiman N, Killip D, Spencer WH 3rd. Hypertrophic obstructive cardiomyopathy: alternative therapeutic options. *Clin Cardiol* 1997;20:417-8.
28. Bhargava B, Agarwal R, Kaul U, Manchanda SC, Wasir HS. Transcatheter alcohol ablation of the septum in a patient of hypertrophic obstructive cardiomyopathy. *Cathet Cardiovasc Diagn* 1997;41:56-8.
29. Kornacewicz-Jach Z, Gil R, Wojtarowicz A, et al. Early results of alcohol ablation of the septal branch of coronary artery in patients with hypertrophic obstructive cardiomyopathy. *Kardiologia Pol* 1998;48:105-12.
30. Nagueh SF, Lakkis NM, He ZX, Middleton KJ, Killip D, Zoghbi WA, et al. Role of myocardial contrast echocardiography during nonsurgical reduction therapy for hypertrophic obstructive cardiomyopathy. *J Am Coll Cardiol* 1998;32:225-9.
31. Gietzen FH, Leuner CJ, Raute-Kreinsen U, Dellmann A, Hegselmann J, Strunk-Mueller C, et al. Acute and long-term results after transcoronary ablation of septal hypertrophy (TASH). Catheter interventional treatment for hypertrophic obstructive cardiomyopathy. *Eur Heart J* 1999;20:1342-54.
32. Seggewiss H, Faber L, Gleichmann U. Percutaneous transluminal septal ablation in hypertrophic obstructive cardiomyopathy. *Thorac Cardiovasc Surg* 1999;47:94-100.
33. Faber L, Meissner A, Ziemssen P, Seggewiss H. Percutaneous transluminal septal myocardial ablation for hypertrophic obstructive cardiomyopathy: long term follow up of the first series of 25 patients. *Heart* 2000;83:326-31.
34. Ruzyllo W, Chojnowska L, Demkow M, Witkowski A, Kusmierczyk-Droszcz B, Piotrowski W, et al. Left ventricular outflow tract gradient decrease with non-surgical myocardial reduction improves exercise capacity in patients with hypertrophic obstructive cardiomyopathy. *Eur Heart J* 2000;21:770-7.
35. Seggewiss H, Faber L, Ziemssen P, Meyners W, Krater L, Meissner A, et al. Age related acute results in percutaneous septal ablation in hypertrophic obstructive cardiomyopathy [abstract]. *J Am Coll Cardiol* 2000;35(Suppl A):A188.
36. Seggewiss H, Faber L, Ziemssen P, Meyners W. Non-surgical septal ablation (PTSMA) in patients with NYHA class IV and hypertrophic obstructive cardiomyopathy (HOCM) [abstract]. *Circulation* 1999;100(Suppl I):515.
37. Singh M, Edwards WD, Holmes DR Jr, Tajil AJ, Nishimura RA. Anatomy of the first septal perforating artery: a study with implications for ablation therapy for hypertrophic cardiomyopathy. *Mayo Clin Proc* 2001;76:799-802.
38. Seggewiss H, Faber L. Percutaneous septal ablation for hypertrophic cardiomyopathy and mid-ventricular obstruction. *Eur J Echocardiogr* 2000;1:277-80.
39. Kern MJ, Holmes DG, Simpson C, Bitar SR, Rajjoub H. Delayed occurrence of complete heart block without warning after alcohol septal ablation for hypertrophic obstructive cardiomyopathy. *Cathet Cardiovasc Interv* 2002;56:503-7.
40. Faber L, Seggewiss H, Werlemann BC, Fassbender D, Schmidt HK, Horstkotte D. Prediction of the risk of pacemaker dependency after percutaneous septal ablation for hypertrophic obstructive cardiomyopathy [abstract]. *J Am Coll Cardiol* 2002;39(Suppl A):845-3.
41. Welge D, Faber L, Werlemann BC, Krater L, Seggewiss H, Gleichmann U, et al. Long-term outcome after percutaneous septal ablation for hypertrophic obstructive cardiomyopathy. *J Am Coll Cardiol* 2002;39:A845.
42. Ziemssen P, Faber L, Schlichting J, Meyners W, Horstkotte D, Seggewiss H. Percutaneous septal ablation in patients with hypertrophic obstructive cardiomyopathy results in improvement of exercise capacity. *J Am Coll Cardiol* 2000;35:A182.
43. Boekstegers P, Steinbigler P, Molnar A, Schwaiblmair M, Becker A, Knez A, et al. Pressure-guided nonsurgical myocardial reduction induced by small septal infarctions in hypertrophic obstructive cardiomyopathy. *J Am Coll Cardiol* 2001;38:846-53.
44. Mazur W, Nagueh SF, Lakkis NM, Middleton KJ, Killip D, Roberts R, et al. Regression of left ventricular hypertrophy after nonsurgical septal reduction therapy for hypertrophic obstructive cardiomyopathy. *Circulation* 2001;103:1492-6.
45. Curtius JM, Stoecker J, Loesse B, Welslau R, Scholz D. Changes of the degree of hypertrophy in hypertrophic obstructive cardiomyopathy under medical and surgical treatment. *Cardiology* 1989;76:255-63.
46. Seggewiss H, Faber L, Ziemssen P, Gleichmann U. One year follow-up after echocardiographically-guided percutaneous septal ablation in hypertrophic obstructive cardiomyopathy. *Dtsch Med Wochenschr* 2001;126:424-30.
47. Seggewiss H, Faber L, Kleikamp G, Becker J, Gleichmann U. Hypertrophic obstructive cardiomyopathy and coronary artery disease: surgical or interventional therapy. *Eur Heart J* 1998;19(Suppl):624.
48. Qin JX, Shiota T, Lever HM, Kapadia SR, Sitges M, Rubin DN, et al. Outcome of patients with hypertrophic obstructive cardiomyopathy after percutaneous transluminal septal myocardial ablation and septal myectomy surgery. *J Am Coll Cardiol* 2001;38:

1994-2000.

49. Nagueh SF, Ommen SR, Lakkis NM, Killip D, Zoghbi WA, Schaff HV, et al. Comparison of ethanol septal reduction therapy with surgical myectomy for the treatment of hypertrophic obstructive cardiomyopathy. *J Am Coll Cardiol* 2001;38:1701-6.
50. Firoozi S, Elliott PM, Sharma S, Murday A, Brecker SJ, Hamid MS, et al. Septal myotomy-myectomy and transcatheter septal alcohol ablation in hypertrophic obstructive cardiomyopathy: a comparison of clinical, haemodynamic and exercise outcomes. *Eur Heart J* 2002;23:1617-24.
51. Gietzen FH, Leuner CJ, Obergassel L, Strunk-Mueller C, Kuhn H. Role of transcatheter ablation of septal hypertrophy in patients with hypertrophic cardiomyopathy, New York Heart Association functional class III or IV, and outflow obstruction only under provocative conditions. *Circulation* 2002;106:454-9.
52. Kuhn H, Gietzen FH, Leuner C, Schafers M, Schober O, Strunk-Mueller C, et al. Transcatheter ablation of septal hypertrophy: a new treatment for hypertrophic obstructive cardiomyopathy. *Z Kardiol* 2000;89(Suppl 4):41-54.