

# Severe Cyanosis After Total Cavopulmonary Connection, Corrected by Surgical Ligation of the Suprahepatic Veins

Daniel Borches,<sup>a</sup> Gustavo Brochet,<sup>a</sup> Ángel Aroca,<sup>a</sup> Luis García-Guereta,<sup>b</sup> Ernesto Sanz,<sup>a</sup> and Gregorio Cordovilla<sup>a</sup>

<sup>a</sup>Servicio de Cirugía Cardíaca Infantil, Hospital Universitario La Paz, Madrid, Spain.

<sup>b</sup>Servicio de Cardiología Infantil, Hospital Universitario La Paz, Madrid, Spain.

We describe a patient with a diagnosis of heterotaxia and independent drainage of the suprahepatic veins into the venous atrium who underwent total extracardiac cavopulmonary connection in which hepatic vein drainage remained directly into the atrium. In the immediate postoperative period she showed increasing cyanosis that suggested substantial right-to-left shunt. Surgical ligation of the suprahepatic veins resolved the complication effectively without signs of hepatic congestion or portal hypertension.

**Key words:** *Congenital heart disease. Hypoxia. Fontan procedure.*

Full English text available at: [www.revespcardiol.org](http://www.revespcardiol.org)

## Cianosis severa tras derivación cavopulmonar total, corregida mediante ligadura quirúrgica de las venas suprahepáticas

Se describe el caso de una paciente con diagnóstico de heterotaxia y drenaje independiente de las venas suprahepáticas en la aurícula venosa, que se sometió a una derivación cavopulmonar total extracardíaca, en la que se dejaron las venas suprahepáticas drenando en la aurícula a modo de fenestración. La aparición en el postoperatorio inmediato de cianosis progresiva indujo a pensar en una derivación de derecha a izquierda muy importante. La ligadura quirúrgica de las venas suprahepáticas resolvió la complicación de una manera efectiva, sin la aparición de signos de congestión hepática o hipertensión portal.

**Palabras clave:** *Cardiopatías congénitas. Hipoxia. Procedimiento de Fontan.*

## INTRODUCTION

Total cavopulmonary connection, or the Fontan procedure, was originally described in 1971.<sup>1</sup> However, several major modifications to the procedure have been made in recent years, and the indication has been expanded to include a wide variety of heart problems where biventricular correction is not feasible.<sup>2</sup> In high-risk patients, leaving a small part of venous flow to drain directly into the systemic atrium by an opening of controlled size has been shown to significantly improve morbidity and mortality during the postoperative period.<sup>3</sup> In a few special cases of infradiaphragmatic anomalous venous drainage, surgical alternatives other than fenestration have been proposed, as they

also allow part of the venous blood to drain into the systemic atrium.<sup>4</sup>

We present the case of a patient who underwent total cavopulmonary connection, in whom the suprahepatic veins were left to drain independently into the systemic atrium as a venous relief measure. The patient later developed severe progressive cyanosis which was corrected by additional surgery.

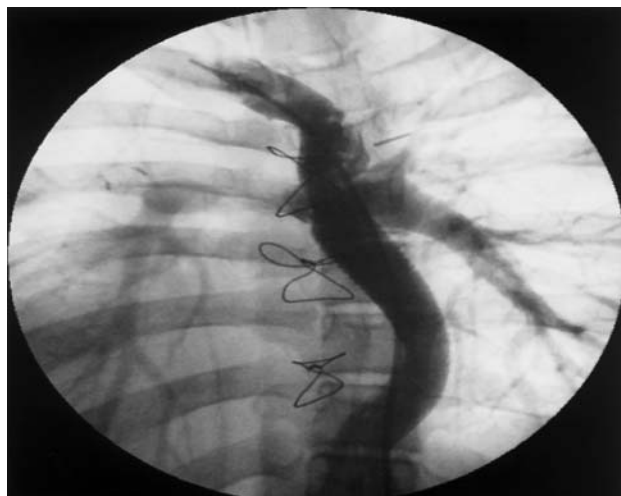## Case Study

A 15-year-old patient was admitted to our hospital for total cavopulmonary connection, with a diagnosis of viscerotaxial situs ambiguous, dextrocardia, single double-outlet right ventricle with aorta in d-malposition, atresia of the venous atrioventricular valve, and valvular and subvalvular pulmonary stenosis. She also presented independent drainage of the suprahepatic veins into the venous atrium through a single main vessel, separate from the inferior vena cava. At 30 months of age, the patient had undergone a modified Blalock-Taussig systemic-pulmonary shunt, and at 11 years of age, she underwent a bidirectional Glenn pro-

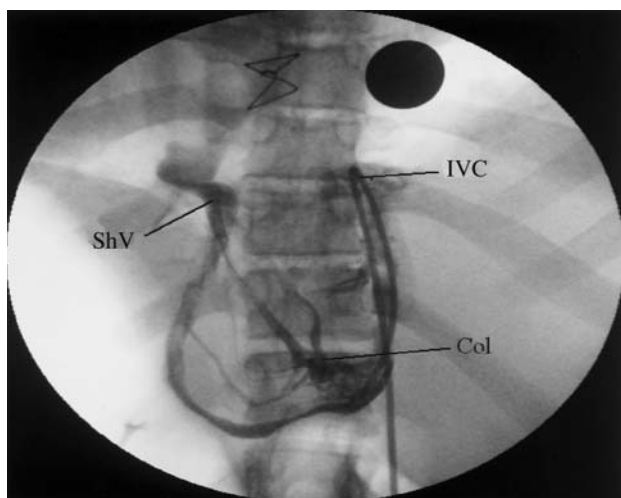
Correspondence: Dr. D. Borches.  
Servicio de Cirugía Cardíaca Infantil. Hospital Universitario La Paz.  
P.º de la Castellana, 261. 28046 Madrid. España.  
E-mail: [dborches.hulp@madrid.salud.org](mailto:dborches.hulp@madrid.salud.org)

Received 17 March, 2003.

Accepted for publication 12 January, 2004.



**Fig. 1.** Angiographic image obtained by injecting contrast material into the superior vena cava. Filling of the entire tube graft shows inverted flow from the superior vena cava toward the inferior vena cava.



**Fig. 2.** Angiographic image obtained by injecting contrast material into the venous collateral arising from the inferior vena cava, which shows the intrahepatic venous collaterals that connect the inferior vena cava to the suprahepatic vein. IVC indicates inferior vena cava; ShV, suprahepatic veins; Col, collaterals.

cedure, plus ligation and sectioning of the shunt, leaving a patent pulmonary trunk.

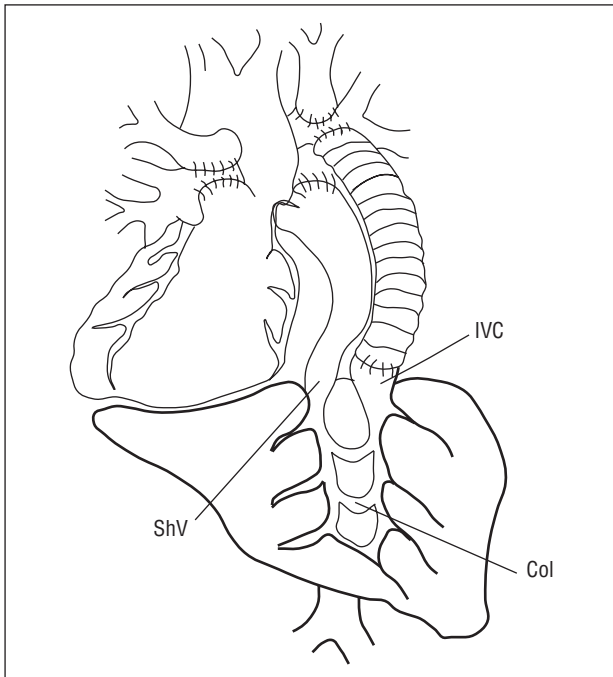
On-pump cavopulmonary connection was performed without aortic cross-clamping, connecting the inferior vena cava to the pulmonary artery with an 18-mm extracardiac tube graft of crimped Dacron. No fenestration was made; however, as recommended by Kawashima et al,<sup>4</sup> the main vessel of the suprahepatic veins was left to drain independently into the venous atrium. At the end of surgery oxygen saturation was 90%-95% SpO<sub>2</sub> and at 24 h it began to drop. The patient was moved to the ward on day three with a SpO<sub>2</sub> of 85%; by day four she presented severe cyanosis that

increased significantly over the next few days, reaching 60%-65%.

Contrast echocardiography showed that the graft was patent, although flow was inverted from the pulmonary arteries toward the inferior vena cava during part of the cardiac cycle. Cardiac catheterization confirmed the echocardiographic diagnosis. Coronary angiography showed inverted flow within the graft (Figure 1) and a large network of venous collaterals draining from the inferior vena cava to the main vessel of the suprahepatic veins and from there to the atrium (Figure 2). In view of this situation, a decision was made to reoperate and proceed to surgical ligation of the main vessel of the suprahepatic veins. The patient underwent surgery 30 days after the first operation, and the SpO<sub>2</sub> immediately rose to 95%. The postoperative period was unremarkable, and there was no pleural effusion. The patient was discharged 10 days later. Twelve months after the operation, the patient was symptom-free, with a SpO<sub>2</sub> of 95% and no clinical or analytical evidence of hepatic congestion.

## DISCUSSION

When total cavopulmonary connection is done in high-risk patients, the recommendation is to leave a small part of systemic venous flow draining in the atria in order to lower venous pressure and improve cardiac preload and cardiac index.<sup>5,6</sup> A fenestration of 3-3.5 mm in diameter is the most commonly used technique. Nevertheless, other methods have been proposed to partially divert venous flow. In 1984 Kawashima et al<sup>4</sup> described the possibility of leaving the suprahepatic veins draining independently in the atrium to divert venous load in patients with heterotaxia<sup>7</sup> and anomalous systemic venous drainage. This technique has been used by various surgical teams since that time. In 28% of patients with heterotaxia, the suprahepatic veins are either isolated from the inferior vena cava or the inferior vena cava is absent with azygos or hemiazygos continuation, and drain independently into the venous atrium.<sup>7</sup> However, in a few cases, severe cyanosis appeared in the immediate postoperative period or later as a result of the development of splanchnic-portal collateral circulation, with substantial venous flow toward the systemic atrium.<sup>8-10</sup> If this major complication arises, several therapeutic options can be used to interrupt venous flow toward the atrium and divert flow from the suprahepatic veins toward the pulmonary region. This objective could be met by rechanneling the outlet of the suprahepatic veins into the systemic venous territory,<sup>11</sup> or simply obstructing the outlet of these veins and allowing the network of intrahepatic and extrahepatic collaterals to act as a channel toward the venous territory.<sup>12</sup> In the latter case, however, there is a potential for hepatic congestion and portal hypertension if the intrahepatic



**Fig. 3.** Diagram of the laterality alteration with dextrocardia, showing the intrahepatic venous system and its anastomoses. IVC indicates inferior vena cava; ShV, suprahepatic veins; Col, collaterals.

venous system is not sufficient to allow adequate drainage. Presumably, pressure gradients higher than 10 mm Hg between the portal and systemic venous system would lead to portal hypertension and esophageal varices.<sup>8,13</sup>

In our patient, we opted for surgical ligation of the suprahepatic vein trunk. We felt that, because the intrahepatic collaterals were allowing considerable blood flow from the systemic territory toward the portal with hardly any pressure gradient, it would also do so in the opposite direction after ligation of the suprahepatic vein (Figure 3). The favorable postoperative course, both clinically and in laboratory parameters, confirms that the system of collaterals was sufficiently developed to allow good portal drainage in our case.

Based on our experience in this case, we conclude that the suprahepatic veins should not be left to drain freely into the atrium as a form of fenestration, since this circumstance would be enhanced by the early development of pulmonary arteriovenous fistulas when the hepatic venous blood does not drain into the pulmonary circulation.<sup>14</sup>

## REFERENCES

- Fontan F, Baudet E. Surgical repair of tricuspid atresia. *Thorax* 1971;26:240-8.
- King RM, Puga FJ, Danielson GK, Julsrud PR. Extended indications for the modified Fontan procedure in patients with anomalous systemic and pulmonary venous return. In: Doyle EF, Allen Engle M, Gersony WM, Rashkind WJ, Telner NS, editors. *Abstracts from the Second World Congress of Paediatric Cardiology*. New York: Springer-Verlag, 1985.
- Bridges ND, Lock JE, Castaneda AR. Baffle fenestration with subsequent transcatheter closure. Modification of Fontan operation for patients at increased risk. *Circulation* 1990;82:1681-9.
- Kawashima Y, Kitamura S, Matsuda H, Shimazaki Y, Nakano S, Hirose H. Total cavopulmonary shunt operation in complex cardiac anomalies. *J Thorac Cardiovasc Surg* 1984;87:74-81.
- Castaneda AR, Bridges ND. The Fontan operation with a fenestrated patch-rationale and results. *Cardiol Young* 1993;3:202-6.
- Laks H, Milliken JC, Perloff JK, Hellenbrand WE, George BL, Chin A, et al. Experience with the Fontan procedure. *J Thorac Cardiovasc Surg* 1984;88:939-51.
- Icardo JM, García Rincón JM, Ros MA. Malformaciones cardíacas, heterotaxia y lateralidad. *Rev Esp Cardiol* 2002;55:962-74.
- Waterbolk TW, Talsma MD, Loeff BG, Slooff MJH, Ebels T. Increasing cyanosis after total cavopulmonary connection treated by banding and separate liver vein. *Ann Thorac Surg* 1995;59:1226-8.
- Hishitani T, Ogawa K, Hoshino K, Nakamura Y. Surgical ligation of anomalous hepatic vein in a case of heterotaxy syndrome with massive intrahepatic shunting after modified fontan operation. *Pediatr Cardiol* 1999;20:428-30.
- Kaneko Y, Murakami A, Miyamoto T, Takamoto S. Hepatic vein-to-azygos vein connection in a patient with interrupted inferior vena cava. *Eur J Cardiothorac Surg* 2002;21:582-4.
- Uemura H, Yagihara T, Hattori R, Kawashira Y, Tsukano S, Watanabe K. Redirection of hepatic venous drainage after total cavopulmonary shunt in left isomerism. *Ann Thorac Surg* 1999;68: 1731-5.
- Hishitani T, Ogawa K, Hoshino K, Nakamura Y. Surgical ligation of anomalous hepatic vein in a case of heterotaxy syndrome with massive intrahepatic shunting after modified Fontan operation. *Pediatr Cardiol* 1999;20:428-30.
- Shun A, Delaney DP, Martín HCO, Henry GM, Stephen M. Portosystemic shunting for paediatric portal hypertension. *J Pediatr Surg* 1997;32:489-93.
- Srivastava D, Preminger T, Lock JE, Mandell V, Keane JF, Mayer JE, et al. Hepatic venous blood and the development of pulmonary arteriovenous malformations in congenital heart disease. *Circulation* 1995;92:1217-22.