

ST Segment Elevation During Dipyridamole Stress Testing in a Patient Without Coronary Lesions

Óscar Díaz-Castro,^a Jesús Fernández-López,^a Luis Campos,^b Francisco Calvo,^a Ramón Mantilla,^c and Javier Goicolea^c

^aServicio de Cardiología, Hospital do Meixoeiro, Pontevedra, Spain.

^bMedicina-Nuclear, Hospital do Meixoeiro, Pontevedra, Spain.

^cHemodinámica-MEDTEC, Hospital do Meixoeiro, Pontevedra, Spain.

We describe a patient who presented transient ST-segment elevation and typical chest pain during an ischemia test with dipyridamole and technetium-tetrofosmin. Chest pain and electrical alterations disappeared promptly with sublingual nitroglycerin. Coronary angiography showed no epicardial lesions, and coronary vasospasm was suspected. We discuss possible explanations for this complication.

Key words: *Isotopes. Stress. Vasospasm.*

Full English text available at: www.revespcardiol.org

Elevación del segmento ST durante una tomografía computarizada por emisión de fotones simples con dipiridamol en ausencia de lesiones coronarias

Presentamos el caso de una paciente que presentó elevación del segmento ST con angina y alteraciones en la perfusión isotópica durante una prueba de detección de isquemia con tomografía computarizada por emisión de fotones simples con tecnecio-tetrofosmín y dipiridamol como agente inductor de isquemia. El cuadro clínico y las alteraciones eléctricas cedieron en pocos minutos con la administración de nitroglicerina sublingual. La coronariografía posterior no mostró lesiones coronarias, por lo que el cuadro se interpretó como probable vasospasmo. Se discuten los posibles mecanismos explicativos.

Palabras clave: *Isótopos. Estrés. Vasospasmo.*

INTRODUCTION

The drug dipyridamole is extensively used in the detection of myocardial ischemia, in both isotopic studies and stress echocardiography. The sensitivity and specificity of tests using dipyridamole for the detection of significant coronary disease is comparable to that of tests using other agents that induce ischemia, such as dobutamine or adenosine. Moreover, the rate of serious complications is low with dipyridamole and, as shown by a number of studies, lower than that of the other two drugs mentioned above.¹⁻⁴ Here we describe a case of ST-segment elevation that occurred during dipyridamole administration in a patient with no significant coronary lesion.

Correspondence: Dr. O. Díaz-Castro.
Servicio de Cardiología, 5.ª planta. Hospital do Meixoeiro.
Meixoeiro, s/n. 36200 Vigo. España.
E-mail: odiazcastro@hotmail.com

Received 26 August, 2003.

Accepted for publication 13 November, 2003.

CASE REPORT

A 73-year-old woman with hypertension and hypercholesterolemia presented with dyspnea and atypical chest pain. Treatment with vasodilators, beta-blockers and statins had been started. Echocardiography demonstrated mild left ventricular hypertrophy, but no other abnormalities. Single-photon emission computerized tomography (SPECT) of the heart was carried out using ^{99m}Tc-tetrofosmin and dipyridamole. Two minutes after completion of the dipyridamole infusion, which was carried out in accordance with the standard laboratory protocol (i.e., 0.84 mg/kg in 10 min), the patient reported typical chest pain. This was accompanied by an ST-segment elevation of up to 3 mm in leads II, III, aVF and V4–V6 (Figure 1A), which ceased after nitroglycerin administration (Figure 1B). Subsequent analysis of the SPECT images revealed the presence of reversible hypoperfusion in the inferior and anterior apical walls (Figure 2). On suspicion of severe coronary disease, the patient was admitted to hospital. Coronary angiography carried out two days later failed to demonstrate the presence of significant coronary lesions.

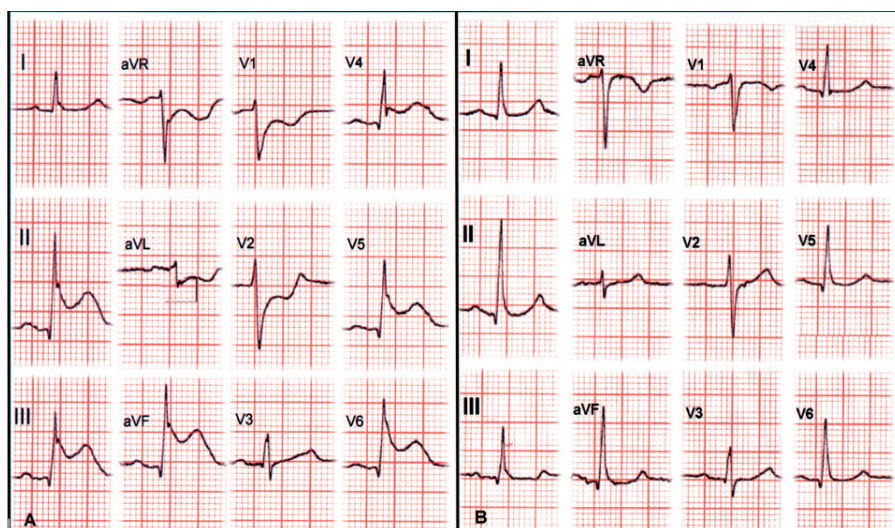


Fig. 1. Electrocardiograms made (A) during the episode of chest pain and ST-segment elevation and (B) after the administration of nitroglycerin.

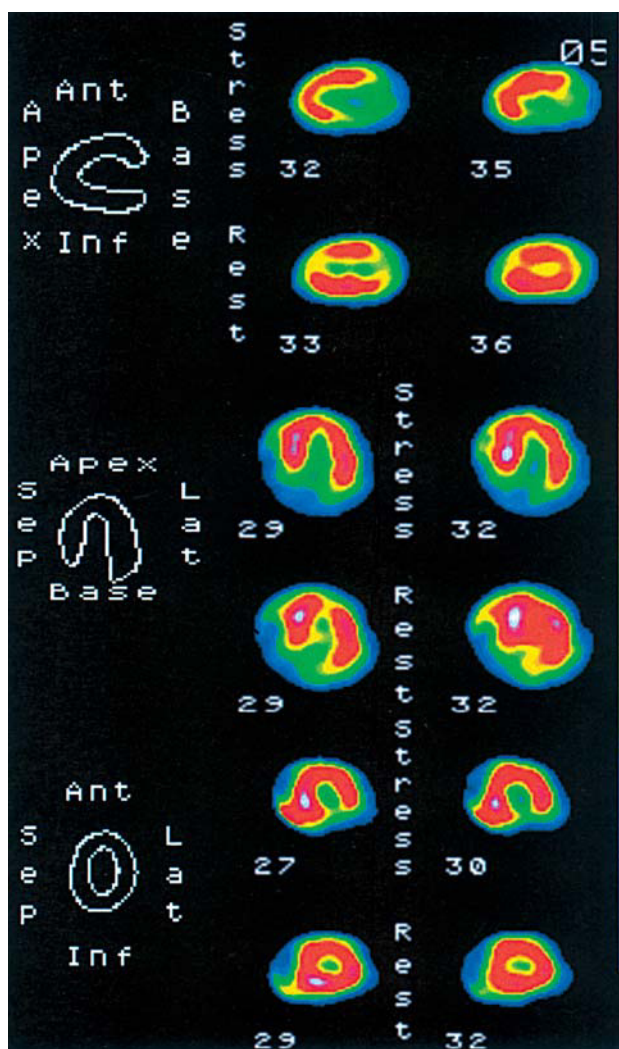


Fig. 2. Single-photon emission computerized tomography (SPECT) of the heart using technetium-99.

DISCUSSION

The active mechanism underlying dipyridamole's ability to induce ischemia is flow redistribution ("coronary theft") towards "healthy" areas to the disadvantage of regions with significant coronary lesions. This effect is achieved through an increase in extracellular adenosine level (dipyridamole blocks cellular reuptake), which causes vasodilatation in healthy areas. However, other mechanisms have also been proposed.⁵

The side effects of dipyridamole, although frequent (40%–55%), are generally self-limiting and of little importance. Reported side effects include chest pain (not always due to ischemia), headache, erythema or flushing, dizziness, bronchospasm and hypotension.⁶ Serious complications have also been described, such as acute myocardial infarction, ventricular arrhythmia and, even, death (<0.5%).⁷

Dipyridamole-induced ST-segment elevation has been reported in patients without coronary lesions at the end of test procedures and following aminophylline administration, and has been attributed to the sudden ending of vasodilatory stimulation.⁸ We found two references to probable dipyridamole-induced vasospasm in patients without coronary lesions. In one, in whom ST-segment elevation was also detected in the inferior wall, vasospasm ceased after aminophylline administration.⁹ The other patient had pseudoxanthoma elasticum.¹⁰

The mechanism by which a vasodilatory agent can induce transmural ischemia in the absence of coronary disease has not been explained. One possibility is the induction of severe systemic hypotension, which has been reported to occur with dipyridamole.⁶ However, in our patient, the arterial pressure remained similar to that found at the start of the test (i.e., 120/70 mm Hg).

Another possible explanation is that regional alterations in the coronary microvasculature (e.g., in the inferior wall) result in the "theft" of blood flow by areas with a healthy microvasculature. Heterogeneous, localized and segmental dysfunction of small coronary vessels has been reported to occur in some areas but not others, perhaps as a focal manifestation of arteriosclerosis or as the result of alterations in capillary size.¹¹ Alternatively, it is also possible that the mechanism of the probable vasospasm is independent of dipyridamole infusion and is actually secondary to the release of catecholamines due to nervousness or anxiety. However, the fact that the heart rate and arterial pressure remained stable in our patient during testing does not lend support to this hypothesis.

REFERENCES

1. Makan M, Pérez JE. Perspectivas sobre la utilización de las modalidades de imagen de estrés en la valoración inicial de la cardiopatía isquémica. *Rev Esp Cardiol* 2003;56:1010-5.
2. Zamorano J, Duque A, Baquero M, Moreno R, Almería C, Rodrigo JL, et al. Ecocardiograma de estrés en el preoperatorio de cirugía vascular: ¿son comparables los resultados con dipyridamol y dobutamina? *Rev Esp Cardiol* 2002;55:121-6.
3. Lette J, Tatum JL, Fraser S, Miller DD, Waters DD, Heller G, et al. Safety of dipyridamole testing in 73,806 patients: the Multicenter Dipyridamole Safety Study. *J Nucl Cardiol* 1995;2:3-17.
4. Álvarez L, Zamorano J, Mataix L, Almería C, Moreno R, Rodrigo JL. Espasmo coronario tras infusión de propranolol durante un ecocardiograma de estrés con dobutamina. *Rev Esp Cardiol* 2002;55:778-81.
5. Bin JP, Le E, Pelberg RA, Coggins MP, Wei K, Kaul S. Mechanism of inducible regional dysfunction during dipyridamole stress. *Circulation* 2002;106:112-7.
6. Johnston DL, Daley JR, Hodge DO, Hopfenspirger MR, Gibbons RJ. Hemodynamic responses and adverse effects associated with adenosine and dipyridamole pharmacologic stress testing: a comparison in 2,000 patients. *Mayo Clin Proc* 1995;70:331-6.
7. Ranhosky A, Kempthorne-Rawson J. Intravenous Dipyridamole Thallium Imaging Study Group. The Safety of dipyridamole thallium myocardial perfusion imaging. *Circulation* 1990;81:1205-9.
8. Picano E, Lattanzi F, Masini M, Distanti A, L'Abbate A. Aminophylline termination of dipyridamole stress as a trigger of coronary vasospasm in variant angina. *Am J Cardiol* 1988;62:694-7.
9. Weinmann P, le Gudulec D, Moretti JL. Coronary spasm induced by dipyridamole during myocardial scintigraphy. *Int J Cardiol* 1994;43:75-8.
10. Sakata K, Nakamura T, Tamekiyo H, Obayashi K, Ishikawa J, Nawada R, et al. Pseudoxanthoma elasticum with dipyridamole-induced coronary artery spasm: a case report. *Jpn Circ J* 1999;63:806-8.
11. Marroquin OC, Holubkov R, Edmundowicz D, Rickens C, Pohost G, Buchthal S, et al. Heterogeneity of microvascular dysfunction in women with chest pain not attributable to coronary artery disease: implications for clinical practice. *Am Heart J* 2003;145:628-35.