

Stereotaxis: A New Approach for Treating Highly Tortuous and Angulated Coronary Lesions After Conventional Techniques Have Failed

To the Editor:

Although it is an exception, extreme tortuosity of proximal coronary vessels may make it impossible to access the lesion to be treated during percutaneous coronary intervention (PCI). Recently, PCI treatment has seen the addition of a magnetic field-based navigation system (MNS) called Stereotaxis® (St. Louis, Missouri, United States) that allows us to control the guidewire's direction and its navigation through the coronary vessels; it also incorporates software called Navigant™ that permits us to create 3D reconstructions of the vessels to be treated. It can also integrate images taken with coronary angiotomography in order to use that information to control the guidewire's course through the coronary vessels.¹ This system has been used with good results in arrhythmia ablations² and in the field of neurosurgery.³ This technique is currently being

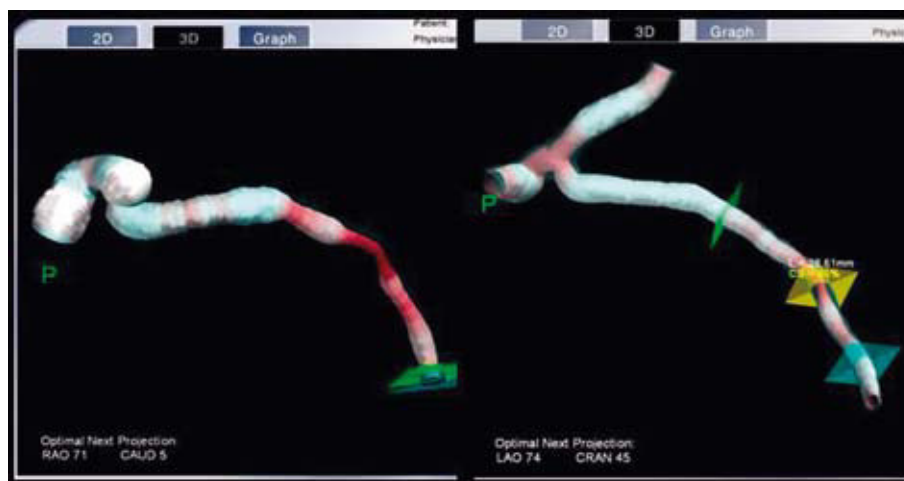


Figure 1. Three-dimensional reconstruction of the left coronary trunk and the circumflex artery.

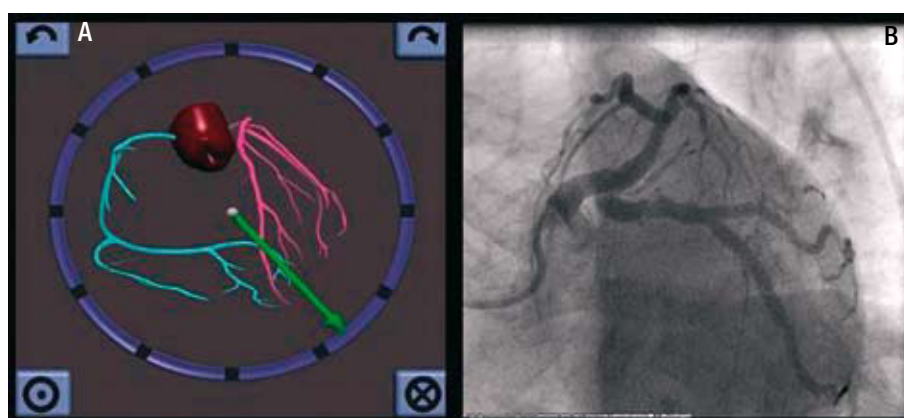


Figure 2. A: two-dimensional navigation showing the vector direction of the stereotaxis guidewire. B: coronariography showing the angles and tortuosity of the left coronary trunk of the circumflex artery, and the final result of the percutaneous coronary intervention.

investigated in the field of PCI for treating cases with complex coronary lesions, tortuous vessels, chronic total occlusions, to reduce procedure times, radiology exposure, and use of contrast,^{1,4} although its potential benefits are yet to be determined. There are few centres with experience in this field in Europe, and virtually no such experience in Spain.

We present the case of a 60-year-old female patient with hypertension and high cholesterol who was admitted with a diagnosis of non-ST segment elevation acute coronary syndrome. The coronary angiogram performed in the centre that referred her showed a severely diseased descending anterior artery (LAD) and the circumflex artery (CX); the ventriculography showed a slightly depressed systolic function with slight anterolateral hypokinesia. PCI was performed on the LAD with the implantation of a drug-eluting stent and PCI was attempted on the CX in a procedure more than 2 h long, using 200 mL of contrast. It was not possible to advance the guidewire despite making multiple attempts (changing to a guide wire with more support, using various BMW, Choice PT floppy, Whisper, Magnum, Pilot 50 and 150 guidewires to

aid with the Venture microcatheter and catheter) due to the extreme angles and tortuosity of the proximal CX segment. The patient was referred to our division to undergo PCI with stereotaxis. First, a 3D reconstruction of the left coronary trunk (LCT) and the CX using Naviview software (Figure 1) using previous angiographic images was carried out. Next, with the Stereotaxis Niobe MNS, we used 2-dimensional navigation (Figure 2A) to advance a specialized magnetic navigation guidewire with a 3 mm curve (made by Titan Soft support) up to the distal segment of the CX in 6 min, using 10 mL of contrast. We then implanted the drug-eluting stent successfully (Figure 2B). The patient was discharged with no complications.

This case illustrates the usefulness of MNS as a new alternative to facilitate treatment of patients with complex coronary lesions with extreme angles and tortuosity through which it has been impossible to pass a guidewire using conventional techniques.

Eric I. Canales, Julio Córdova, Javier Escaned,
and Rosana Hernández-Antolín
Unidad de Hemodinámica, Hospital Clínico San Carlos, Madrid, Spain.

REFERENCES

1. Kiemeneij F, Patterson M, Amoroso G, Rearman G, Slagboom T. Use of the stereotaxis Niobe, Magnetic navigation system for percutaneous coronary intervention: results from 350 consecutive patients. *Catheter Cardiovasc Inter.* 2008;71:510-6.
2. Faddis M, Chen J, Osborn J, Talcott M, Cain M, Lindsay B. Magnetic guidance system for cardiac electrophysiology. *J Am Coll Cardiol.* 2003;42:1952-8.
3. Chu J, Hsi W, Hubbard L, Zhang Y, Bernard D, Reeder P, et al. Performance of magnetic field guided navigation system for interventional neurosurgical and cardiac procedures. *J Appl Clin Med Phys.* 2005;6:143-9.
4. Atmakuri S, Lev E, Alviar C, Ibarra E, Raizner A, Solomon S, et al. Initial experience with a magnetic navigation system for percutaneous coronary intervention in complex coronary artery lesions. *J Am Coll Cardiol.* 2006;47:515-21.