

## Image in cardiology

# Symptomatic Late-acquired Coronary Dissection: Value of Intracoronary Images

## Dissección coronaria diferida sintomática: valor de la imagen intracoronaria

Roberto del Castillo Medina,\* Lorenzo Hernando Marrupe, and Javier Botas Rodríguez

Servicio de Cardiología, Hospital Universitario Fundación Alcorcón, Alcorcón, Madrid, Spain

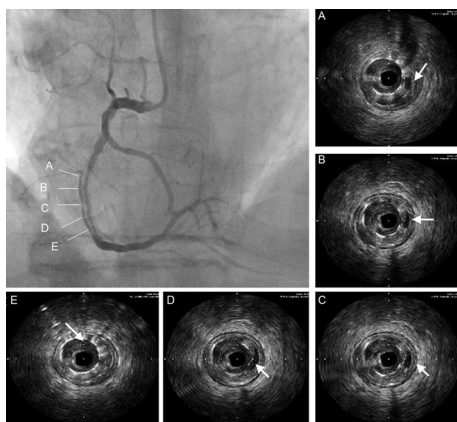


Figure 1.

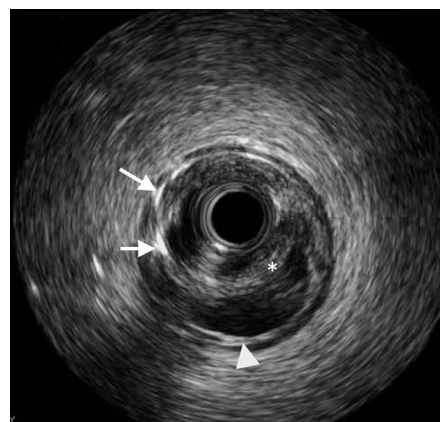


Figure 2.

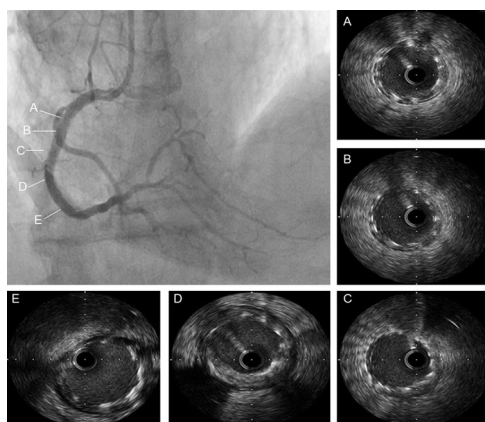


Figure 3.

An 80-year-old man, who was hypertensive, diabetic, and a smoker, was referred to our center due to unstable angina. He had been admitted to another center 3 months previously for a non-Q-wave infarction where he underwent percutaneous revascularization of the anterior descending artery and proximal and middle portions of the right coronary artery using 3 standard stents.

Right coronary angiography showed a double lumen image in the middle third, coinciding with the artery portion treated previously, providing an angiographic image of apparent dissection (Figs. 1A-E, arrows). Intracoronary ultrasound confirmed the presence of various phenomena (Fig. 2): a) incorrect positioning and underexpansion of both distal stents (arrows); b) contrast transfer to a parallel space with a semicircular cross-section (asterisk); and c) persistence of the intima-medial interface in the vessel wall (arrow tip) and the presence of an intimal/neointimal layer covering the outer surface of the stent.

The potential causes of these findings could have been the following: a) unsuitable selection of stent size in an artery with spasm and thrombus; b) partially subintimal trajectory of the stents; and c) dissection/intramural hematoma after stent implantation and late double lumen development due to reabsorption of the thrombotic content, or a combination of these causes.

An angioplasty was performed on the stent with appropriately-sized high pressure non-compliant balloons to position the stents properly and obliterate the adjacent lumen (Figs. 3A-E). The intracoronary ultrasound made a decisive contribution to the choice of materials and helped optimize the result.

\* Corresponding author:

E-mail address: [rcastillo@fhalcorcon.es](mailto:rcastillo@fhalcorcon.es) (R. del Castillo Medina).

Available online 25 July 2012