

# Tako-Tsubo Transient Left Ventricular Apical Ballooning Is Associated With a Left Anterior Descending Coronary Artery With a Long Course Along the Apical Diaphragmatic Surface of the Left Ventricle

Borja Ibáñez, Felipe Navarro, Jerónimo Farré, Pedro Marcos-Alberca, Miguel Orejas, Rosa Rábago, Manuel Rey, José Romero, Andrés Iñiguez, and Manuel Córdoba

Servicio de Cardiología, Fundación Jiménez Díaz, Universidad Autónoma de Madrid, Madrid, Spain.

**Introduction and objectives.** Tako-tsubo-like transient left ventricular apical ballooning has been described in Japan, but few cases have been reported in Western countries. We report one of the first series outside Japan, which provides new information on the coronary anatomy of this disorder.

**Patients and methods.** From January 1998 to February 2003 we observed 11 patients with a clinical suspicion of acute myocardial infarction, normal coronary arteries, and transient tako-tsubo-like systolic left ventricular apical ballooning. We compared the coronary artery anatomy in these 11 patients with that in 44 controls matched for age and sex: 22 with normal coronary arteries and 22 with acute myocardial infarction related with an obstructive thrombus in the left anterior descending coronary artery.

**Results.** As in Japanese patients, tako-tsubo syndrome in Caucasian patients frequently occurs in women in their seventh or eighth decades of life, and is usually preceded by emotional or physical stress. The left anterior descending in our patients with tako-tsubo syndrome was longer overall, and its recurrent diaphragmatic segment was longer, than in controls. To compare these groups we designed a measure termed recurrent segment index (left anterior descending recurrent segment length/total left anterior descending length  $\times 100$ ). In tako-tsubo syndrome this index was 22.3 (1.5)%, vs 10.9 (6.7)% in normal controls ( $P < .001$ ), and 11.3 (7.7)% in acute myocardial infarction patients ( $P < .001$ ). Patients with acute myocardial infarction and a high recurrent segment index ( $\geq 16\%$ ) had ventriculographic findings of systolic apical ballooning identical to those in patients with tako-tsubo syndrome.

**Conclusions.** All our patients with tako-tsubo syndrome had a left anterior descending with a long recurrent segment. The identical ventriculographic findings in patients with tako-tsubo syndrome and those with acute myocardial infarction with a long recurrent segment may be due to a common etiology.

**Key words:** *Myocardial stunning. Coronary disease. Myocarditis.*

SEE EDITORIAL ON PAGES 194-7

Correspondence: Prof. J. Farré.  
Servicio de Cardiología. Fundación Jiménez Díaz.  
Avda. Reyes Católicos, 2. 28040 Madrid. España.  
E-mail: jfarre@telefonica.net

Received 19 September, 2003.  
Accepted for publication 1 December, 2003.

Full English text available at: [www.revespcardiol.org](http://www.revespcardiol.org)

**Asociación del síndrome tako-tsubo con la arteria coronaria descendente anterior con extensa distribución por el segmento diafragmático**

**Introducción y objetivos.** El síndrome de disfunción ventricular transitoria tako-tsubo ha sido descrito en Japón y se han publicado casos aislados en Occidente. Mostramos una de las primeras series descritas fuera de Japón y presentamos nueva información sobre su anatomía coronaria.

**Pacientes y método.** Entre enero de 1998 y abril de 2003 identificamos a 11 pacientes con sospecha de infarto agudo de miocardio, arterias coronarias normales y disfunción ventricular transitoria tipo tako-tsubo. Estudiamos la anatomía coronaria de estos 11 pacientes, así como de 44 controles ajustados por edad y sexo: 22 con coronarias normales y 22 con infarto agudo de miocardio en relación con oclusión en la arteria coronaria descendente anterior.

**Resultados.** Al igual que en los pacientes japoneses, el síndrome tako-tsubo en pacientes caucásicos generalmente ocurre en mujeres en la séptima u octava décadas de la vida y con frecuencia se precede de estrés emocional o físico. La arteria coronaria descendente anterior de nuestros pacientes con síndrome tako-tsubo tiene mayor longitud y un segmento diafragmático (recurrente) más largo que la de los controles. Para compararlos diseñamos un índice de recurrencia ([segmento recurrente de descendente anterior/longitud total de la descendente anterior]  $\times 100$ ). En los pacientes con síndrome tako-tsubo, este índice fue del  $22,3 \pm 1,5\%$ , en controles normales fue del  $10,9 \pm 6,7\%$  ( $p < 0,001$ ) y en los pacientes de control con infarto del  $11,3 \pm 7,7\%$  ( $p < 0,001$ ). Los pacientes de control con infarto presentaban una ventriculografía idéntica a la de los enfermos con síndrome tako-tsubo cuando su índice de recurrencia era alto ( $\geq 16\%$ ).

**Conclusiones.** Todos nuestros pacientes con síndrome tako-tsubo presentan una descendente anterior con un gran segmento recurrente. La morfología idéntica de la ventriculografía de los pacientes con síndrome tako-tsubo y los controles con infarto con un elevado índice de recurrencia de la descendente anterior puede deberse a una etiopatogenia común.

**Palabras clave:** *Aturdimiento miocárdico. Enfermedad coronaria. Miocarditis.*

## ABBREVIATIONS

LAD: left anterior descending coronary artery.

ECG: electrocardiogram.

AMI: acute myocardial infarction.

ACS: acute coronary syndrome.

LV: left ventricle.

## INTRODUCTION

In Japan, a new clinical disorder characterized by extensive akinesia with ballooning without significant coronary lesions has recently been described.<sup>1-4</sup> Patients present chest pain, electrocardiographic (ECG) changes and slight enzyme level elevation similar to patients presenting acute myocardial infarction (AMI) or other forms of acute coronary syndrome (ACS). Sato et al<sup>1</sup> first described this disorder in 1990 and proposed the term *tako-tsubo-like left ventricular dysfunction* due to the shape taken by the left ventricle (LV). Angiograms showed extensive systolic LV ballooning taking the form of a container traditionally used in Japan to catch octopus and known as a *tako-tsubo* (Figura 1A).<sup>1,2</sup> The condition has a benign prognosis and segment changes affecting contractility recover in a few weeks. Typically, the disorder affects older women with few cardiovascular risk factors and is frequently triggered by emotional or physical stress.<sup>1-6</sup> Acute phase ECG changes involve ST segment elevation mainly along the anterolateral surface with pathologic Q waves that evolve with the appearance of negative T waves and Q wave regression. These changes suggest an ischemic event in anterolateral territory. The discovery of extensive LV apical akinesia has led several authors to discount the idea that the territory involved may correspond to a single coronary artery.<sup>1-3</sup>

Except for some isolated cases<sup>7-9</sup> and one recent European series,<sup>10</sup> all the series reported come from Japan.<sup>1-6</sup> Even though it is more than 10 years since research began, the etiology of the disorder is still unknown.

This study describes one of the first series of tako-tsubo-like ventricular dysfunction with ballooning from outside Japan. Based on the anatomy of the left anterior descending coronary artery (LAD) of our patients, we formulated a hypothesis as to the etiology of the entity.

## PATIENTS AND METHODS

Between January 1998 and April 2003 we identified 11 patients who fulfilled the following criteria: a) suspected ACS based on the presence of chest pain, ECG changes and enzyme elevation; b) transient tako-

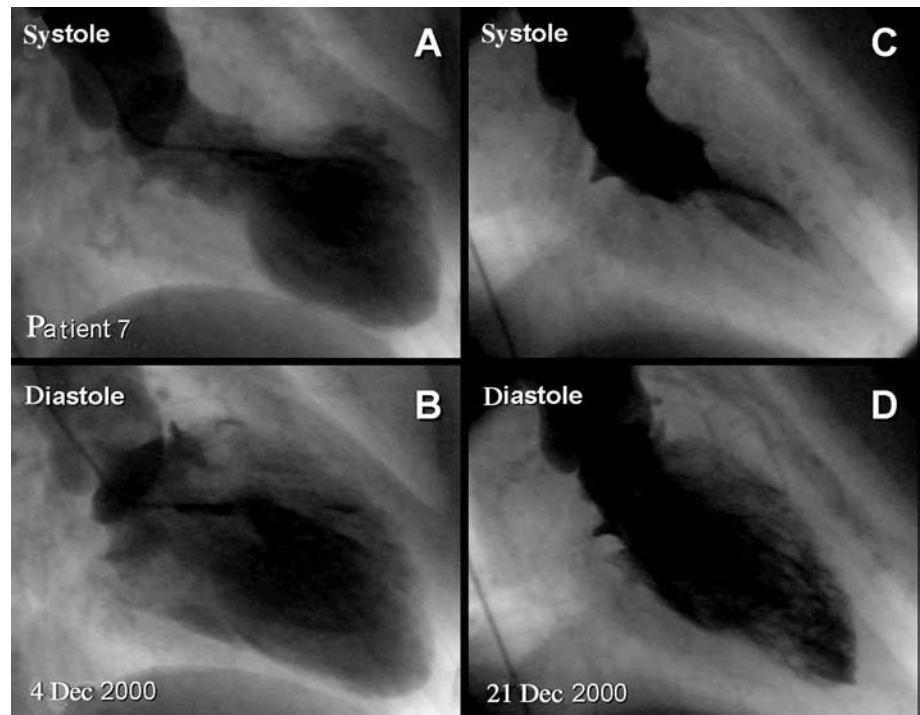
tsubo-like systolic ballooning found in angiograms and 2D echocardiograms of the LV and, and c) absence of significant coronary artery obstruction (no stenosis >50%) in the three principal coronary arteries. All patients underwent angiographic studies of the LV and coronary angiography, 21±12 h (range, 5-36 h) after the onset of symptoms (Figure 1 A and B). In all patients, anatomical characteristics of the epicardial coronary arteries were studied. To determine whether a single coronary artery could supply the entire akinetic course of the LV, we retrospectively analyzed the LV dimensions of patients. We measured LAD length (in mm) of the left lateral projection from the LAD ostium to the visible end of its course, tracing the route of the artery with Quantcor® 1.1 software (Pie Medical Imaging, Maastricht, Netherlands). We designated the apical point of the LAD as that which was furthest from the LAD ostium (Figure 2). We defined an LAD recurrent (diaphragmatic) segment as that part of the vessel between the apical point of the LAD and the visible end of the coronary artery (Figure 2). When the apical point of the LAD coincided with the visible end of the artery, we considered the patient lacked a recurrent segment. We calculated an LAD recurrent segment index using the following formula:

$$(\text{left anterior descending recurrent segment length} / \text{total left anterior descending length}) \times 100$$

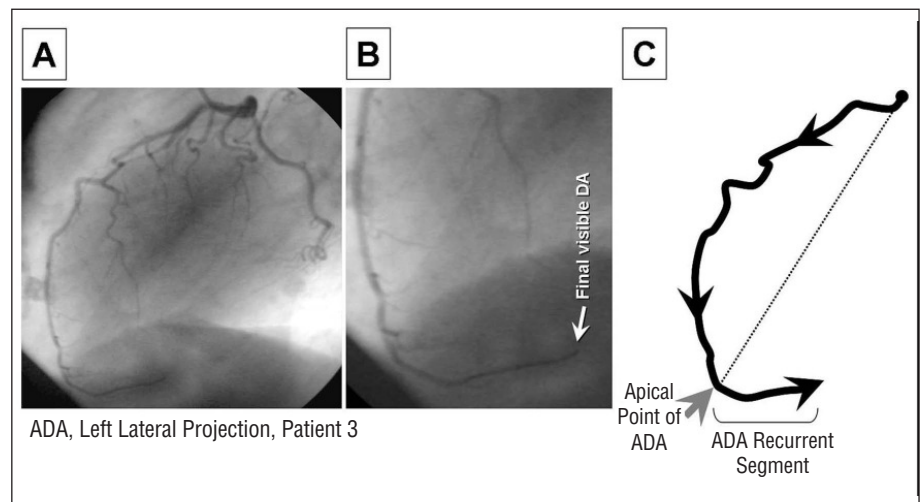
To determine whether patients had abnormally developed LAD recurrent segments we took the same measurements in 44 controls: 22 with chest pain without enzyme level elevation with normal coronary arteries, and 22 with AMI due to obstructive thrombus lesion in the LAD without evidence of lesions in other coronary arteries. The first control group was made up of patients with chest pain but without angiographic evidence of coronary heart disease, a characteristic they had in common with patients with tako-tsubo syndrome. The second control group was enrolled on the assumption that patients with tako-tsubo syndrome are initially diagnosed with suspected anterior wall AMI. In order to match controls to patients with tako-tsubo syndrome, we searched our database retrospectively and enrolled consecutive women patients of 60-80 years who met the control group criteria. Each control group included twice as many patients as those enrolled in the tako-tsubo group.

Enzyme levels were determined on admission and every 8 hours until peak values had been recorded. Creatine kinase (CK) >220 UI/L was considered pathologic. Troponin I (TnI) was determined in 4 patients and troponin T (TnT) in the other 7. Levels of TnI>0.6 ng/mL and TnT>0.1 ng/mL were considered pathologic. In 3 patients, viral antibody titers were evaluated in the first 24 h and 2 weeks after the onset of symptoms.

**Figure 1.** Images of systole and diastole in left ventriculogram in right anterior oblique projection of patient 7 obtained at 5 h (A and B) and at 17 days after the onset of the symptoms (C and D), respectively. Detail of systolic ballooning (A) and of the complete normalization of systolic function 2 1/2 weeks after admission.



**Figure 2.** A: left lateral projection of the left coronary artery of patient 3. B: amplified view of the same image to show more clearly the recurrent segment of the anterior descending artery (ADA) and its visible end. C: sketch of the ADA as it appears in A, indicating the apical point of the LAD and the recurrent segment.



A 12-lead ECG was performed on admission and every 8 hours during the first 3 days. Later, patients underwent daily ECGs until discharge (Figure 3). All patients had a 2D echocardiogram on admission and weekly thereafter (Figure 4). One patient in the tako-tsubo group underwent a second angiographic study 17 days after admission (Figure 1C and D). In the other 10 patients, changes in global and segmental ventricular function were recorded by 2D echocardiogram (Figure 4).

### Statistical Analysis

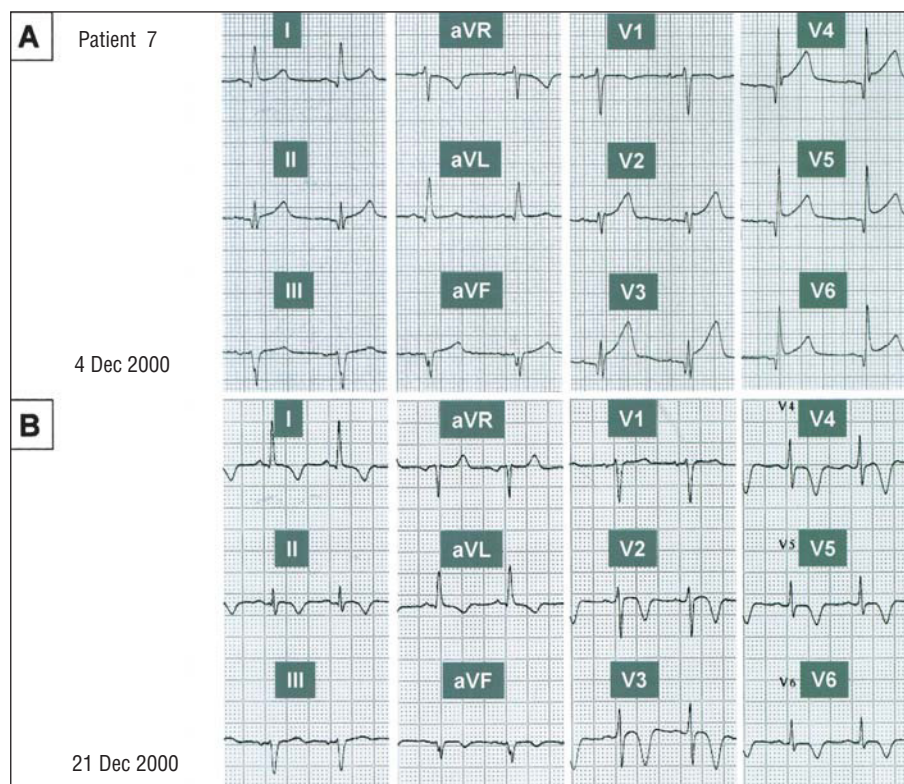
Continuous variables are expressed as

mean±standard deviation (SD). Ejection fraction in acute and subacute phases was compared with the Wilcoxon test for paired data. Tako-tsubo patients and controls were compared for total LAD length, LAD recurrent segment length and LAD recurrent segment index using the Mann-Whitney U test for non-paired data. Statistical significance was set at  $P<.05$ .

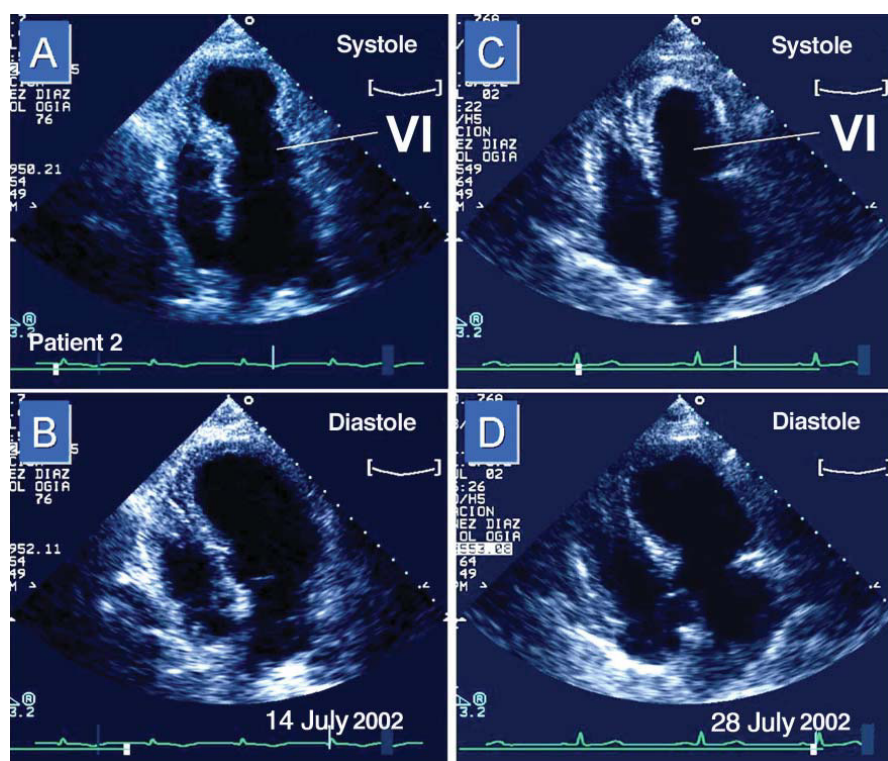
### RESULTS

Clinical characteristics of patients with tako-tsubo syndrome (n=11) appear in Table 1. Patients were white and 9 of them (82%) were women. Average age was  $72\pm12$  years (range, 41-84 years). Ten patients





**Figure 3.** Patient 7, the same patient as in Figure 1. A: ECG on admission and 17 days after the onset of symptoms (B). In the initial ECG, note the presence of Q waves in leads I, II, aVL, and in leads V3 to V6. ST segment is elevated in leads I, II, III, aVL, aVF, and in leads V2 to V6. B: ECG prior to discharge. The Q waves are very faint in leads I and aVL and can no longer be seen in leads V3 to V6. T wave is inverted in leads I, II, aVL, aVF, and in V2 to V6.



**Figure 4.** 2D echocardiogram (apical axis of 4-chambers) of patient 2. A and B: systole and diastole in the acute phase (10 h after the onset of the symptoms), respectively. C and D: study performed 14 days after admission. Ballooning, which is clearly shown in image A, disappears at 2 weeks after the acute phase (C).

were admitted for suspected angina (91%) and 1 patient presented at the Emergency Room after fainting; 6 patients (55%) reported suffering physical

or emotional stress prior to the onset of symptoms.

On admission, ECG findings for all patients showed ST segment elevation  $\geq 1$  mm in more than 3

TABLE 1. Characteristics of Patients With Tako-Tsubo Syndrome

Patient	Age	Gender	High Blood Pressure	Diabetes	Hypercholesterolemia	Tobacco	Prior Stress	Reason for Attending Clinic
1	82	F	+	—	—	—	Physical	Syncope
2	76	F	—	—	+	—	Emotional	Chest pain
3	70	F	+	—	+	—	—	Chest pain
4	81	F	+	—	—	—	—	Chest pain
5	41	M	—	—	+	—	—	Chest pain
6	67	F	+	—	—	—	Emotional	Chest pain
7	70	F	+	—	—	—	Emotional	Chest pain
8	75	F	—	—	—	—	Physical	Chest pain
9	77	F	—	—	—	—	Physical	Chest pain
10	71	F	+	+	—	—	—	Chest pain
11	84	M	+	—	+	—	—	Chest pain

consecutive leads, especially V3 to V6, and lead I (Figure 3A). During hospitalization, markedly negative T waves developed in 9 patients (82%), particularly in leads V2 to V6, and lead I (Figure 3B). In these patients, negative T waves were still present on discharge at  $15 \pm 10$  days (range, 5-35). In the other 2 patients, ST segment recovered without developing negative T waves. Peak CK value was  $272 \pm 227$  UI/L (range, 126-889) but only 4 patients (36%) presented values above the normal range. All 11 patients had high TnI or TnT values (mean, TnT,  $0.46 \pm 0.3$  ng/mL [range, 0.2-1.2] and mean TnI,  $4.0 \pm 2.6$  ng/mL [range, 1.6-7.47]). Viral antibody titers against enterovirus, ECHO virus, *Coxsackie* virus, influenza A and influenza B were normal in those patients analyzed.

On admission, all 11 patients presented akinesia with ballooning in 2D echocardiograms (Figure 4). Left ventriculograms performed at  $21 \pm 12$  hours (range, 5-36) after the onset of symptoms showed tako-tsubo-like apical akinesia, a form of left ventricular systolic dysfunction characterized by extensive apical akinesia with normal or hypercontractile baseline segments (Figure 1). In all patients, serial echocardiograms showed left ventricular systolic function recovery at  $13 \pm 8$  days (range, 3-31) (Figure 4). One patient underwent a coronary angiogram that confirmed normal LV contractility (Figure 1). Left ventricular ejection fraction on admission was  $37\% \pm 9\%$  (range, 20%-50%) whereas on discharge it was  $64\% \pm 9\%$  (range, 58%-75%;  $P=.003$ ). All patients with tako-tsubo-like disorder underwent early coronary angiograms that showed an absence of epicardial coronary lesions  $>50\%$  in the 3 principal coronary arteries.

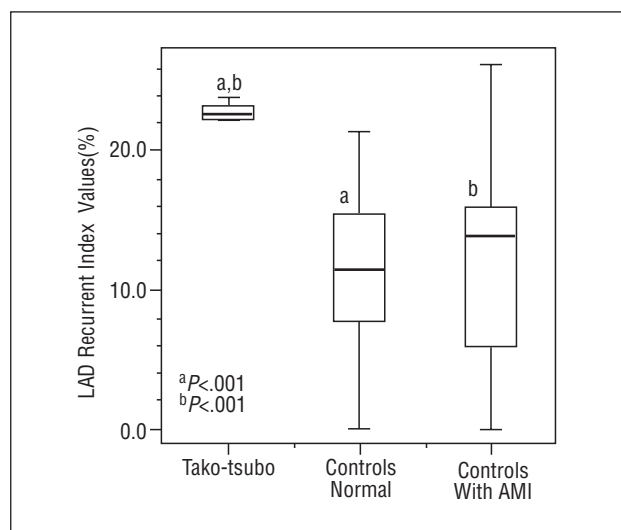
### Dimensions of the left anterior descending coronary artery

Total LAD length in patients with tako-tsubo-like disorder was  $133.0 \pm 13.4$  mm (range, 110.8-147.4) versus  $113.6 \pm 15.4$  mm (range 78.3-144.9) in controls

with normal coronary arteries ( $P=.004$ ) and  $105.9 \pm 20.0$  mm (range, 67.9-137.4) in controls with AMI and a single LAD lesion ( $P=.001$ ). In all 11 patients with tako-tsubo syndrome, the LAD around the LV apex extended along the diaphragmatic surface of the LV (Figure 2). We also found an LAD recurrent segment in 18 of the 22 controls with normal arteries (82%) and in 18 of the 22 controls with AMI with a single LAD lesion (82%). However, LAD recurrent segment length in patients with tako-tsubo syndrome was  $29.6 \pm 3.6$  mm (range, 24.8-34.9) versus  $13.0 \pm 8.5$  mm (range, 0-26.8) in controls with normal coronary arteries ( $P<.001$ ) and  $12.9 \pm 9.4$  mm (range, 0-31.4) in controls with AMI ( $P<.001$ ). Moreover, LAD recurrent index was  $22.3\% \pm 1.5\%$  (range, 18.7%-23.8%) in patients with tako-tsubo syndrome,  $10.9\% \pm 6.7\%$  (range, 0%-21.4%) in controls with normal coronary arteries ( $P<.001$ ) and  $11.3\% \pm 7.7\%$  (range, 0%-26.2%) in controls with AMI ( $P<.001$ ; Figure 5 and Table 2). If we exclude patients without recurrent segment, LAD recurrent segment index in patients with tako-tsubo syndrome was greater than in the control groups ( $22.3\% \pm 1.5\%$  vs  $13.3\% \pm 4.6\%$  and  $13.8\% \pm 6.0\%$ , respectively;  $P<.001$  for both comparisons).

### Left ventriculogram in patients with tako-tsubo syndrome and in controls with AMI and single LAD lesion

By definition, patients with tako-tsubo syndrome had extensive LV apical akinesia with tako-tsubo-like systolic ballooning (Figure 1). In contrast, only 4 of the 22 patients (18%) with AMI and a single LAD lesion presented ballooning (Figure 6). These 4 patients had LAD recurrent indices of 16%, 19%, 19%, and 26%, respectively ( $22.0\% \pm 4.4\%$ ). The remaining 18 controls in this group had LAD recurrent indices  $<16\%$  ( $8.0\% \pm 6.0\%$ ).



**Figure 5.** LAD recurrent index values (mean±SD) in patients with tako-tsubo syndrome and both control groups (see text for further details).

## DISCUSSION

We have presented one of the first series of tako-tsubo-like ventricular dysfunction described in white patients. Our study compares the epicardial coronary anatomy of patients with tako-tsubo syndrome with that of patients with normal coronary arteries and patients with AMI and a single LAD lesion. Patients with tako-tsubo syndrome all had long LAD extending beyond the apex along the diaphragmatic segment of the left ventricle (recurrent segment). This recurrent segment was longer in patients with tako-tsubo syndrome than in control groups. Moreover, ballooning, present in all patients with tako-tsubo syndrome, was identified in controls with AMI and a single LAD lesion only when the LAD recurrent index was high (in this series,  $\geq 16\%$ ).

Since Sato et al described tako-tsubo syndrome in 1990,<sup>1</sup> many retrospective studies carried out in Japan have been published.<sup>2-6</sup> Clinical, biochemical, electrocardiographic and ventriculographic aspects of the disorder are well documented and our data coincide with those reported for Japanese patients. Consequently, our series shows the disorder is not unique to the Japanese and confirms results of the

Belgian study reported by Desmet et al.<sup>10</sup>

Tako-tsubo syndrome is generally agreed to be a form of myocardial stunning but the etiology is as yet unknown. One hypothesis suggests we are dealing with an acute myocarditis. However, Kurisu et al<sup>3</sup> report negative results in endomyocardial biopsies (3 patients) and viral antibody titers (7 patients) that indicate this is unlikely. Abe et al<sup>6</sup> did not find a rise in viral antibody titers in 6 patients with tako-tsubo syndrome and in endomyocardial biopsies they found interstitial fibrosis in specimens taken from all 6 patients with slight inflammatory cell infiltration in 3 of them. These changes were not considered compatible with a diagnosis of myocarditis. We did not find a rise in viral antibody titers in any of the 3 patients analyzed.

Previous research has pointed to the direct toxic effect of catecholamine as a possible cause of symptoms. The fact that the disorder is frequently preceded by stress (in our series, 55% of patients presented physical or emotional stress) implies that the adrenergic system may sometimes be involved in the pathology of the disorder. However, in the only series in which noradrenalin plasma values have been recorded,<sup>3</sup> titers were normal or slightly raised in the 6 patients analyzed. This issue needs to be resolved in future studies.

Another hypothesis is that of coronary artery spasm. Results of provocative testing with acetylcholine were only positive in 21% of patients.<sup>4</sup> Transient dynamic obstruction of LV outflow tract has also been suggested as a possible cause. However, Abe et al<sup>6</sup> reported that none of the patients in their series presented a significant intraventricular gradient ( $>30$  mm Hg) and Tsuchihashi et al<sup>4</sup> found only 18% of patients in their series presented transient intraventricular gradient.

Authors who have studied tako-tsubo syndrome in series of patients agree that the behavior of the ventricular dysfunction and the rapid recovery coincide with developments observed in patients with myocardial stunning. The most frequent cause of myocardial stunning is atherosclerosis.<sup>11</sup> The absence of significant coronary artery stenosis in patients with tako-tsubo syndrome does not exclude transient coronary artery obstruction as a possible cause. The discovery that all

**TABLE 2. Dimensions of Left Anterior Descending Coronary Artery in Patients With Tako-Tsubo Syndrome and in Controls\***

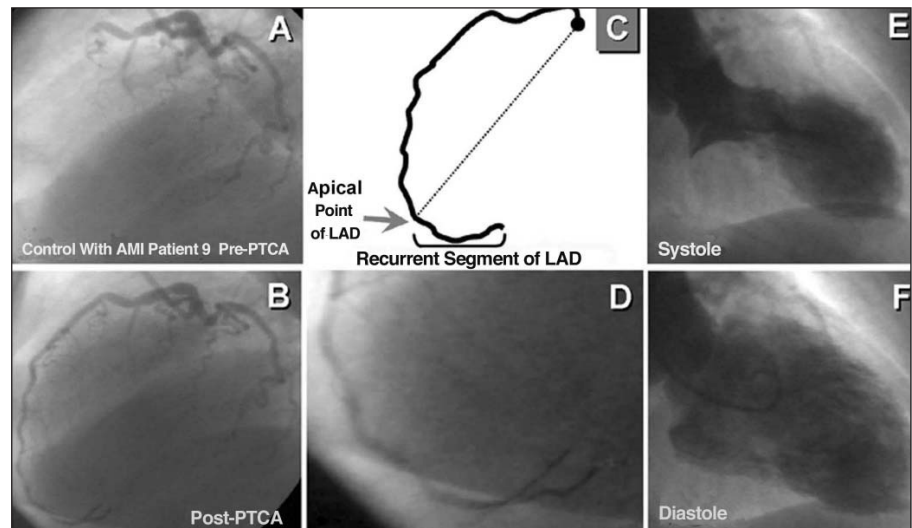
	Tako-Tsubo (n=11), Mean±SD (range)	Controls N (n=22), Mean±SD (Range)	Controls AMI (n=22), Mean±SD (Range)
Total length of LAD, mm	133±13.4 (110.8-147.4)	113.6±15.4 (78.3-144.8)	105.9±20.0 (67.8-137.4)
Length of recurrent segment, mm	29.6±3.6 (24.8-34.9)	13.0±8.5 (0-26.8)	12.9±9.4 (0.0-31.4)
LAD recurrent index, %	22.3±1.5 (18.7-23.8)	10.9±6.7 (0-21.4)	11.3±7.7 (0-26.2)
LAD recurrent index, %†	22.3±1.5 (18.7-23.8)	13.3±4.6 (6.1-21.4)	13.8±6.0 (3.5-26.2)

\*LAD indicates left anterior descending coronary artery; controls N, controls with normal coronary arteries; AMI, acute myocardial infarction.

†Excluding those patients without recurrent segment (controls with normal coronary arteries, n=18; controls with AMI, n=18).



**Figure 6.** A and B: left lateral projection of LAD in patient 9, control with AMI, before and after angioplasty with stent. C: sketch of LAD as it appears in B, indicating the apical point of the artery and recurrent segment. D: improved expanded view of the same image of LAD recurrent segment and its visible end. E and F: systole and diastole of left ventriculogram in oblique anterior right projection in the same control patient. PTCA indicates percutaneous transluminal coronary angioplasty.



patients in our series presented a marked LAD recurrent segment with a long course along the diaphragmatic surface of the LV leads us to suggest that a coronary event in the LAD may produce extensive apical akinesia along the LV diaphragmatic surface. This was found in patients with AMI with a significant LAD lesion with long course diaphragmatic segment as we have seen in controls with LAD recurrent index  $\sim 16\%$ . The existence of AMI in patients with normal coronary arteries is well known.<sup>12,13</sup> Even though the etiology of AMI with normal coronary arteries is unknown, it has been suggested as a possible cause of transient coronary thrombosis (eventually related to spasm).<sup>14</sup> The proportion of patients with AMI and normal coronary arteries is  $1\pm 6\%$ .<sup>15</sup> As occurs in patients with tako-tsubo syndrome, patients with AMI and normal coronary arteries frequently present few cardiovascular risk factors; however, they are usually young.

### LAD Anatomy in Patients With Tako-Tsubo Syndrome Compared With Controls

In all our patients with tako-tsubo syndrome, the LAD followed a long course after the apex of the LV and consequently supplied a large part of the diaphragmatic surface of the LV. In series of patients with normal hearts, 72% and 90% of patients, respectively, had an LAD recurrent segment.<sup>6,17</sup>

In our study, 82% of controls with normal coronary arteries and 82% of controls with AMI had an LAD recurrent segment. In patients with tako-tsubo syndrome, both the LAD and LAD recurrent segment were longer than in controls.

### Implications for the Etiology of the Entity

Our findings on the existence of a longer LAD recurrent segment do not mean that this anatomical variation predisposes individuals to suffer this disorder. In fact, when an obstructive thrombus occurs in long LAD recurrent segment (in our series  $\geq 16\%$ ), the left ventriculogram also shows a type of akinesia that is identical to that of patients with tako-tsubo syndrome (Figure 6). In these patients, apical akinesia is permanent, whereas in patients with tako-tsubo syndrome it is transient. If an LAD obstruction is resolved within a few hours of the onset of symptoms (due to spasm or spontaneous thrombolysis) before an angiographic study is conducted, the patient may be diagnosed with tako-tsubo syndrome. Tako-tsubo-like transient ventricular dysfunction syndrome may be caused by a prolonged obstruction of the thrombus that is spontaneously resolved in patients with a long LAD and long course along the diaphragmatic surface of the LV.

### Limitations of the Study

This study involved relatively few patients with tako-tsubo syndrome and our findings about LAD recurrent segment length need to be confirmed in larger series. Larger series of patients are also needed if we are to establish a cutoff point for LAD recurrent segment index at which an obstructive thrombus of this type can produce a ventriculogram with tako-tsubo-like morphology.

### CONCLUSIONS

This series describes Spanish patients with tako-tsubo syndrome, or transient ventricular dysfunction

with ballooning, and confirms that the entity is not exclusively found in Japanese patients. In all of our patients, the LAD supplies a large part of the diaphragmatic territory of the LV. When patients with AMI and a single obstructive thrombus in the LAD had an LAD recurrent index  $\geq 16\%$ , the left ventriculogram showed a morphology indistinguishable from that of tako-tsubo syndrome. The LAD recurrent index in our 11 patients with tako-tsubo syndrome was  $\geq 16\%$ . Although the etiology of tako-tsubo-like ventricular dysfunction is still unknown, our findings are compatible with a common etiology of tako-tsubo syndrome and acute myocardial infarction.

## REFERENCES

1. Sato H, Tateishi H, Uchida T, Dote K, Ishihara M, Sasaki K. Tako-tsubo-like left ventricular dysfunction due to multivessel coronary spasm. In: Kodama K, Haze K, Hori M, editors. Clinical aspect of myocardial injury: from ischemia to heart failure (in Japanese). Tokyo: Kagakuhyoronsha Publishing Co., 1990; p. 56-64.
2. Dote K, Sato H, Tateishi H, Uchida T, Ishihara M. Myocardial stunning due to simultaneous multivessel coronary spasms: a review of 5 cases. *J Cardiol* 1991;21:203-14.
3. Kurisu S, Sato H, Kawagoe T, Ishihara M, Shimatani Y, Nishioka K, et al. Tako-tsubo-like left ventricular dysfunction with ST-segment elevation: a novel cardiac syndrome mimicking acute myocardial infarction. *Am Heart J* 2002;143:448-55.
4. Tsuchihashi K, Ueshima K, Uchida T, Oh-mura N, Kimura K, Owa M, et al. Transient left ventricular apical ballooning without coronary artery stenosis: a novel heart syndrome mimicking acute myocardial infarction. Angina Pectoris-Myocardial Infarction Investigations in Japan. *J Am Coll Cardiol* 2001;38:11-8.
5. Kurisu S, Inoue I, Kawagoe T, Ishihara M, Shimatani Y, Nishioka K, et al. Myocardial perfusion and fatty acid metabolism in patients with tako-tsubo-like left ventricular dysfunction. *J Am Coll Cardiol* 2003;41:743-8.
6. Abe Y, Kondo M, Matsuoka R, Araki M, Dohyama K, Tanio H. Assessment of clinical features in transient left ventricular apical ballooning. *J Am Coll Cardiol* 2003;41:737-42.
7. Peraira Moral JR, Segovia Cubero J, Oteo Domínguez JF, Ortiz Oficialdegui P, Fuentes Manso R, Martín Júdez V. Síndrome de discinesia apical transitoria con una complicación inhabitual. *Rev Esp Cardiol* 2002;55:1328-32.
8. Pavin D, Le Breton H, Daubert C. Human stress cardiomyopathy mimicking acute myocardial syndrome. *Heart* 1997;78:509-11.
9. Villareal RP, Achari A, Wilansky S, Wilson JM. Anteroapical stunning and left ventricular outflow tract obstruction. *Mayo Clin Proc* 2001;76:79-83.
10. Desmet WJ, Adriaenssens BF, Dens JA. Apical ballooning of the left ventricle: first series of white patients. *Heart* 2003;89:1027-31.
11. Kloner RA, Bolli R, Marban E, Reinlib L, Braunwald E. Medical and cellular implications of stunning, hibernation, and preconditioning: an NHLBI workshop. *Circulation* 1998;97:1848-67.
12. Da Costa A, Isaz K, Faure E, Mourot S, Cerisier A, Lamaud M. Clinical characteristics, aetiological factors and long-term prognosis of myocardial infarction with an absolutely normal coronary angiogram: a 3-year follow-up study of 91 patients. *Eur Heart J* 2001;22:1459-65.
13. Ammann P, Marschall S, Kraus M, Schmid L, Angehrn W, Krapf R, et al. Characteristics and prognosis of myocardial infarction in patients with normal coronary arteries. *Chest* 2000;117:333-8.
14. Raymond R, Lynch J, Underwood D, Leatherman J, Razavi M. Myocardial infarction and normal coronary arteriography: a 10 year clinical and risk analysis of 74 patients. *J Am Coll Cardiol* 1988;11:471-7.
15. DeWood MA, Spores J, Notske R, Mouser LT, Burroughs R, Golden MS, et al. Prevalence of total coronary occlusion during the early hours of transmural myocardial infarction. *N Engl J Med* 1980;303:897-902.
16. Perlmutter LM, Jay ME, Levin DC. Variations in the blood supply of the left ventricular apex. *Invest Radiol* 1983;18:138-40.
17. Reig J, Jornet A, Petit M. Patterns of the coronary artery irrigation in the left ventricle. *Surg Radiol Anat* 1993;15:309-14.