

Table 2
Procedure-Related Characteristics

Radial access	124 (89.2)
Culprit artery	
Anterior descending	52 (37.4)
Right coronary	66 (47.5)
Circumflex	20 (14.4)
Baseline TIMI	
TIMI 0-1	115 (82.7)
TIMI 2-3	24 (17.3)
Total lesion length, mm	22.6±8.7
Number of stents per patient	
1	106 (76.3)
2	28 (20.1)
3	5 (3.6)
Maximum lesion diameter, mm	3.1±0.4
Direct stent	75 (54)
Thrombus aspiration	80 (57.6)
Final TIMI	
TIMI 3	134 (96.5)
TIMI 1-2	4 (3.6)
No reflux	9 (6.5)
Angiographic complications*	18 (12.9)

TIMI, thrombolysis in myocardial infarction.

Data are expressed as mean±standard deviation or no. (%).

* Distal embolization, lateral branch occlusion, dissection, or perforation.

Based on the criteria of the Academic Research Consortium, there were 2 definite cases of thrombosis during follow-up (1.4%), one occurring during hospitalization and the other at 7 months following the procedure in a patient who had temporarily discontinued antiplatelet therapy.

Clinical restenosis occurred in 5% of cases, a new TVR was required in 5.8%, and target lesion revascularization (TLR) was needed in 3.8%.

Primary angioplasty is the treatment of choice in patients with STEAMI. Nonetheless, the choice of stent type remains controversial. Although it has been demonstrated that drug-eluting stents (DESs) effectively reduce restenosis, they can delay remodeling, a factor that has been related to thrombosis, particularly in high-risk situations, such as STEAMI.² In a study by Planas et al.,³ 8.6% of the patient group treated with DESs required TLR, a higher rate than was documented in our study. This difference may be related to the fact that the patients in that study underwent angiographic follow-up studies at 6 and 12 months, which could increase the indication for coronary interventions.

Few studies have been performed with the Genous® stent in primary angioplasty. In the registry carried out by Lee et al.,⁴ which contained 321 patients, definite thrombosis was reported in 0.9%

and the total mortality rate was 5.8%. The most relevant finding of Lee's study was that there was no increase in the number of late thrombosis cases despite the use of dual antiplatelet therapy for 1 month. More recently, Low et al.⁵ reported a binary restenosis rate of 28% and lumen loss of 0.82 mm in a study including 95 patients with angiographic follow-up at 6 and 12 months. These values are higher than those obtained in our study and, again, can be related to a higher indication for coronary interventions in patients under angiographic follow-up.

In a comparison with other devices used in STEAMI cases, a study by Chong et al.⁶ showed that the Genous® stent was a comparable alternative to conventional stents and DESs; no significant differences were found in terms of TVR, non-fatal myocardial infarction, or long-term major cardiac events.

The Genous® stent seems to be a safe, effective option in STEAMI patients because of low associated rates of thrombosis and TLR. However, additional comparative studies with currently available devices are needed.

Melisa Santas-Alvarez,* Diego Lopez-Otero, Ana B. Cid-Alvarez, Pablo Souto-Castro, Ramiro Trillo-Nouche, and Jose R. Gonzalez-Juanatey

Departamento de Cardiología Intervencionista, Hospital Clínico de Santiago de Compostela, Santiago de Compostela, A Coruña, Spain

* Corresponding author:

E-mail address: melisasantas@hotmail.com (M. Santas-Alvarez).

Available online 5 December 2011

REFERENCES

- Mioglionico M, Patti G, D'Ambrosio A, Di Sciascio G. Percutaneous coronary intervention utilizing a new endothelial progenitor cells antibody-coated stent: A prospective single-centre registry in high-risk patients. *Catheter Cardiovasc Interv.* 2008;71:600-4.
- Saia F, Lemos PA, Lee CH, Arampatzis CA, Hoyer A, Degertekin A, et al. Sirolimus-eluting stent implantation in ST-elevation acute myocardial infarction: a clinical an angiographic study. *Circulation.* 2003;108:1927-9.
- Planas-del Viejo AM, Pomar-Domingo F, Vilar-Herrero JV, Jacas-Osborn V, Nadal-Barangé M, Pérez-Fernández E. Resultados clínicos y angiográficos tardíos de stents liberadores de fármacos en pacientes con infarto agudo de miocardio con elevación del ST. *Rev Esp Cardiol.* 2008;61:360-8.
- Lee YP, Tay E, Lee CH, Low A, Teo SG, Poh KK, et al. Endothelial progenitor cell capture stent implantation in patients with ST-segment elevation acute myocardial infarction: one year follow-up. *Eurointervention.* 2010;5:698-702.
- Low A, Lee CH, Teo SG, Chan M, Tay E, Lee YP, et al. Effectiveness and safety of the Genous endothelial progenitor cell-capture stent in acute ST-elevation myocardial infarction. *Am J Cardiol.* 2011;108:202-5.
- Chong E, Poh KK, Liang S, Lee RCH, Low A, Teo S-G, et al. Two-year clinical registry follow-up endothelial progenitor cell capture stent versus sirolimus-eluting bioabsorbable polymer-coated stent versus bare metal stent in patients undergoing primary percutaneous coronary intervention for ST elevation myocardial infarction. *J Interv Cardiol.* 2010;23:101-8.

doi: 10.1016/j.rec.2011.09.021

Terminology Management for Implantable Cardiac Electronic Device Lead Macro-Dislodgement

Ordenación terminológica sobre macrodislocación de electrodos de dispositivos cardíacos electrónicos implantables

To the Editor,

Poor lead positioning of implantable electronic cardiac devices is rare and discovered incidentally on occasion, but can have

serious complications.¹ Dislodgement of correctly positioned leads is common, however, and can be a significant source of clinical complications for patients with these devices. Lead dislodgement may be an incidental, asymptomatic finding in certain patients, while in others it can cause a wide range of clinical problems. These include extracardiac stimulation, inappropriate therapies by automatic defibrillators, syncope, and heart failure due to loss of cardiac resynchronization in patients with biventricular pacing, possibly leading to death from asystole in patients completely dependent on pacing.

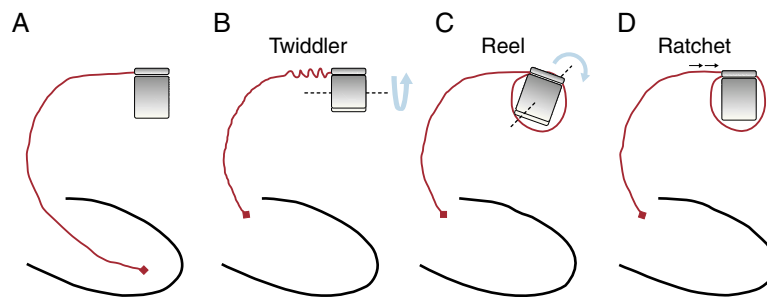


Figure 1. Mechanisms involved in lead macro-dislodgement of implantable devices. A, normal. B, twiddler syndrome. C, reel syndrome. D, ratchet syndrome.

Leaving aside injuries and iatrogenic conditions, several syndromes of lead macro-dislodgement have been described and cover the usual causes of lead dislodgement, namely, twiddler, reel, and ratchet syndromes.²⁻⁴ Although the problem is relevant, the terminology is confusing, perhaps because these terms were originally taken from individual case reports in the literature. Identical cases have been defined and classified differently by the authors and, conversely, different cases have been classified as identical. Some cases initially described as twiddler syndrome are actually forms of reel syndrome, and some cases described as either of these entities are actually cases of ratchet syndrome.^{5,6} Therefore, it would be appropriate to provide precise definitions for each of the potential mechanisms, in order to enhance our understanding of the mechanisms involved in each patient and to identify predictors of the problem,

their consequences, and the frequency of actual presentation of each one.

Below we present a proposal for the precise definition and classification of these lead macro-dislodgement syndromes (Fig. 1):

Twiddler syndrome: Twiddler syndrome can be defined as lead retraction and dislodgement due to device generator rotation over the axis defined by the lead. Although external manipulation by the patient may make it easier for this to occur, it is not a necessary condition. As the generator rotates, the lead twists over itself, giving it a characteristic and definitive appearance (Fig. 2).

Reel syndrome: Reel syndrome can be defined as lead retraction and dislodgement due to generator rotation over its sagittal axis, which causes lead reeling above or below the

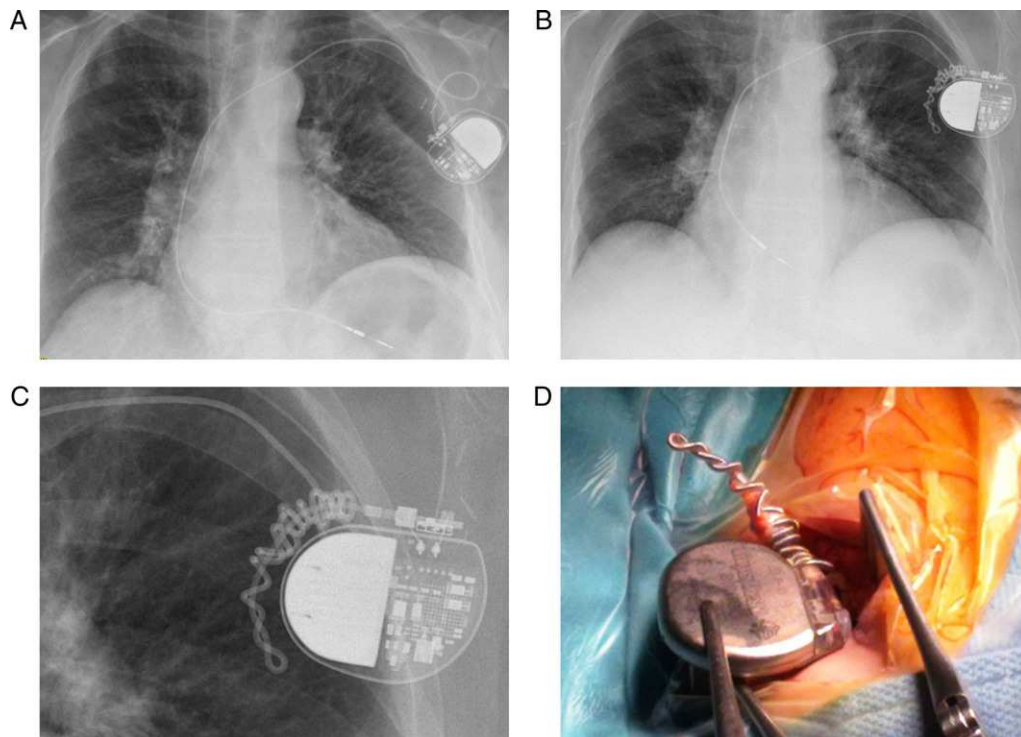


Figure 2. Example of twiddler syndrome in a 68-year-old patient who presented macro-dislodgement of the ventricular lead of a pacemaker implanted 2 months previously for atrial fibrillation with significant pauses. A, posteroanterior chest radiograph showing a normal lead position. B, posteroanterior chest radiograph showing lead macro-dislodgement and winding of the proximal portion over the long axis, due to generator rotation over the horizontal axis. C, detailed view of the proximal portion and generator in the radiograph. D, detailed view of the surgical revision of the system.

generator. Because of the mechanism involved in both twiddler and reel syndrome, all leads would be affected to some extent, in case of several leads.

Ratchet syndrome: Ratchet syndrome can be defined as lead retraction and dislodgement due to progressive lead displacement through its fixation parts or protector sleeves, facilitated by movements of the ipsilateral arm and due to incomplete lead fixation to the protector sleeve, but without generator rotation over any of its axes. In this case, the problem could involve all system leads in a patient or, more commonly, only one of the leads, with all others in normal position; this is a key finding for identifying ratchet syndrome and distinguishing it from the other 2 lead macro-dislodgement syndromes.

Prior to surgical revision of the system in the case of lead dislodgement, simple visualization of the lead(s) and radiographic visualization of the generator position, along with a comparison to the original implant position, will provide an approximate identification of the mechanism involved. For cases in which the evidence is not definitive, either because the system uses only 1 lead and there are no signs of any mechanism (eg, twisting) or because the generator is in its normal position and there are no lead abnormalities, it would be preferable to use the term "lead macro-dislodgement" alone.

We believe that the classification and management of the proposed definitions may be helpful to the clinician and to the physician implanting the device and would allow better characterization of this rather common complication in patients with implantable electronic cardiac devices.

Miguel A. Arias,* Marta Pachón, Alberto Puchol, Jesús Jiménez-López, Blanca Rodríguez-Picón, and Luis Rodríguez-Padial

Unidad de Arritmias y Electrofisiología Cardíaca, Servicio de Cardiología, Hospital Virgen de la Salud, Toledo, Spain

* Corresponding author:

E-mail address: maapalomares@secardiologia.es (M.A. Arias).

Available online 11 January 2012

REFERENCES

1. Feltes Guzmán GI, Vivas Balcones D, Pérez de Isla L, Zamorano Gómez JL. Malposición de catéter de marcapasos durante 9 años. Rol del ecocardiograma. *Rev Esp Cardiol.* 2011;64:250.
2. Carnero-Varo A, Pérez-Paredes M, Ruiz-Ros JA, Giménez-Cervantes D, Martínez-Corbalán FR, Cubero-López T, et al. "Reel Syndrome": a new form of Twiddler's syndrome? *Circulation.* 1999;100:e45-6.
3. Von Bergen NH, Atkins DL, Gingerich JC, Law IH. "Ratchet" syndrome, another etiology for pacemaker lead dislodgement: a case report. *Heart Rhythm.* 2007;4:788-9.
4. Benezet-Mazuecos J, Benezet J, Ortega-Carnicer J. Pacemaker twiddler syndrome. *Eur Heart J.* 2007;28:2000.
5. Bracke F, Van Gelder B, Dijkman B, Meijer A. Lead system causing twiddler's syndrome in patients with an implantable cardioverter-defibrillator. *J Thorac Cardiovasc Surg.* 2005;129:231-2.
6. Higgins SL, Suh BD, Stein JB, Meyer DB, Jons J, Willis D. Recurrent twiddler's syndrome in a nonthoracotomy ICD system despite a Dacron pouch. *Pacing Clin Electrophysiol.* 1998;21:130-3.

doi: 10.1016/j.rec.2011.09.025

Acute Myocardial Infarction for Thrombotic Occlusion in Patient With Elevated Coagulation Factor VIII

Infarto agudo de miocardio por oclusión trombótica en paciente con elevación del factor VIII de la coagulación

To the Editor,

We read with interest the article in the July issue of the *Revista Española de Cardiología* about hematologic diseases and the heart. We believe it would be appropriate to add elevated factor VIII (FVIII) as a risk factor for venous and arterial thrombotic events. For example, we present the case of a 45-year-old man with no cardiovascular risk factors who played sports regularly and had a body mass index of 23. He attended our hospital because of severe chest pain after cycling for 20 min. The electrocardiogram (ECG) showed ST elevation in leads V₂ to V₆, I, and aVL, and complete right bundle branch block. Fibrinolytic therapy was administered (7000 U of tenecteplase) for the first hour after onset of pain and he was transferred to our hospital. On arrival, he was asymptomatic and hemodynamically stable; the ECG showed normal ST segment with normal QS in leads V₂ to V₃ and negative T-waves in the precordial leads. Transthoracic echocardiography on admission revealed a dilated left ventricle, with a slightly depressed left ventricular ejection fraction (LVEF) of 38% and anteroseptal akinesia. At 23 h after onset, coronary angiography was performed, showing the presence of thrombotic material in the proximal segment of the left anterior descending artery, responsible for 40% obstruction with distal TIMI III flow. The remaining vessels were free of disease (Fig. 1). The physical examination was normal; laboratory tests showed troponin I levels of 57 ng/mL and peak creatine kinase of 2440 IU/L. The lipid profile, blood count,

and coagulation parameters were all normal. Given the lack of cardiovascular risk factors and the presence of arterial thrombosis, a hypercoagulation study was performed 48 h after admission to hospital. Fibrinogen, protein S, protein C, and antithrombin III levels were normal. Neither mutation of Leiden factor V nor lupus anticoagulant was detected. FVIII levels were elevated (234.2%; normal range, 50%-140%). The patient did not have a history of

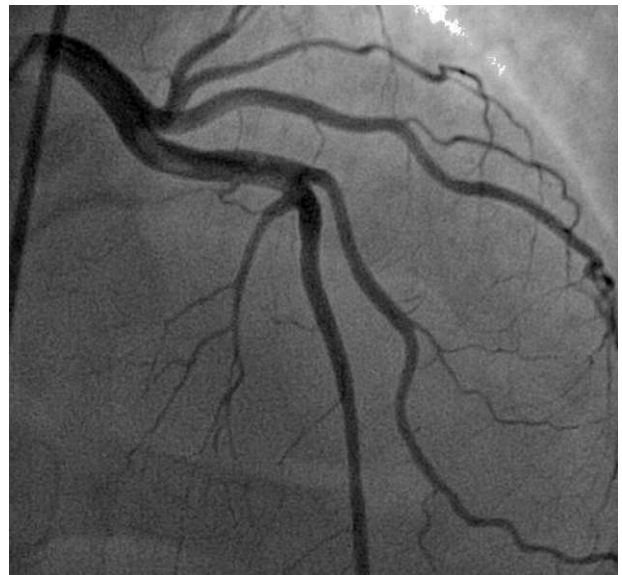

Figure 1. Coronary angiography. Anteroposterior cranial view: thrombus in proximal segment of the left anterior descending artery.