

Thrombectomy After Failed Fibrinolysis in Prosthetic Tricuspid Valve Thrombosis

To the Editor:

Prosthetic valve thrombosis is a complication basically related to mechanical prostheses and in the majority of cases is due to suboptimal anticoagulation. In addition, the use of mechanical prosthesis in the tricuspid position is limited by the high rate of prosthetic valve thrombosis due to the slower flow in the right heart cavities. It was traditionally considered that fibrinolysis was the treatment of choice in these cases.

We present the case of a tricuspid prosthetic valve thrombosis which was initially treated with fibrinolysis and then with surgical thrombectomy, since there was no observed improvement in the clinical and echocardiographic parameters.

The patient was a 56-year-old woman with Ebstein's anomaly who underwent a mechanical prosthesis implant St. Jude number 31. On the eleventh day post surgery she presented several episodes of resting presyncope with no evidence of electrocardiographic anomalies. In the 48 hours prior to this, oedemas appeared on the lower extremities with fovea and jugular ingurgitation. The prosthetic click was absent on auscultation. The patient was anticoagulated with acenocoumarol and presented an INR of 2.4.

The trans-thoracic echocardiogram showed abundant spontaneous echo contrast in the right atrium and the medial hemidisc was immobile. Through the Doppler, the flow of tricuspid filling presented a mean gradient of 21 mm Hg and a velocity of 2.5 m/s obtained in sinus rhythm. The study was completed with a transoesophageal echocardiogram, which confirmed these findings and also showed a thrombus of 12×13 mm on the lateral hemidisc (Figure 1).

Fibrinolysis was performed with rt-PA (10 mg in bolus followed by perfusion of 90 mg) and perfusion of sodium heparin. 24 hours later, the patient presented stable hypotension (90/40 mm Hg) and required high-flow oxygen therapy to maintain saturation. The helicoid computerised tomography excluded pulmonary thromboembolism.

A new echocardiographic control was carried out, with no variation with respect to the previous study, so the decision was made to intervene surgically. Inspection of the prosthesis during surgery revealed, a thrombus that surrounded the whole prosthetic ring and prevented movement of one of the hemidiscs. This was completely removed (Figure 2). The prosthesis was not replaced as it

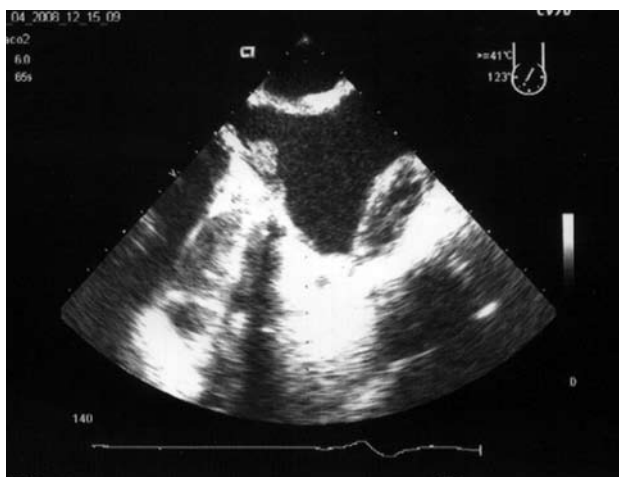


Figure 1. Transoesophageal echocardiogram showing a thrombus on the lateral hemidisc of the tricuspid valve prosthesis (shot from four cameras modified at 120° and with a maximum rotation towards the right).

was functioning correctly and no other thrombi were observed.

The serial control echocardiographs showed average prosthetic gradients of 3-4 mm Hg and good prosthesis opening. On discharge, the patient was administered acenocoumarol and 100 mg of acetylsalicylic acid.

There is a higher incidence of tricuspid prosthetic valve thrombosis compared with prostheses in mitral and/or aortic positions, with an annual published incidence of up to 20%-30% of the patients.¹ This greater presentation of tricuspid prosthetic valve thrombosis could be explained by the slower flow in the right cavities.¹ In any case, the most important aetiological factor is inadequate anticoagulation.¹ This is why most authors recommend adding low dose acetylsalicylic acid to the anticoagulant treatment.^{1,2}

The tricuspid prosthetic valve thrombosis is generally presented in an insidious form, with signs of right cardiac insufficiency, diastolic murmur and/or absence of prosthetic clicks.²

The diagnostic method of choice faced with suspected prosthetic valve thrombosis is the echocardiogram, especially through transoesophageal route, which also permits establishment of a differential diagnosis with other processes and, therefore, guides the therapeutic management.³

Fibrinolysis has been described as the treatment of choice for tricuspid prosthetic valve thrombosis with success rates of up to 80%. Although there are several norms with different fibrinolytic agents and varied doses, the efficacy of rt-PA has been demonstrated. It carries the advantage of having

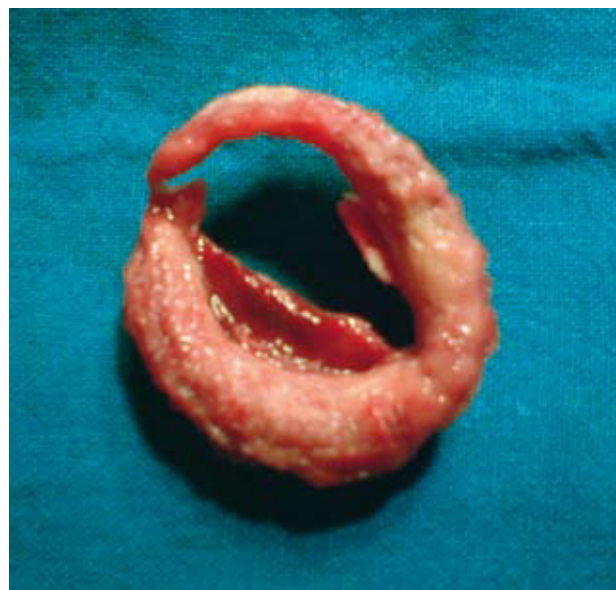

Figure 2. Organised thrombus reproducing the shape of the prosthetic ring.

less systemic deleterious effects, making it better in case of having to resort to surgery due to failure of the thrombolysis.⁴

Both the prosthetic replacement as well as the thrombectomy present high surgical risks, which can reach 38%-40% according to the published series. Therefore, surgical treatment is the next option when the fibrinolysis is not effective.⁵

Juan M. Lacal-Peña,^a Aníbal Bermúdez-García,^b
Roque Arana-Granado,^a and Tomás Daroca-Martínez^b

^aServicio de Cardiología, Hospital Universitario Puerta del Mar, Cádiz, Spain

^bServicio de Cirugía Cardíaca, Hospital Universitario Puerta del Mar, Cádiz, Spain

REFERENCES

1. Shapira Y, Sagie A, Jortner R, Adler Y, Hirsch R. Thrombosis of bileaflet tricuspid valve prosthesis: clinical spectrum and the role of no surgical treatment. *Am Heart J*. 1999;137:721-5.
2. Mehan VK, Dalvi BV, Kale PA. Thrombosed prosthetic valve in tricuspid position. Successful therapy with intravenous streptokinase. *Chest*. 1992;102:1599-600.
3. Bonow RO, Carabello BA, Chatterjee K, de Leon AC Jr, Faxon DP, Freed MD, et al. ACC/AHA 2006 guidelines for the management of patients with valvular heart disease. *J Am Coll Cardiol*. 2006;48:e1-95.
4. Vahanian A, Baumgartner H, Bax J, Butchart E, Dion R, Filippatos G, et al. Guía de práctica clínica sobre el tratamiento de las valvulopatías. Grupo de Trabajo sobre el Tratamiento de las Valvulopatías de la Sociedad Europea de Cardiología. *Rev Esp Cardiol*. 2007;60:e1-50.
5. Azpitarte J, Sánchez-Ramos J, Urda T, Vivancos R, Oyonarte JM, Malpartida F. Trombosis valvular protésica: ¿cuál es la terapia inicial más apropiada? *Rev Esp Cardiol*. 2001;54:1367-76.