

## Image in cardiology

## Transcatheter Aortic Valve, Impella and Complex Coronary Intervention



## Válvula aórtica transcatéter, Impella e intervención coronaria compleja

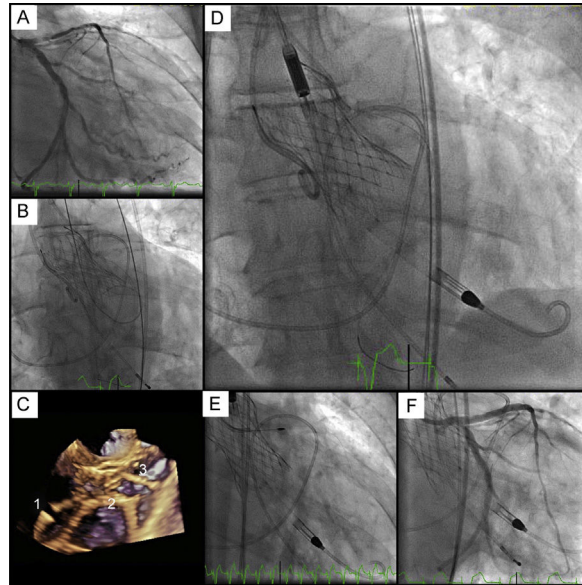
Isaac Pascual,<sup>a,b</sup> Pablo Avanzas,<sup>a,b,\*</sup> and César Morís<sup>a,b</sup><sup>a</sup>Área del Corazón, Hospital Universitario Central de Asturias, Oviedo, Asturias, Spain<sup>b</sup>Instituto de Investigación Sanitaria del Principado de Asturias, Oviedo, Asturias, Spain

Figure.

A 70-year-old man was admitted for non-ST-segment acute coronary syndrome with extensive anterolateral ischemia, severely depressed ventricular function (20%), and critical aortic stenosis (AS). Coronary angiography revealed a critical and severely calcified lesion in the left anterior descending (LAD) artery (Figure A). The urgent multidisciplinary team decided to perform percutaneous coronary intervention (PCI) with circulatory support with an Impella CP device. Because the patient had associated critical AS, transcatheter aortic valve implantation (TAVI) was performed prior to PCI.

A 29-mm Evolut R device was implanted through the right femoral vein, with good results (Figure B). Before implantation, the left coronary artery was protected with an angioplasty guide to facilitate subsequent access. Under 3-dimensional echocardiographic guidance and fluoroscopy, the same access route was used to insert the Impella CP device through the valve leaflets (Figure C: 1, left ventricle; 2, prosthesis; 3, aorta) (Figure D). Finally, through the mesh of the prosthetic valve, the intervention was performed on the AD using rotational atherectomy and the implantation of 2 overlapping everolimus-eluting stents, with good results (supplementary material video; Figure E and F). The Impella CP device was removed after the procedure, without complications, and percutaneous vascular access suture was performed. The patient's progress was good, with an ejection fraction of 45% at discharge.

We present the images of an exceptional case, the first in Spain, in which TAVI was used to implant a percutaneous hemodynamic support device prior to high-risk angioplasty. Because the patient was at high surgical risk due to his unstable condition, we chose percutaneous treatment.

## SUPPLEMENTARY MATERIAL



Supplementary material associated with this article can be found in the online version available at <http://dx.doi.org/10.1016/j.rec.2017.09.012>

\* Corresponding author:  
E-mail address: [avanzas@secardiologia.es](mailto:avanzas@secardiologia.es) (P. Avanzas).  
Available online 19 October 2017